Motor impairment and Chiari II malformation in children with spina bifida

Neurophysiological and brain MR imaging studies

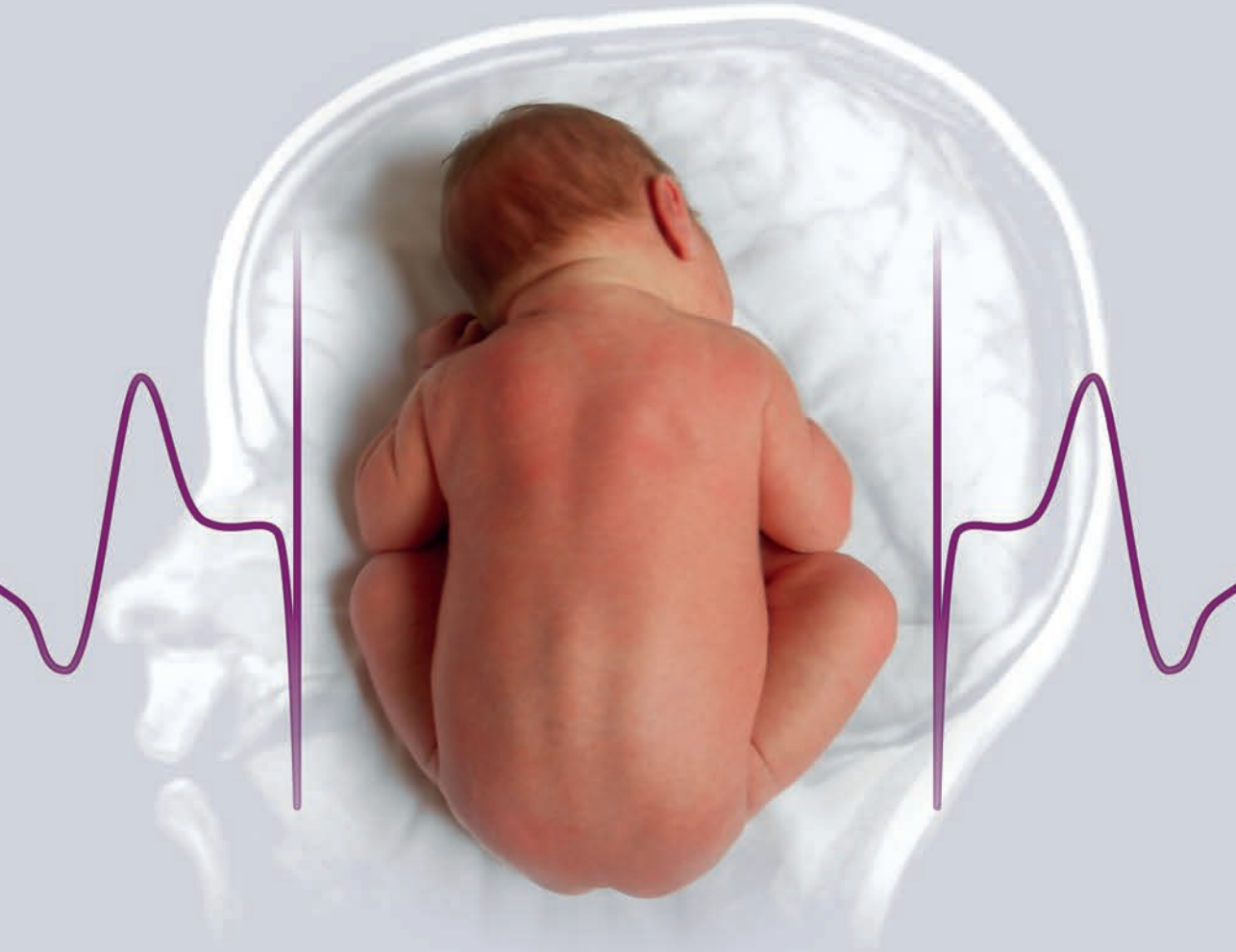

Niels Geerdink

Colofon

Motor impairment and Chiari II malformation in children with spina bifida.
Neurophysiological and brain MR imaging studies
Thesis Radboud University Nijmegen Medical Center with summary in Dutch

This PhD project was funded by a Research Grant from the Radboud University Nijmegen to the Nijmegen Interdisciplinary Spina Bifida Program and by additional Research Grants form the Johanna Kinderfonds and the Kinderrevalidatie Fonds Adriaanstichting.
Printing of this thesis was financially supported by the Radboud University Nijmegen Medical Center.

ISBN 978-90-9027188-0

Cover design and layout by In Zicht Grafisch Ontwerp, Arnhem
Printed and bound by Ipskamp Drukkers, Enschede

Motor impairment and Chiari II malformation in children with spina bifida

Neurophysiological and brain MR imaging studies

Proefschrift

ter verkrijging van de graad van doctor
aan de Radboud Universiteit Nijmegen
op gezag van de rector magnificus prof. mr. S.C.J.J. Kortmann,
volgens besluit van het college van decanen
in het openbaar te verdedigen
op donderdag 20 december 2012
om 10.30 uur precies

door

Niels Geerdink
geboren op 6 april 1976
te Eibergen

Promotor
Prof. dr. J.J. Rotteveel

Copromotoren
Dr. R.A. Mullaart
Dr. J.W. Pasman
Dr. ir. N. Roeleveld

Manuscriptcommissie
Prof. dr. A.C.H. Geurts, voorzitter
Prof. dr. ir. D.F. Stegeman
Prof. dr. O.F. Brouwer (Universitair Medisch Centrum Groningen)

Paranimfen
Dr. A. Vinck
Dr. B.V. Tjemkes

Table of contents

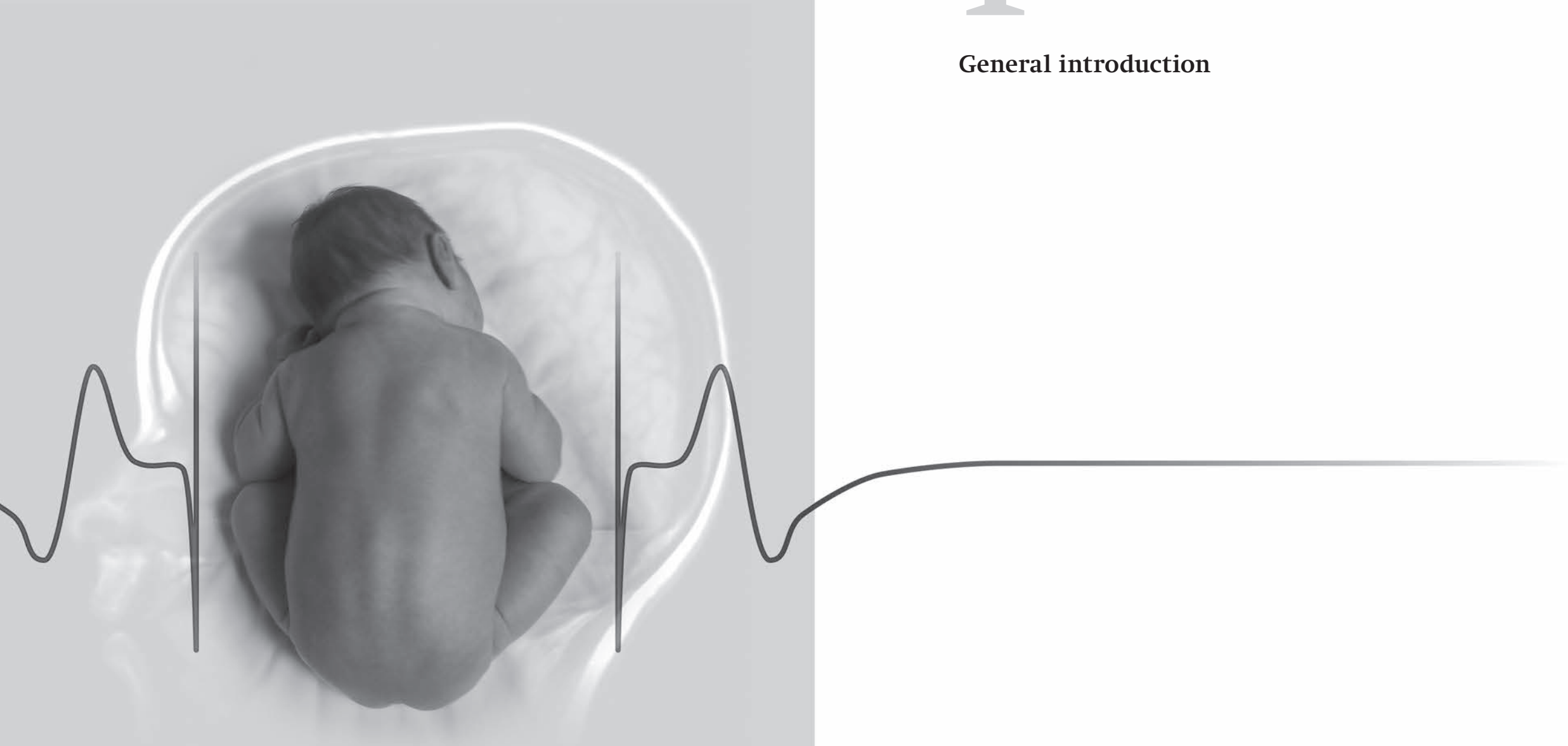

1

General introduction

Spina bifida is a complex congenital malformation of the nervous system with abnormalities at several levels along the neural axis. Spina bifida is heterogeneous in presentation and outcome and may result in life-long impairments with a pervasive impact on daily activities and community participation for affected individuals. As a result of improved medical care, such as neurosurgical interventions and improved urological care, the mortality rate has substantially declined over the past decades and spina bifida is now compatible with long-term survival. As such, it is a challenging disorder for every clinician working with children and adults with spina bifida.

Characterization

Spina bifida is primarily characterized by incomplete closure of the neural tube during early embryonic development resulting in abnormal spinal cord, meningeal, and mesenchymal tissue, mostly in the lumbosacral region. Broadly speaking, spina bifida can be categorized into *open spinal dysraphism* and *closed spinal dysraphism* [1]. In case of open spinal dysraphism, the abnormal neural tissue protrudes through open vertebral arches and a midline muscle-skin defect resulting in a membranous cystic swelling, called cele. Consequently, the abnormal neural tissue is exposed to the environment without skin covering. In most cases of closed spinal dysraphism, the abnormal neural tissue protrudes through open vertebral arches and a muscle defect as well, but this tissue is covered by normal skin, often in combination with a subcutaneous lipomatous mass. Together with anencephaly and encephalocele, spina bifida encompasses the broad spectrum of neural tube defects.

Prevalence

Worldwide, the prevalence estimates of neural tube defects range from 1.0 to 10.0 per 1,000 births with approximately equal frequencies for spina bifida and anencephaly [2]. The birth prevalence of spina bifida has decreased in the last decades due to folic acid fortification programs and an increased frequency of pregnancy terminations due to prenatal diagnosis by ultrasound screening. However, the prevalence seems to stabilize in the last few years [3,4]. The prevalence of spina bifida not only varies over time, but also by region, race, and ethnicity [5], which explains the worldwide range in prevalence estimates. In the Netherlands, the prevalence of spina bifida was 0.51 per 1,000 in the period from 2006 to 2010, with a live birth prevalence of 0.24 per 1,000 [6].

Pathogenesis and etiology

Although the pathogenesis of spina bifida is not completely understood, the 'two-hit' hypothesis as proposed by Heffez et al. [7] is widely supported regarding open spinal dysraphism. In normal spinal cord development, the neural plate is formed by differentiation of ectodermal cells. Folding of the neural plate results in a neural groove and subsequently, the neural folds fuse in the midline to from the primary neural tube. This process occurs during weeks 3 and 4 of embryonic development and is called primary neurulation. Open spinal dysraphism results from failures in this process [8]. Data from animal models suggest that disturbances in cell adhesion or alterations in neural plate folding prevent apposition of the neural folds [9]. The second hit is damage to and neurodegeneration of exposed aberrant neural tissue in utero. In addition to toxicity of amniotic fluid causing chemical injury [10], mechanical shearing and abrasive stresses on the surface of the neural tissue cause damage to this delicate tissue [11].

Regarding closed spinal dysraphism, the pathogenesis is less well understood. Most forms of closed spinal dysraphism are also thought to originate from defective primary neurulation involving focal premature disjunction of the cutaneous ectoderm from the neuroectoderm (neural plate). As a consequence, mesenchymal tissue can freely enter the interior of the neural tube and make contact with the ependymal lining. The ependyma induces the mesenchymal tissue to develop into aberrant lipomatous tissue [12].

The etiology of spina bifida is multifactorial with involvement of both environmental and genetic determinants. A large number of potential risk factors have been implicated, but most of the reported associations are weak or have not been replicated in subsequent studies. Therefore, only a few well-known risk factors have been established for spina bifida, including a previous affected pregnancy, inadequate maternal intake of folic acid, pre-existing maternal diabetes, and valproic acid or carbamazepine use. In addition, a number of strongly suspected risk factors are reported, including poor maternal vitamin B12 status, maternal obesity, maternal hyperthermia, and maternal diarrhea [13]. Genetic factors have been subject of extensive research as well. Although most neural tube defects are isolated, a genetic influence is suggested as neural tube defects have a higher concordance rate in monozygotic twins compared to dizygotic twins and are more common among siblings and in females [14]. Moreover, neural tube defects occur as part of syndromes, chromosomal anomalies, and a few single gene disorders [2]. Over a hundred candidate genes have been examined for associations with isolated spina bifida. The candidate genes studied include those important in folic acid metabolism, glucose metabolism, retinoid

metabolism, and apoptosis. In addition, many genes that are involved in early embryonic development are tested. Less than 20 % of the candidate genes studied have been determined as having even a minor effect on spina bifida risk [2].

Malformations at multiple levels along the neural axis

The pathology of spina bifida, in particular open spinal dysraphism, includes malformations at multiple levels along the neural axis (Figure 1). This paragraph describes these malformations in a caudo-cranial direction.

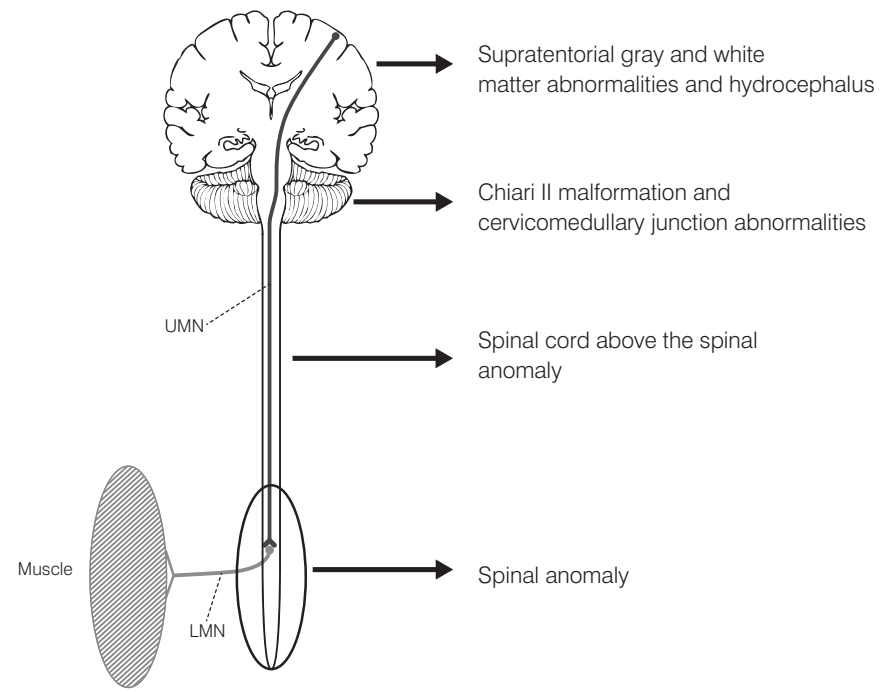

Figure 1 Malformations at multiple levels along the neural axis. UMN, upper motor neuron; LMN, lower motor neuron.

The most distinct malformation is the *spinal anomaly*, which results from incomplete closure of the neural tube (see paragraph pathogenesis and etiology). Based on the clinical appearance of the spinal anomaly, spina bifida is initially categorized

into *open spinal dysraphism* and *closed spinal dysraphism* [1]. In open spinal dysraphism, the abnormal non-neurulated spinal cord, called neuroplacode, and the meninges are exposed to the environment through open vertebral arches and a midline muscle-skin defect [15]. Because the mesenchymal tissue does not migrate posterior to the neuroplacode, bones, cartilage, and muscles develop anterolaterally to the neuroplacode. Nerve roots originate from the ventral surface of the neuroplacode and course through the subarachnoidal space to reach their corresponding neuroforamina and innervate limb muscles [16]. Open spinal dysraphism can be further classified into myelomeningocele, myelocele, and the unilateral variants of these entities, hemimyelomeningocele and hemimyelocele. In myelomeningocele, the neuroplacode and aberrant meninges protrude above the cutaneous surface due to expansion of the underlying subarachnoidal spaces, whereas in myelocele, the neuroplacode and aberrant meninges are flush with the cutaneous surface [1]. Myelomeningoceles account for the majority of open spinal dysraphism. In closed spinal dysraphism, the spinal anomaly with the aberrant neural tissue is completely covered with skin, although cutaneous marks are present in up to 50% of the patients [17]. Closed spinal dysraphism can be further categorized based on the presence or absence of a subcutaneous mass. Spinal anomalies with a subcutaneous mass are lipomyelocele, lipomyelomeningocele, meningocele, and terminal myelocystocele. Spinal anomalies without a subcutaneous mass encompass a more heterogeneous group, including intradural lipoma, tight filum terminale, dermal sinus, diastematomyelia, and caudal agenesis [16].

Within the subtypes mentioned, phenotypic heterogeneity is substantial and spinal anomalies vary in size and position along the spine. In general, open spinal dysraphism is associated with other substantial malformations along the neural axis (see below), whereas none or just minor other malformations may be associated with closed spinal dysraphism [18,19]. In open spinal dysraphism, the spinal anomaly is usually located more cranial than in closed spinal dysraphism.

The *spinal cord in the fused spinal segments above the spinal anomaly* may be abnormal as well. This may be due to syringomyelia, a fluid filled cavity central in the spinal cord, or due to stretching of the spinal cord resulting from traction on the spinal cord in case of a so-called tethered spinal cord.

Chiari II malformation is almost uniquely associated with open spinal dysraphism [20]. It is a complex and heterogeneous malformation that is characterized by a small posterior fossa, downward herniation of the cerebellum and brainstem through an enlarged foramen magnum, and upward herniation of the cerebellum through an enlarged tentorial incisura [21]. In addition to these characteristics, other specific features are frequently present and include tectal beaking, medullary kinking, small fourth ventricle, and hypoplastic tentorium [22]. Regarding the pathogenesis, McLone and Knepper [23] hypothesized that leakage

of cerebrospinal fluid through the spinal anomaly reduces the distension of the embryonic ventricular system. Subsequently, decreased inductive pressure on the surrounding mesenchymal tissue results in an abnormally small posterior fossa. Approximately one third of the patients with spina bifida develop signs or symptoms of Chiari II malformation [22]. These may result from intrinsic developmental hindbrain abnormalities or from secondary damage due to hindbrain compression. A clear association between the morphological appearance of the malformation and the presence of signs and symptoms does not exist [24].

Hydrocephalus is present in 80-85% of infants with open spinal dysraphism, requiring shunting in almost all infants with thoracic spinal anomalies and in less than 70% of infants with sacral spinal anomalies [25]. The pathogenesis is not completely elucidated yet, but it is hypothesized that hydrocephalus is caused by a compromised cerebrospinal fluid flow due to crowding in the posterior fossa or an obstruction in a malformed aqueduct [26]. Hydrocephalus may be associated with specific functional and neuropsychological abnormalities, many of which can be attributed to dysfunction of particular brain regions [27,28].

A certain degree of *corpus callosum dysmorphology* is present in virtually all children with open spinal dysraphism. Although the morphology is highly variable, the genu is relatively preserved with hypoplastic features occurring in the corpus and agenesis being most prominent in the isthmus and splenium [29]. This dysmorphology is related to deficits in cognitive tasks [30].

Other *supratentorial malformations* include, but are not limited to, large massa intermedia, abnormal interhemispheric commissures, heterotopias, and stenogyria [21,31].

Outcome and prognosis

Over the past decades, childhood survival of children with spina bifida has increased to 85% [32,33] and the overall outcome has improved, both as a result of progress in medical care and surgical management [13,3]. Moreover, in the era of prenatal screening, elective termination of pregnancy following a prenatal diagnosis of spina bifida did not only result in a decreased birth prevalence, but also in improvement of the overall outcome, as the most severely affected fetuses are less likely to come to term [34]. Despite improvements in outcome, the consequences with respect to daily activities and community participation are life-long [32,35-39].

The direct consequences of the spinal anomaly are generally most pronounced. They include motor impairment in the lower limbs leading to restricted mobility; sensory loss leading to gait instability and pressure sores; bladder and bowel

dysfunction leading to incontinence, constipation, urinary tract infections, and sometimes renal damage; and sexual dysfunction leading to impotence, decreased sensation, and complicated reproduction. In addition, orthopedic problems such as scoliosis, kyphosis, and joint contractures are frequently seen. During childhood, restricted ambulation and bowel dysfunction are the most prominent problems. In adolescence and adulthood, incontinence, constipation, foot deformities, and scoliosis become the most frequently reported health problems [36,40]. Incontinence and sexual dysfunction have repercussions for relationships and sexuality in later life as well [40].

As already stated, signs and symptoms of Chiari II malformation are present in approximately one third of the patients. Children younger than 2 years of age present most frequently with cranial nerve and brainstem signs, such as an inspiratory stridor due to vocal cord abduction paresis, apnoeic episodes, swallowing difficulties with chronic aspiration, and nystagmus. In older children, sign and symptoms of cervical myelopathy are the hallmark with upper limb weakness and spasticity being the most common findings. Ataxia and occipital headaches are common as well [22]. The mortality among symptomatic children is 15 to 35 % [41,42] and applies virtually exclusively to children under the age of 2 years [43]. Consequently, Chiari II malformation is the most frequent cause of death among infants with spina bifida.

Cognitive impairment is considered to be relatively mild, as most patients tend to have intelligence skills within the low-average to average range with verbal skills generally being more advanced than nonverbal problem-solving skills [44,45]. Specific cognitive impairments associated with spina bifida are deficits in visual perception, motor skills, and memory [46-48]. These cognitive deficits can adversely affect educational and occupational achievements and the ability to live independently.

Several studies concerning survival and outcome of patients with spina bifida are available in the literature. Illustrative is the longest follow-up study from the UK described by Oakeshott and Hunt [35,49]. Of the 117 patients followed for 40 years, 40 patients died before the age of 5 years and 31 during the next 35 years. Of the 46 survivors, 30% could walk at least 50 meters, 80% had an IQ of 80 or more, 83% had a shunted hydrocephalus, and 20% were continent of urine and feces. Thirty-three percent worked in open employment and 46% drove a car, while 35% needed daily care. Another follow-up study described the 25 years outcome of a cohort of 118 individuals with spina bifida in the USA [32]. Twenty-eight (24%) children had died at time of follow-up, the majority (18/28) during infancy or in their preschool years and most of them (13/18) due to symptomatic Chiari II malformation. Of the 71 individuals available for follow-up, 46% were ambulant, 36% and 49% had attended high school or college,

respectively, 86% had a shunted hydrocephalus, and 15% and 52% were continent of urine or feces, respectively. Forty-five percent of the young adults were employed and 15% lived independently. Illustrative for the Dutch situation are the results from the ASPINE study (Adolescents with spina bifida in the Netherlands study), a multicenter study in which the outcome of 179 young adults with spina bifida was evaluated. In many impairment domains, subjects with spina bifida and hydrocephalus encountered more problems than those with spina bifida without hydrocephalus or those with closed spinal dysraphism. Subjects with high level spinal anomalies encountered more problems than subjects with low level spinal anomalies [36]. Of the 119 young adults with spina bifida and hydrocephalus in the ASPINE study, 44% were ambulant, 80% had an IQ above 70, 71 % were incontinent of urine, and 46% were incontinent of feces. Twenty percent had a partner, 31% had regular employment, and 5% lived independently [36,38,39,50].

A number of studies on the quality of life of children with spina bifida have been also reported in the literature. However, it is difficult to arrive at a synthesis of this literature, as several different instruments were used and the results are equivocal. Some authors found that the health-related quality of life was below normal [51], whereas others concluded that quality of life was good or comparable to people without spina bifida [52]. In the ASPINE study, the overall satisfaction with life of young adults with spina bifida appeared more or less the same as that of their healthy peers and the severity of spina bifida appeared to have only a minor impact on life satisfaction [53].

Although the overall outcome of children with spina bifida has improved over the past decades, determining the individual long-term prognosis for an affected infant born nowadays is still difficult [54,55]. Some rough neonatal outcome predictors have been established. The extent of the sensory deficit is related to the outcome and has a predictive value for ambulation, need of daily care, and community participation in adulthood [56,35]. A higher anatomical level of the spinal anomaly is associated with more severe brain malformations, which in turn are associated with poorer neurobehavioral outcome [57]. However, the anatomical level is only partly related to the level of neurological impairment, as the latter level is generally located more cranially than the anatomical level [25]. Furthermore, the presence of hydrocephalus is associated with poorer outcome [36] with the annotation that cognitive impairments in particular are related to the number of shunt-related complications [58-60]. Using prenatal ultrasound imaging, the anatomical level of the spinal anomaly and head circumference are predictive for survival, but no obvious prenatal ultrasound predictors for mental and motor outcome have been identified so far [61,62].

Treatment

Over the past decades, medical care and surgical management of individuals with spina bifida have greatly improved. The main advances were the treatment of hydrocephalus using cerebrospinal fluid shunts in the late 1950s and improved urological management with the introduction of clean intermittent catheterization in the 1970s. Currently, the treatment is multidisciplinary. Neurosurgical management is aimed at maintaining stable neurological functioning throughout life [63]. Initially, surgical closure of the spinal anomaly is performed within the first days after birth. Shortly after, most infants need cerebrospinal fluid shunt insertion for hydrocephalus and most of these infants become shunt-dependent for life. Shunt-related complications, such as infections and dysfunctions, occur at all ages and require immediate treatment. Further treatment may include posterior fossa decompression to relief symptomatic Chiari II malformation, untethering of a tethered spinal cord, orthopedic interventions for scoliosis and joint contractures, and bladder and bowel management. Based on the individual needs, support from pediatricians, rehabilitation medicine, physical and occupational therapists, social workers, wounds specialists, and psychologists are important as well [64].

With the advances in the management of spina bifida, a discussion about selective treatment arose in the 1970s. John Lorder, a British pediatrician, promoted selection criteria for treatment and suggested withholding active treatment from newborns with gross macrocephaly, myelomeningocele above spinal level L3, severe kyphoscoliosis, or additional congenital defects. He argued that many of these children were a burden to themselves, their family, and society [65,66]. None of these criteria, either in isolation or in combination, however, is an entirely accurate predictor of outcome [64]. The policy of Lorber was, among others, opposed by David McLone, who advocated aggressive, coordinated, multidisciplinary care for all newborns with spina bifida. One of the reasons for McLone's policy was that there is little difference in outcome between children surviving selective treatment and children surviving non-selective treatment [67]. Nowadays, non-selective treatment is standard care in North America [60,63], whereas selective treatment is not uncommon in Europe. As such, the discussion on selective treatment still continues [54,68]. In the Netherlands, a set of guidelines to clarify and facilitate the assessment of clinically stable newborn infants, who are considered to be suffering unbearably and for whom the prognosis is felt to be hopeless ('The Groningen Protocol'), was proposed in 2001 and published in 2005 [69]. Verhagen et al. [70] reported twenty-two newborn infants with myelomeningocele that met the criteria for ending life by lethal injection according to the 'The Groningen Protocol'. The protocol received significant condemnation as well as support in the literature. In addition to different expert opinions, the improved overall outcome over the last decades and the lack of evidence-based outcome predictors for an individual infant with spina bifida add to the discussion on selective treatment [54,60,63]. Personal opinions and perhaps emotional arguments may prevail over medical arguments in decision-making processes regarding the treatment of newborn infants with spina bifida.

Quite in contrast to selective treatment, prenatal surgery has become an optimistic new treatment option. From animal studies, evidence exists that secondary damage to neural tissue according to the 'two hit' theory may be prevented by covering the spinal anomaly at an early gestational age and that consequently, neurological function is preserved [71,72]. In humans, the first successful prenatal surgical interventions for spina bifida were reported in the late 1990s [73,74]. Recently, the initial favorable results were confirmed in a randomized trail (Management of Myelomeningocele Study – MOMS trail) showing improvement of motor impairment and reduction of hindbrain herniation and hydrocephalus shunting at the age of two years after prenatal surgery compared to postnatal surgery [75]. However, criticism regarding prenatal surgery exists as well, because long-term outcome is still not available and prenatal surgery is associated with increased risks of maternal and fetal complications [76,77]. Currently, prenatal surgery is not yet performed in the Netherlands.

Motivation for this thesis

In line with the current considerations on spina bifida mentioned in the paragraphs above, the motivation for the studies described in this thesis is founded on intrinsic characteristics of spina bifida and extrinsic topics regarding outcome and treatment. The intrinsic characteristics concern the pathology at multiple levels along the neural axis and the morphological and functional heterogeneity of spina bifida. Considering the reported improvements in motor impairment and hindbrain herniation after prenatal surgery, the pathophysiology of lower limb motor impairment in relation to the multilevel pathology and the morphological heterogeneity of Chiari II malformation are of particular interest. This is further explained below.

Considering the complex multilevel pathology, motor impairment in the lower limbs may result from lower motor neuron (LMN) and upper motor neuron (UMN) dysfunction (Figure 1). LMN dysfunction directly results from segmental disorders in the spinal anomaly. UMN dysfunction, however, may result from abnormalities in the corticospinal tract either in or above the spinal anomaly.

Important abnormalities above the spinal anomaly are Chiari II malformation and supratentorial malformations, whether or not related to hydrocephalus. Clinical signs of LMN dysfunction are generally most prominent, but knowledge about the proportional contribution of LMN and UMN dysfunction to motor impairment and the specific localization of UMN dysfunction is limited. Furthermore, it is of interest whether the improvement in motor impairment after prenatal surgery is related to improved LMN or improved UMN function.

Usually, Chiari II malformation is clinically diagnosed with the help of MR imaging, but the morphological appearance of the Chiari II malformation on MR images is quite heterogeneous. Therefore, the interpretation of its features as seen on MR images may not always be straightforward. The heterogeneity and an abundance of features that could be taken into account may obscure unambiguous assessment of Chiari II malformation. Definitions of features may be equivocal and reviewers may interpret features differently. This may be explained by the qualitative nature of these features and the fact that the distinction between normal and abnormal brain development is not defined by unambiguous cutoff points. Although most features are typical for Chiari II malformation, knowledge about the reliability of rating these features on MR images is lacking. These difficulties may hamper the assessment of Chiari II malformation not only in clinical settings, but also in research settings concerning the outcome of hindbrain herniation after prenatal surgery.

The extrinsic topics that motivated this thesis are the improved overall outcome of children with spina bifida and the decisions that have to be taken regarding prenatal and postnatal treatment opportunities. These decision-making processes are complicated by the lack of up-to-date knowledge about the outcome of children with spina bifida and the fact that the outcome of an individual newborn infant with spina bifida is hardly predictable. Therefore, it is important to have instruments that could provide objective information about the morphological abnormalities and the severity of the neurological deficits to guide decision-making processes.

Neurophysiological studies, such as transcranial and spinal magnetic stimulation and nerve conduction studies may provide new insights into the pathophysiology of LMN and UMN dysfunction in spina bifida. Furthermore, the MR assessment of Chiari II malformation could be upgraded by a critical morphological and morphometric appraisal of the malformation on MR images. These neurophysiological and imaging instruments could contribute to decision-making processes regarding the treatment of spina bifida, as they may provide objective outcome measures or predictive tools.

Neurophysiological methods

Transcranial magnetic stimulation (TMS) of the cerebral cortex and magnetic stimulation of spinal roots are non-invasive neurophysiological methods to investigate LMN and UMN function in adults and children [78,79]. Based on the principle of electromagnetic induction, TMS induces an electric current in the underlying brain by a powerful fluctuating extracranial magnetic field. This electric current results in activation of cortical motor neurons, either directly by excitation at the axon hillock (direct excitation) or indirectly (transsynaptically) by activation of cortical interneurons projecting onto corticospinal motor neurons (indirect excitation). Fast-conducting corticospinal neurons have a lower threshold for direct excitation, whereas slow-conducting corticospinal neurons have a lower threshold for indirect excitation [80]. Following excitation, corticospinal motor neurons discharge and volleys are mediated via the corticospinal tract that has monosynaptic connections with spinal alpha motor neurons, which subsequently innervate voluntary muscles. Following TMS, motor evoked potentials (MEPs) can be recorded from limb muscles by surface electromyography. These MEPs provide information about cortical motor function and the integrity of the corticospinal tract (UMN function) [81]. This method is illustrated in Figure 2.

Based on the same principle of electromagnetic induction, spinal magnetic stimulation activates the motor nerve roots at the point where they leave the intervertebral foramina. At this point, the magnetic field focuses and the stimulus threshold is low [82-84]. As the configuration of the spinal column insulates the spinal cord, it is impossible to stimulate the spinal cord directly [82]. Following spinal magnetic stimulation, MEPs can be recorded from limb muscles by surface electromyography. These MEPs provide information about LMN function [81].

In addition, conventional nerve conduction studies are convenient tools to investigate LMN function. Following percutaneous supramaximal electrical stimulation of a peripheral nerve, compound muscle action potentials (CMAPs) can be recorded from the target muscle by surface electromyography. The CMAP is a reflection of activated motor units in the muscle recorded [85].

Several parameters can be used to study MEPs and CMAPs (Figure 3). The latency measures the conduction time from the stimulus to the onset of the response. The amplitude of the response and the area under the response curve provide estimates of the number of activated motor units. However, the area provides a better estimate than the amplitude, as the area is less liable to dispersion of motor volleys [86,87]. Therefore, we used the area instead of the amplitude. The central motor conduction time (CMCT) is calculated from the

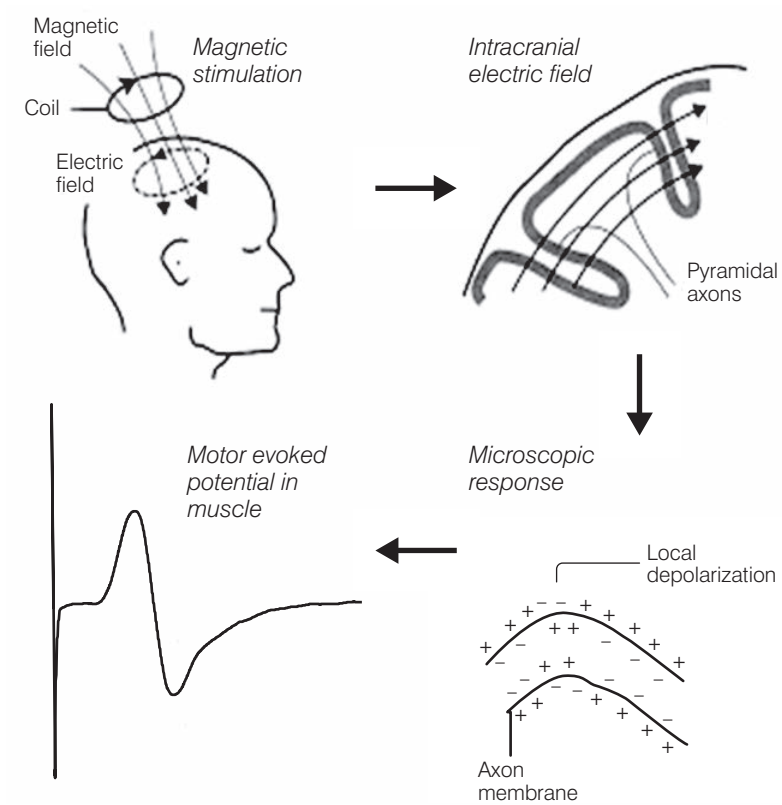

Figure 2 Principle of magnetic stimulation.

difference between the latencies of the transcranial and spinal MEPs in the same target muscle [88]. The CMCT includes the times for excitation of cortical motor neurons, conduction via the corticospinal tract, and excitation of spinal motor neurons sufficient to exceed their firing threshold [78].

When performing TMS, facilitation of MEPs is achieved during voluntary contraction of the target muscle, which results in a reduced threshold for excitation, a shorter MEP latency, and an increased MEP amplitude and area [89]. Although the physiology of facilitation is not entirely understood, both changes in spinal and cortical excitability seem to be involved [90].

So far, magnetic stimulation has proven to be of diagnostic value in several neurological disorders in adults and children [78,79]. TMS is particularly useful to investigate cortical motor function and the integrity of the corticospinal tract.

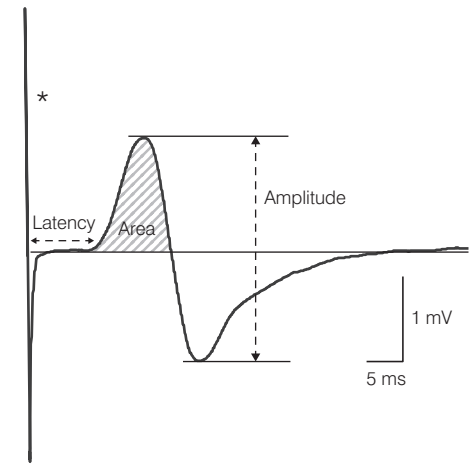

Figure 3 Parameters of MEP and CMAP. Asterisk indicates stimulus artifact.

It may be helpful by confirming the presence of corticospinal tract involvement in neurological disorders and provides insight into disease mechanisms [80]. It is a safe and noninvasive method that is easily used and well tolerated [91,92].

Background, aim, and outline of the thesis

This thesis is the third PhD thesis achieved within the Nijmegen Interdisciplinary Spina Bifida program. In this program, several disciplines participate: pediatric neurology, neuropsychology, clinical neurophysiology, neuroradiology, obstetrics, epidemiology, family psychology, and empirical theology. The main purpose of the program is to determine the neurological, neuropsychological, and family-related outcomes of children with spina bifida aiming to improve the prognostication and to support decision-making processes regarding prenatal and postnatal treatment. Data collection started in January 2002. A cohort of 44 newborn infants with spina bifida was prospectively included and followed into early childhood. In addition, a cohort of 56 school-age children with spina bifida was recruited from the outpatient multidisciplinary spina bifida clinics. Regarding the pediatric neurological part of the program, data collection included prenatal ultrasound imaging, physical and neurological examination, cranial ultrasound imaging, muscle ultrasound imaging, MR imaging of the brain and spinal cord, and neurophysiological investigations as mentioned before.

The specific aim of this thesis is twofold. First, we aim to disentangle the proportional contribution of LMN and UMN dysfunction to motor impairment in the lower limbs using conventional nerve conduction studies and transcranial and spinal magnetic stimulation. In addition, we aim to provide objective measures for the degree of motor impairment through investigation of the diagnostic and prognostic values of these neurophysiological instruments. Second, we aim to improve the MR assessment of Chiari II malformation by critically appraising its morphological features and performing morphometric analyses, in order to select those features and measures that are particularly useful for the diagnosis, severity assessment, and outcome evaluation of Chiari II malformation.

In summary, this thesis addresses the following research questions:

1. *At which levels along the neural axis is the pathology located that determines motor impairment in the lower limbs in children with spina bifida?*
2. *Can neurophysiological tools provide objective information about motor impairment in children with spina bifida and what is the diagnostic and prognostic value of these tools?*
3. *Which features and measures are essential in the MR assessment of Chiari II malformation?*
4. *Can neurophysiological and imaging tools provide objective standards to evaluate the outcome of prenatal and postnatal treatment?*

The results are described in two parts. *Part one* contains the neurophysiological studies. *Chapter 2* describes a pilot study, in which the applicability of transcranial and lumbosacral magnetic stimulation was investigated in the newborn infants with spina bifida. In *Chapter 3 and 4* associations between CMAPs and MEPs and neurological impairment in newborn infants with spina bifida are described. Subsequently, we investigated the predictive value of these neonatal MEPs and CMAPs for neurological outcome at the age of two years, which is described in *Chapter 5*. Finally, neurophysiological studies performed in the cohort of school-age children with spina bifida are described in *Chapter 6*. In order to disentangle the proportional contribution of LMN and UMN dysfunction to motor impairment, neurophysiological measurements in mildly and severely impaired children with spina bifida are compared to measurements in children without spina bifida.

Part two contains the brain MR imaging studies. *Chapter 7* describes a qualitative study, in which the morphological features of Chiari II malformation are studied by assessing their interobserver reliability. Among the abundance of features, those features that are essential for the MR assessment of the malformation are selected. Subsequently, a quantitative study is presented in *Chapter 8*. In this study, the interobserver reliability and diagnostic value of morphometric measures are investigated, in an attempt to select measures that may be suitable to address the severity of Chiari II malformation.

Finally, the main findings and methodological considerations are discussed in *Chapter 9*, where the final concluding remarks and future perspectives are presented as well.

References

1. Tortori-Donati P, Rossi A, Cama A. Spinal dysraphism: a review of neuroradiological features with embryological correlations and proposal for a new classification. *Neuroradiology* 2000; 42:471-491.
2. Au KS, Ashley-Koch A, Northrup H. Epidemiologic and genetic aspects of spina bifida and other neural tube defects. *Dev Disabil Res Rev* 2010; 16:6-15.
3. Fletcher JM, Brei TJ. Introduction: Spina bifida - a multidisciplinary perspective. *Dev Disabil Res Rev* 2010; 16:1-5.
4. Frey L, Hauser WA. Epidemiology of neural tube defects. *Epilepsia* 2003; 44(Suppl.3):4-13.
5. Mitchell LE. Epidemiology of neural tube defects. *Am J Med Genet C Semin Med Genet* 2005; 135:88-94.
6. EUROCAT Website Database. EUROCAT prevalence data tables. [EUROCAT website]. April 3, 2012. Available at: http://www.eurocat-network.eu/ACCESSPREVALENCEDATA/PrevalenceTables. Accessed May 27, 2012.
7. Heffez DS, Aryanpur J, Hutchins GM, Freeman JM. The paralysis associated with myelomeningocele: clinical and experimental data implicating a preventable spinal cord injury. *Neurosurgery* 1990; 26:987-992.
8. Sadler TW. Mechanisms of neural tube closure and defects. *MRDD research reviews* 1998; 4:247-253.
9. Copp AJ, Greene ND. Genetics and development of neural tube defects. *J Pathol* 2010; 220:217-230.
10. Drewek MJ, Bruner JP, Whetsell WO, Tulipan N. Quantitative analysis of the toxicity of human amniotic fluid to cultured rat spinal cord. *Pediatr Neurosurg* 1997; 27:190-193.
11. Stiefel D, Copp AJ, Meuli M. Fetal spina bifida in a mouse model: loss of neural function in utero. *J Neurosurg* 2007; 106:213-221.
12. Naidich TP, McLone DG, Mutluer S. A new understanding of dorsal dysraphism with lipoma (lipomyeloschisis): radiologic evaluation and surgical correction. *AJR Am J Roentgenol* 1983; 140:1065-1078.
13. Mitchell LE, Adzick NS, Melchionne J, Pasquariello PS, Sutton LN, Whitehead AS. Spina bifida. *Lancet* 2004; 364:1885-1895.
14. Bowman RM, Boshnjaku V, McLone DG. The changing incidence of myelomeningocele and its impact on pediatric neurosurgery: a review from the Children's Memorial Hospital. *Childs Nerv Syst* 2009; 25:801-806.
15. Kumar A, Tubbs RS. Spina bifida: a diagnostic dilemma in paleopathology. *Clin Anat* 2011; 24:19-33.
16. Rossi A, Gandolfo C, Morana G, et al. Current classification and imaging of congenital spinal abnormalities. *Semin Roentgenol* 2006; 41:250-273.
17. Warder DE. Tethered cord syndrome and occult spinal dysraphism. *Neurosurg Focus* 2001; 10:E1.
18. Tubbs RS, Bui CJ, Rice WC, et al. Critical analysis of the Chiari malformation type I found in children with lipomyelomeningocele. *J Neurosurg* 2007; 106:196-200.
19. Milhorat TH, Bolognese PA, Nishikawa M, et al. Association of Chiari malformation type I and tethered cord syndrome: preliminary results of sectioning filum terminale. *Surg Neurol* 2009; 72:20-35.
20. Chiari H. Ueber Veränderungen des kleinhirns infolge von hydrocephalie des grosshirns. *Deut Med Wochenschr* 1891; 17:1172-1175.
21. Barkovich AJ. Congenital malformations of the brain and skull. In: Barkovich AJ. ed. *Pediatric neuroimaging*, 4th ed. Philadelphia: Lippincott Williams & Wilkins, 2005: 374-384.
22. Stevenson KL. Chiari type II malformation: past, present, and future. *Neurosurg Focus* 2004; 16:E5.
23. McLone DG, Knepper PA. The cause of Chiari II malformation: a unified theory. *Pediatr Neurosci* 1989; 15:1-12.
24. Vinchon M. Comment on Salman M: Posterior fossa decompression and the cerebellum in Chiari type II malformation: a preliminary MRI study. *Childs Nerv Syst* 2011; 27:463-464.
25. Rintoul NE, Sutton LN, Hubbard AM, et al. A new look at myelomeningoceles: functional level, vertebral level, shunting, and the implications for fetal intervention. *Pediatrics* 2002; 109:409-413.
26. Del Bigio MR. Neuropathology and structural changes in hydrocephalus. *Dev Disabil Res Rev* 2010; 16:16-22.
27. Dennis M, Landry SH, Barnes M, Fletcher JM. A model of neurocognitive function in spina bifida over the life span. *J Int Neuropsychol Soc* 2006; 12:285-296.
28. Hannay HJ, Walker A, Dennis M, Kramer L, Blaser S, Fletcher JM. Auditory interhemispheric transfer in relation to patterns of partial agenesis and hypoplasia of the corpus callosum in spina bifida meningomyelocele. *J Int Neuropsychol Soc* 2008; 14:771-781.
29. Kawamura T, Nishio S, Morioka T, Fukui K. Callosal anomalies in patients with spinal dysraphism: correlation of clinical and neuroimaging features with hemispheric abnormalities. *Neurol Res* 2002; 24:463-467.
30. Juranek J, Salman MS. Anomalous development of brain structure and function in spina bifida myelomeningocele. *Dev Disabil Res Rev* 2010; 16:23-30.
31. Miller E, Widjaja E, Blaser S, Dennis M, Raybaud C. The old and the new: supratentorial MR findings in Chiari II malformation. *Childs Nerv Syst* 2008; 24:563-575.
32. Bowman RM, McLone DG, Grant JA, Tomita T, Ito JA. Spina bifida outcome: a 25-year prospective. *Pediatr Neurosurg* 2001; 34:114-120.
33. Davis BE, Daley CM, Shurtleff DB, et al. Long-term survival of individuals with myelomeningocele. *Pediatr Neurosurg* 2005; 41:186-191.
34. Aguilera S, Soothill P, Denbow M, Pople I. Prognosis of spina bifida in the era of prenatal diagnosis and termination of pregnancy. *Fetal Diagn Ther* 2009; 26:68-74.
35. Oakeshott P, Hunt GM, Poulton A, Reid F. Open spina bifida: birth findings predict long-term outcome. *Arch Dis Child* 2012; 97:474-476.
36. Verhoef M, Barf HA, Post MW, van Asbeck FW, Gooskens RH, Prevo AJ. Secondary impairments in young adults with spina bifida. *Dev Med Child Neurol* 2004; 46:420-427.
37. Verhoef M, Barf HA, Post MW, van Asbeck FW, Gooskens RH, Prevo AJ. Functional independence among young adults with spina bifida, in relation to hydrocephalus and level of lesion. *Dev Med Child Neurol* 2006; 48:114-119.
38. Barf HA, Verhoef M, Post MW, et al. Educational career and predictors of type of education in young adults with spina bifida. *Int J Rehabil Res* 2004; 27:45-52.
39. Barf HA, Post MW, Verhoef M, Jennekens-Schinkel A, Gooskens RH, Prevo AJ. Restrictions in social participation of young adults with spina bifida. *Disabil Rehabil* 2009; 31:921-927.
40. Verhoef M, Barf HA, Vroege JA, et al. Sex education, relationships, and sexuality in young adults with spina bifida. *Arch Phys Med Rehabil* 2005; 86:979-987.
41. McLone DG. Continuing concepts in the management of spina bifida. *Pediatr Neurosurg* 1992; 18:254-256.
42. Oakeshott P, Hunt GM. Long-term outcome in open spina bifida. *Br J Gen Pract* 2003; 53:632-636.
43. Pollack IF, Pang D, Albright AL, Krieger D. Outcome following hindbrain decompression of symptomatic Chiari malformations in children previously treated with myelomeningocele closure and shunts. *J Neurosurg* 1992; 77:881-888.
44. Wills KE. Neuropsychological functioning in children with spina bifida and/or hydrocephalus. *J Clin Child Psychol* 1993; 22:247-265.
45. Brookshire BL, Fletcher JM, Bohan TP, Landry SH, Davidson KC, Francis DJ. Verbal and nonverbal skill discrepancies in children with hydrocephalus: a five-year longitudinal follow-up. *J Pediatr Psychol* 1995; 20:785-800.
46. Dennis M, Fletcher JM, Rogers T, Hetherington R, Francis DJ. Object-based and action-based visual perception in children with spina bifida and hydrocephalus. *J Int Neuropsychol Soc* 2002; 8:95-106.
47. Mataro M, Junque C, Poca MA, Sahuquillo J. Neuropsychological findings in congenital and acquired childhood hydrocephalus. *Neuropsychol Rev* 2001; 11:169-178.
48. Yeates KO, Enrile BG, Loss N, Blumenstein E, Delis DC. Verbal learning and memory in children with myelomeningocele. *J Pediatr Psychol* 1995; 20:801-815.
49. Oakeshott P, Hunt GM, Poulton A, Reid F. Expectation of life and unexpected death in open spina bifida: a 40-year complete, non-selective, longitudinal cohort study. *Dev Med Child Neurol* 2010; 52:749-753.

50. Barf HA, Verhoef M, Jennekens-Schinkel A, Post MW, Gooskens RH, Prevo AJ. Cognitive status of young adults with spina bifida. *Dev Med Child Neurol* 2003; 45:813-820.
51. Pit-ten Cate IM, Kennedy C, Stevenson J. Disability and quality of life in spina bifida and hydrocephalus. *Dev Med Child Neurol* 2002; 44:317-322.
52. Sawin KJ, Brei TJ, Buran CF, Fastenau PS. Factors associated with quality of life in adolescents with spina bifida. *J Holist Nurs* 2002; 20:279-304.
53. Barf HA, Post MW, Verhoef M, Jennekens-Schinkel A, Gooskens RH, Prevo AJ. Life satisfaction of young adults with spina bifida. *Dev Med Child Neurol* 2007; 49:458-463.
54. Barry S. Quality of life and myelomeningocele: an ethical and evidence-based analysis of the Groningen Protocol. *Pediatr Neurosurg* 2010; 46:409-414.
55. Shaer CM, Chescheir N, Schulkin J. Myelomeningocele: a review of the epidemiology, genetics, risk factors for conception, prenatal diagnosis, and prognosis for affected individuals. *Obstet Gynecol Surv* 2007; 62:471-479.
56. Hunt GM. Open spina bifida: outcome for a complete cohort treated unselectively and followed into adulthood. *Dev Med Child Neurol* 1990; 32:108-118.
57. Fletcher JM, Copeland K, Frederick JA, et al. Spinal lesion level in spina bifida: a source of neural and cognitive heterogeneity. *J Neurosurg* 2005; 102:268-279.
58. Hunt GM, Oakeshott P, Kerry S. Link between the CSF shunt and achievement in adults with spina bifida. *J Neurol Neurosurg Psychiatry* 1999; 67:591-595.
59. Heinsbergen I, Rotteveel J, Roeleveld N, Grotenhuis A. Outcome in shunted hydrocephalic children. *Eur J Paediatr Neurol* 2002; 6:99-107
60. Piatt JH. Treatment of myelomeningocele: a review of outcomes and continuing neurosurgical considerations among adults. *J Neurosurg Pediatr* 2010; 6:515-525.
61. Coniglio SJ, Anderson SM, Ferguson JE. Developmental outcomes of children with myelomeningocele: prenatal predictors. *Am J Obstet Gynecol* 1997; 177:319-326.
62. Van der Vossen S, Pistorius LR, Mulder EJ, et al. Role of prenatal ultrasound in predicting survival and mental and motor functioning in children with spina bifida. *Ultrasound Obstet Gynecol* 2009; 34:253-258.
63. Bowman RM, McLone DG. Neurosurgical management of spina bifida: research issues. *Dev Disabil Res Rev* 2010; 16:82-87.
64. Dias MS. Neurosurgical management of myelomeningocele (spina bifida). *Pediatr Rev* 2005; 26:50-60.
65. Lorber J. Results of treatment of myelomeningocele. An analysis of 524 unselected cases, with special reference to possible selection for treatment. *Dev Med Child Neurol* 1971; 13:279-303.
66. Lorber J. Selective treatment of myelomeningocele: to treat or not to treat? *Pediatrics* 1974; 53:307-308.
67. McLone DG. Treatment of myelomeningocele: arguments against selection. *Clin Neurosurg* 1986; 33:359-370.
68. Ottenhoff MJ, Dammers R, Kompanje EJ, Tibboel D, de Jong TH. Discomfort and pain in newborns with myelomeningocele: a prospective evaluation. *Pediatrics* 2012; 129:e741-e747.
69. Verhagen E, Sauer PJ. The Groningen protocol--euthanasia in severely ill newborns. *N Engl J Med* 2005; 352:959-962.
70. Verhagen AA, Sol JJ, Brouwer OF, Sauer PJ. Deliberate termination of life in newborns in The Netherlands; review of all 22 reported cases between 1997 and 2004. *Ned Tijdschr Geneeskd* 2005; 149:183-188.
71. Meuli M, Meuli-Simmen C, Yingling CD, et al. Creation of myelomeningocele in utero: a model of functional damage from spinal cord exposure in fetal sheep. *J Pediatr Surg* 1995; 30:1028-1032.
72. Danzer E, Johnson MP, Adzick NS. Fetal surgery for myelomeningocele: progress and perspectives. *Dev Med Child Neurol* 2012; 54:8-14.
73. Adzick NS, Sutton LN, Crombleholme TM, Flake AW. Successful fetal surgery for spina bifida. *Lancet* 1998; 352:1675-1676.
74. Tulipan N, Hernanz-Schulman M, Bruner JP. Reduced hindbrain herniation after intrauterine myelomeningocele repair: A report of four cases. *Pediatr Neurosurg* 1998; 29:274-278.
75. Adzick NS, Thom EA, Spong CY, et al. A randomized trial of prenatal versus postnatal repair of myelomeningocele. *N Engl J Med* 2011; 364:993-1004.
76. Shurtleff D. Fetal endoscopic myelomeningocele repair. *Dev Med Child Neurol* 2012; 54:4-5.
77. Simpson JL, Greene MF. Fetal surgery for myelomeningocele? *N Engl J Med* 2011; 364:1076-1077.
78. Chen R, Cros D, Curra A, et al. The clinical diagnostic utility of transcranial magnetic stimulation: report of an IFCN committee. *Clin Neurophysiol* 2008; 119:504-532.
79. Frye RE, Rotenberg A, Ousley M, Pascual-Leone A. Transcranial magnetic stimulation in child neurology: current and future directions. *J Child Neurol* 2008; 23:79-96.
80. Kobayashi M, Pascual-Leone A. Transcranial magnetic stimulation in neurology. *Lancet Neurol* 2003; 2:145-156.
81. Weber M, Eisen AA. Magnetic stimulation of the central and peripheral nervous systems. *Muscle Nerve* 2002; 25:160-175.
82. Ugawa Y, Rothwell JC, Day BL, Thompson PD, Marsden CD. Magnetic stimulation over the spinal enlargements. *J Neurol Neurosurg Psychiatry* 1989; 52:1025-1032.
83. Macdonell RA, Cros D, Shahani BT. Lumbosacral nerve root stimulation comparing electrical with surface magnetic coil techniques. *Muscle Nerve* 1992; 15:885-890.
84. Chokroverty S, Flynn D, Picone MA, Chokroverty M, Belsh J. Magnetic coil stimulation of the human lumbosacral vertebral column: site of stimulation and clinical application. *Electroencephalogr Clin Neurophysiol* 1993; 89:54-60.
85. Falck B, Stalberg E. Motor nerve conduction studies: measurement principles and interpretation of findings. *J Clin Neurophysiol* 1995; 12:254-279.
86. Schulte-Mattler WJ, Jakob M, Zierz S. Assessment of temporal dispersion in motor nerves with normal conduction velocity. *Clin Neurophysiol* 1999; 110:740-747.
87. Johnsen B, Fuglsang-Frederiksen A, de Carvalho M, Labarre-Vila A, Nix W, Schofield I. Amplitude, area and duration of the compound muscle action potential change in different ways over the length of the ulnar nerve. *Clin Neurophysiol* 2006; 117:2085-2092.
88. Classen J, Binkofski F, Kunesch E, Benecke R. Magnetic stimulation of peripheral and cranial nerves. In: Pascual-Leone A, Davey NJ, Rothwell J, Wassermann EM, Puri BK, eds. *Handbook of transcranial magnetic stimulation*. 1st ed. London: Arnold, 2002: 185-195.
89. Hess CW, Mills KR, Murray NM. Responses in small hand muscles from magnetic stimulation of the human brain. *J Physiol* 1987; 388:397-419.
90. Di Lazzaro V, Restuccia D, Oliviero A, et al. Effects of voluntary contraction on descending volleys evoked by transcranial stimulation in conscious humans. *J Physiol* 1998; 508:625-633.
91. Rossi S, Hallett M, Rossini PM, Pascual-Leone A. Safety, ethical considerations, and application guidelines for the use of transcranial magnetic stimulation in clinical practice and research. *Clin Neurophysiol* 2009; 120:2008-2039.
92. Gilbert DL, Garvey MA, Bansal AS, Lipps T, Zhang J, Wassermann EM. Should transcranial magnetic stimulation research in children be considered minimal risk? *Clin Neurophysiol* 2004; 115:1730-1739.

Part one

Neurophysiological studies

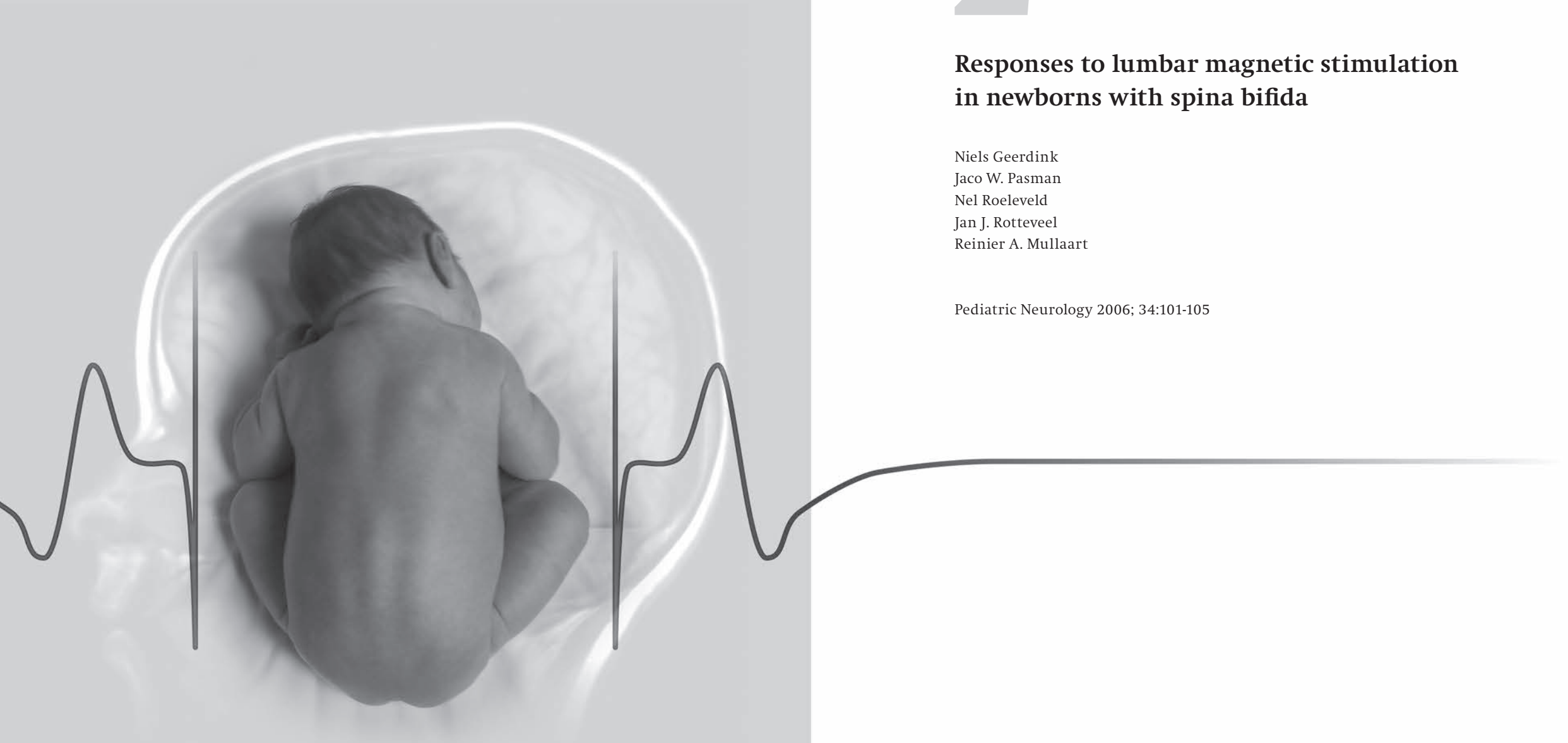

2

Responses to lumbar magnetic stimulation in newborns with spina bifida

Niels Geerdink
Jaco W. Pasman
Nel Roeleveld
Jan J. Rotteveel
Reinier A. Mullaart

Pediatric Neurology 2006; 34:101-105

Abstract

Searching for a tool to quantify motor impairment in spina bifida, transcranial and lumbar magnetic stimulation were applied in affected newborn infants. Lumbar magnetic stimulation resulted in motor evoked potentials in both the quadriceps muscle and the tibialis anterior muscle in most (11/13) subjects. However, transcranial magnetic stimulation did not lead to any response at all. A strong left-to-right correlation existed for amplitude and for latency. Lumbar magnetic stimulation proved to be applicable in newborn infants with spina bifida. Although current concepts regarding spina bifida suppose lower motor neuron dysfunction, the results of this study suggest that lower motor neuron integrity is at least partly preserved after birth. Transcranial magnetic stimulation does not lead to responses in healthy newborn infants because of insufficient synaptogenesis, myelinogenesis and axon thickness. Therefore, conclusions on upper motor neuron function in spina bifida cannot be drawn. To what extend the method used here can achieve the aim to quantify motor impairment is a matter of further study.

Introduction

Motor evoked potentials (MEPs) evoked by magnetic stimulation might be relevant in quantifying motor impairment in newborn infants with spina bifida. In magnetic stimulation, the cortex and the cervical and lumbar nerve roots can be stimulated using an external coil and MEPs can be recorded from limb muscles after stimulation [1]. Magnetic stimulation has a diagnostic value in neurological disorders in which the corticospinal tract, the spinal cord, motor neurons, nerve roots, and peripheral nerves are involved [2,3]. Furthermore, magnetic stimulation is a safe and non-invasive method that is easily used and well tolerated [4-6]. In children, magnetic stimulation has been applied in motor disorders and has been demonstrated to be of prognostic value in congenital hemiplegia [7-9].

Spina bifida is a congenital malformation of the nervous system, which causes considerable motor impairment and disability. This disability mainly depends on the neonatal neurological deficit [10]. This neurological deficit reflects the integrity of motor pathways over and under the spinal lesion and is traditionally assessed by neurological examination. Nevertheless, precise determination the motor deficit might be difficult in newborn infants with spina bifida. Electromyography and nerve conduction studies have been described [11,12], but valid additional instruments to assess the motor deficit in newborn infants with spina bifida are unavailable. However, magnetic stimulation seems an appropriate tool to evaluate the integrity of motor pathways over and caudally from the spinal anomaly. Therefore, this study investigated the applicability of magnetic stimulation in newborn infants with spina bifida in order to find an additional tool to quantify motor deficit. We hypothesize that upper and lower motor neurons are present after birth and that the integrity of them can be assessed by magnetic stimulation. The clinical value, methodological aspects, and implications of magnetic stimulation for the pathophysiology of spina bifida will be discussed in this chapter.

Methods

Subjects

Thirteen newborn infants (7 boys and 6 girls) with spina bifida, born at or referred to the Radboud University Nijmegen Medical Centre between January 1, 2002 and December 31, 2003 were enrolled in the study. Patient characteristics are listed in Table 1. Birth weight was normal in most newborns. Two infants were born premature at a gestational age of 35 and 37 weeks. The spinal anomalies were classified as myelomeningocele (7), myelocele (3), lipomyelomeningocele (1) and

Table 1 Patient characteristics (n=13)

Gender	
Boy	7
Girl	6
Gestational age	
≤ 37 weeks	2
38 – 42 weeks	11
Birth weight	
< 2500 gm	1
2500 – 4000 gm	11
> 4000 gm	1
Spinal anomaly	
Myelomeningocele	7
Myelocele	3
Lipomyelomeningocele	1
Occult spinal dysraphism	2
Cerebral co-morbidity on MRI [a]	
Hydrocephalus	9
Chiari II malformation	10
Level of motor deficit	
Cranial to L2	5
L2 – S1	5
Caudally to S1	3

[a] Besides Hydrocephalus and Chiari II malformation no other major intracranial abnormalities were present

occult spinal dysraphism (2). The median age at investigation was two days (range 1-15 days). At time of investigation, the perinatal period was uneventful for all subjects. The study protocol was approved by the local Committee on Human Research.

Neurophysiological assessment

In all subjects, magnetic stimulation was performed by the same researcher (J.P.) using a Magstim 200 magnetic stimulator and 90 mm circular coil (outer diameter 130 mm, inner diameter 50 mm). The procedure took place before surgical closure of the spinal anomaly. Magnetic stimulation (100% intensity) of the motor cortex (transcranial) and the lumbar nerve roots was performed in prone position with the coil positioned tangentially over the vertex and over the lumbar spine, respectively. For each muscle, magnetic stimulation was repeated several times with little variation in coil position in search of the best reproducible MEPs. The MEP with the highest amplitude was used for further

analysis. MEPs were recorded bilaterally from the quadriceps femoris muscle and the tibialis anterior muscle using surface electrodes and an Oxford Synergy electromyograph (band-pass filter 20 Hz and 3 kHz, amplifier range 100 mV and display sensitivity of 0.5 mV/division). Compound muscle action potentials (CMAPs) were obtained from the tibialis anterior muscle by supramaximal percutaneous electrical stimulation of the peroneal nerve at the lateral popliteal fossa as controls. Onset latencies and peak-to-peak amplitudes were measured (Figure 1). As the measured values were not normally distributed, Spearman rank-order correlations were calculated to ascertain left-to-right correlation for latency and amplitude using statistically package SPSS 10.0.

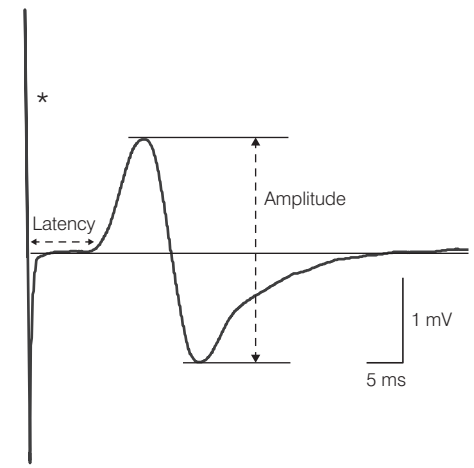

Figure 1 Motor evoked potential recorded from quadriceps femoris muscle after lumbar magnetic stimulation. Asterisk indicates stimulus artifact.

Results

All subjects tolerated magnetic stimulation without discomfort. An overview of the MEPs is shown in Table 2. Lumbar magnetic stimulation resulted in both quadriceps femoris MEPs and tibialis anterior MEPs in most subjects (11/13). In one subject only tibialis anterior MEPs were obtained, and in another subject only quadriceps femoris MEPs were obtained. Control tibialis anterior CMAPs after electrical stimulation of the peroneal nerve were congruent with tibialis anterior MEPs after lumbar magnetic stimulation: when lumbar magnetic stimulation did not lead to a reponse, neither did electrical stimulation. In contrast

Table 2 Responses to magnetic and electrical stimulation in newborn infants with spina bifida

Stimulus	Stimulus site	Target muscle	Responses		
Magnetic	Lumbar roots	TA	+	+[b]	-
	Lumbar roots	QF	+[a]	-	+
	Motor cortex	TA/QF	-	-	-
Electrical	Peroneal nerve	TA	+	+	-
Number of newborn infants			11	1	1

[a] One subject demonstrated only responses in the left QF after lumbar stimulation.
[b] This subject demonstrated only responses in the left TA after lumbar stimulation
TA, tibialis anterior muscle; QF, quadriceps femoris muscle;
+, response present; -, no response present

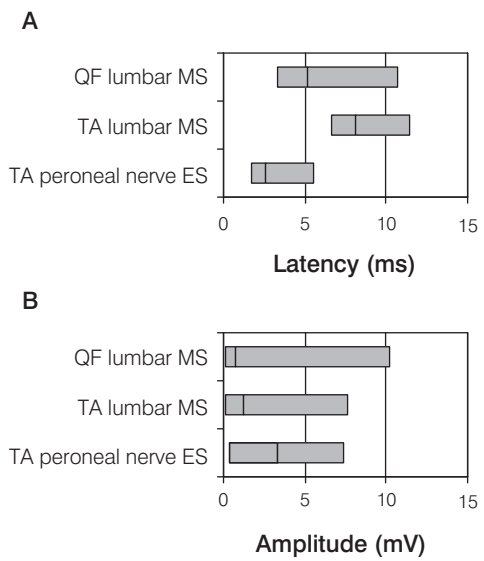

Figure 2 Distributions for latency (**A**) and amplitude (**B**); bar indicates range and vertical line indicates median value; ES, electrical stimulation; MS, magnetic stimulation; TA, tibialis anterior muscle; QF, quadriceps femoris muscle.

to lumbar magnetic stimulation, transcranial magnetic stimulation did not result in MEPs in any of the subjects.

Figure 2 depicts the distributions of latency and amplitude. In all cases, the tibialis anterior latency was longer after lumbar magnetic stimulation than after electrical stimulation and the tibialis anterior latency was longer than the quadriceps femoris latency after lumbar magnetic stimulation. In contrast to the distributions of latency, the distributions of amplitude were broad and they all covered the same range. In all subjects except three, the tibialis anterior amplitude was higher after electrical stimulation than after lumbar magnetic stimulation. Despite a broad distribution, the left-to-right correlation for amplitude was strong and statistically significant in all target muscles both after electrical stimulation ($r_{\text{tibialis anterior}} = 0.76$; $p<0.05$) and after lumbar magnetic stimulation ($r_{\text{tibialis anterior}} = 0.92$; $p<0.001$ and $r_{\text{quadriceps femoris}}$ 0.81; $p<0.005$) (Table 3). For tibialis anterior latency after electrical stimulation a left-to-right correlation did not exist, but after lumbar magnetic stimulation the correlation coefficient was 0.55 ($p<0.08$) for the tibialis anterior latency and 0.87 ($p<0.001$) for the quadriceps femoris latency.

Table 3 Left-to-right correlation for latency and amplitude

Stimulus	Stimulus site	Target Muscle	Latency		Amplitude		n
			r	P-value	r	P-value	
Magnetic	Lumbar roots	TA	0.55	0.08	0.92	<0.001	11
	Lumbar roots	QF	0.87	<0.001	0.81	<0.005	11
Electrical	Peroneal nerve	TA	-0.01	0.98	0.76	<0.05	12

TA, tibialis anterior muscle; QF, quadriceps femoris muscle; r, Spearman's rho;
n, number of subjects.

Discussion

This study demonstrates that MEPs are obtainable after lumbar magnetic stimulation in newborn infants with spina bifida. As magnetic stimulation was easily performed and well tolerated without discomfort, lumbar magnetic stimulation is considered to be applicable in newborn infants with spina bifida. Remarkably, MEPs could be obtained in almost all subjects, even in subjects with a severe spinal anomaly and completely paralyzed lower limbs. Only in two subjects unilateral MEPs were elicited; no specific difficulties were encountered

in stimulating these subjects, neither did these unilateral MEPs correspond to an extreme asymmetric motor deficit at neurological examination. The presence of MEPs in almost all subjects implies that excitable neural tissue is present at or caudally from the spinal anomaly, even in case of completely paralyzed lower limbs. In normal subjects, excitation after lumbar magnetic stimulation occurs at the point where motor nerve roots leave the intervertebral foramina. At this point, the magnetic field focuses and the stimulus threshold is low [13-15]. Because the configuration of the spinal column insulates the spinal cord, it is impossible to stimulate the spinal cord directly [13]. In case of spina bifida, this insulation is mostly absent and the neuroplacode is exposed to the surface. In addition, the stimulus threshold of the exposed neuroplacode is probably lower than the threshold of covered spinal cord in normal infants. Therefore, excitation might occur at the neuroplacode and thus at the spinal cord directly in newborn infants with spina bifida.

Despite not knowing where excitation occurs exactly, the recorded MEPs prove that the integrity of lower motor neurons is at least partly preserved after birth. In accordance to this, Stark and Drummond [11] reported findings from electromyography and nerve conduction studies consistent with preserved lower motor neuron activity within 13 hours after birth. In contrast, Sival et al. [12] suggested lower motor neuron damage owing to the presence of denervation potentials and the disappearance of lower limb movements within 48 hours after birth. In the present study, needle electromyography was not performed to demonstrate denervation potentials, but the results indicate that lower motor neuron activity is demonstrable in most newborn infants after 48 hours of age, even if corresponding movement patterns are absent. These findings are supported by neuropathological studies [16,17]. In spina bifida, lower motor neurons are present at several levels in the spinal anomaly, and anterior nerve roots extend from the anterior horn cells at the proper position in the malformed spinal cord innervating corresponding muscles. Furthermore, the presence of lower motor neurons can be explained from the pathogenesis of spina bifida. According to the paradigm that spina bifida results from an incomplete fusion of the dorsal side of the neural tube, the ventral plate of the neural tube is probably less affected than the dorsal plate. Therefore, anterior horn cells are still able to develop and grow into the lower limbs. The current study shows that the lower motor neurons present at neuropathological examination also have, to some extend, functional qualities at neurophysiological examination. The clinical significance of these findings is matter of further study. As magnetic stimulation has proven to be of prognostic value in other neurological disorders [7-9], we hypothesize that the obtained MEPs might have a prognostic significance toward the outcome of spina bifida.

In contrast to lumbar magnetic stimulation, transcranial magnetic stimulation did not result in recordable MEPs in the lower limbs. Even in three newborn infants who did not demonstrate any loss of motor function and could therefore be considered as control subjects, MEPs were absent. These findings are in accordance with most other studies. In healthy infants, reliable MEPs after cortical magnetic stimulation can not be obtained before the age 4 years, because of the immaturity of the brain resulting in high stimulus thresholds [18,19]. This immaturity has its consequence in a combination of insufficient synaptogenesis, myelinogenesis, and axon thickness [19-21]. In case of spina bifida, it is plausible that the spinal lesion and associated cerebral malformations (hydrocephalus, Chiari II malformation) also affect cortical excitability and central motor conduction. Our study design did not enable us to investigate this. On the other hand, Koh and Eyre [6] were able to elicit MEPs after transcranial magnetic stimulation. They used a facilitating isomeric muscle contraction to lower the stimulus threshold. In the present study, this method of facilitation was not applied. First, it is hardly possible to achieve an isomeric muscle contraction in newborn infants with paralyzed lower limbs. Second, an isomeric muscle contraction could confound the results for latency and amplitude through different levels of facilitation [22]. Because of the impossibility to obtain responses after transcranial magnetic stimulation in newborn infants, conclusions about motor nerve conduction over the spinal anomaly and regarding upper motor neuron function cannot be drawn.

In this explorative study, we looked for reproducible MEPs, but only the MEP with the highest amplitude was recorded. Although the amplitude depends on the number of axons stimulated, the direction of the current in the coil, and the lumbar level of stimulation [13], a strictly defined coil position was not applied for two reasons. First, the abnormal spinal anatomy, in some cases large celes, hampers precise positioning. As a result of the abnormal anatomy, the segmental innervation is deviant resulting in an abnormal course of the nerve roots exiting the spinal column. Therefore, it is impossible to stimulate every subject at the same neurosegmental motor level. Second, the relatively large magnetic field in relation to the body proportions of a newborn infant means that variation in coil position will be of little influence on the MEPs. Moreover, this influence only involves the amplitude and not the latency [13]. Therefore, using the MEPs with the highest amplitude might be the best method to obtain a certain consistency, allowing comparison of findings between subjects.

In some infants, magnetic stimulation was also performed with a smaller circular coil (diameter 70 mm) and with a figure-of-eight coil (double 70 mm). Although not systematically evaluated, the stimulus threshold was lower using the 90 mm circular coil, and MEPs elicited with this coil seem to have higher amplitudes and to yield better reproducibility. This is in contrast with other

reports in which the focal magnetic field produced by the figure-of-eight coil results in a higher amplitude [23,24]. To achieve this, the magnetic field has to be focused on the point where excitation occurs. In spina bifida, the spinal anatomy is deviant and the point of excitation may differ from subject to subject. Therefore, the focal aspect of the figure-of-eight coil might hamper adequate stimulation in spina bifida. The larger and less focal magnetic field generated by the 90 mm circular coil makes recurrent stimulation with equal intensity easier to perform.

The reliability of the results is supported by the latencies assessed. The distributions of latency, which are shown in figure 2, are narrow and they are in accordance with the distances between point of stimulation and point of recording. These narrow distributions agree with results from other studies [13-15]. On the other hand, the distributions of amplitude are broad, which is also in accordance with results from other studies. In addition, the reliability is supported by the results of electrical peroneal nerve stimulation. If lumbar magnetic stimulation did not reveal a response, neither did electrical stimulation. This strongly suggests that false negative MEPs after lumbar magnetic stimulation are unlikely. Furthermore, a strong left-to-right correlation existed, especially for the amplitude. Because both sides were investigated separately, this correlation could not be based on simultaneous stimulation of left and right muscle. For the tibialis anterior latency after electrical stimulation, this correlation was not found. The short distance between point of stimulation (popliteal fossa) and point of recording (tibialis anterior muscle), which is the shortest distance of all stimulus-response-combinations, could be an explanation. The short distance may result in large measurement errors, which might hamper proving a left-to-right correlation.

In conclusion, lumbar magnetic stimulation is applicable in newborn infants with spina bifida. Excitable neural tissue is present at or caudally from the spinal anomaly. Although current concepts regarding spina bifida suppose lower motor neuron dysfunction, our results suggest that lower motor neuron integrity is at least partly preserved after birth. Transcranial magnetic stimulation does not lead to MEPs in healthy newborn infants because of insufficient synaptogenesis, myelinogenesis and axon thickness. Therefore, conclusions on upper motor neuron function in neonatal spina bifida cannot be drawn. Magnetic stimulation might have additional value to the clinical assessment of spina bifida. However, to what extend our method brings closer our initial aim to quantify motor impairment, is a matter of further study.

Acknowledgments

The authors thank Yvonne M Visco, Electroneurodiagnostic Technologist.

References

1. Barker AT, Jalinous R, Freeston IL. Non-invasive magnetic stimulation of human motor cortex. *Lancet* 1985; 1:1106-1107.
2. Curra A, Modugno N, Inghilleri M, Manfredi M, Hallett M, Berardelli A. Transcranial magnetic stimulation techniques in clinical investigation. *Neurology* 2002; 59:1851-1859.
3. Di Lazzaro V, Oliviero A, Profice P, et al. The diagnostic value of motor evoked potentials. *Clin Neurophysiol* 1999; 110:1297-1307.
4. Kandler R. Safety of transcranial magnetic stimulation. *Lancet* 1990; 335:469-470.
5. Wassermann EM. Risk and safety of repetitive transcranial magnetic stimulation: report and suggested guidelines from the International Workshop on the Safety of Repetitive Transcranial Magnetic Stimulation, June 5-7, 1996. *Electroencephalogr Clin Neurophysiol* 1998; 108:1-16.
6. Koh TH, Eyre JA. Maturation of corticospinal tracts assessed by electromagnetic stimulation of the motor cortex. *Arch Dis Child* 1988; 63:1347-1352.
7. Carr LJ, Harrison LM, Evans AL, Stephens JA. Patterns of central motor reorganization in hemiplegic cerebral palsy. *Brain* 1993; 116:1223-1247.
8. Maegaki Y, Maeoka Y, Ishii S, et al. Mechanisms of central motor reorganization in pediatric hemiplegic patients. *Neuropediatrics* 1997; 28:168-174.
9. Vandermeeren Y, Bastings E, Fadiga L, Olivier E. Long-latency motor evoked potentials in congenital hemiplegia. *Clin Neurophysiol* 2003; 114:1808-1818.
10. Oakeshott P, Hunt GM. Long-term outcome in open spina bifida. *Br J Gen Pract* 2003; 53:632-636.
11. Stark GD, Drummond M. Neonatal electromyography and nerve conduction studies in myelomeningocele. *Neuropädiatrie* 1972; 3:409-420.
12. Sival DA, van Weerden TW, Vles JS, et al. Neonatal loss of motor function in human spina bifida aperta. *Pediatrics* 2004; 114:427-434.
13. Ugawa Y, Rothwell JC, Day BL, Thompson PD, Marsden CD. Magnetic stimulation over the spinal enlargements. *J Neurol Neurosurg Psychiatry* 1989; 52:1025-1032.
14. Macdonell RA, Cros D, Shahani BT. Lumbosacral nerve root stimulation comparing electrical with surface magnetic coil techniques. *Muscle Nerve* 1992; 15:885-890.
15. Chokroverty S, Flynn D, Picone MA, Chokroverty M, Belsh J. Magnetic coil stimulation of the human lumbosacral vertebral column: site of stimulation and clinical application. *Electroencephalogr Clin Neurophysiol* 1993; 89:54-60.
16. Lendon RG. Neuron population in the lumbosacral cord of myelomeningocele children. *Dev Med Child Neurol* 1969; 11(Suppl.20):82-85.
17. Hori A. A review of the morphology of spinal cord malformations and their relation to neuro-embryology. *Neurosurg Rev* 1993; 16:259-266.
18. Nezu A, Kimura S, Uehara S, Kobayashi T, Tanaka M, Saito K. Magnetic stimulation of motor cortex in children: maturity of corticospinal pathway and problem of clinical application. *Brain Dev* 1997; 19:176-180.
19. Muller K, Homberg V, Lenard HG. Magnetic stimulation of motor cortex and nerve roots in children. Maturation of cortico-motoneuronal projections. *Electroencephalogr Clin Neurophysiol* 1991; 81:63-70.
20. Garvey MA, Ziemann U, Bartko JJ, Denckla MB, Barker CA, Wassermann EM. Cortical correlates of neuromotor development in healthy children. *Clin Neurophysiol* 2003; 114:1662-1670.
21. Moll GH, Heinrich H, Wischer S, Tergau F, Paulus W, Rothenberger A. Motor system excitability in healthy children: developmental aspects from transcranial magnetic stimulation. *Electroencephalogr Clin Neurophysiol. Supplement* 1999; 51:243-9.
22. Hess CW, Mills KR, Murray NM. Magnetic stimulation of the human brain: facilitation of motor responses by voluntary contraction of ipsilateral and contralateral muscles with additional observations on an amputee. *Neurosci Lett* 1986; 71:235-240.

23. Maegaki Y, Maeoka Y, Takeshita K. Magnetic stimulation of the lumbosacral vertebral column in children: normal values and possible sites of stimulation. *Electroencephalogr Clin Neurophysiol* 1997; 105:102-108.
24. Cohen LG, Roth BJ, Nilsson J, et al. Effects of coil design on delivery of focal magnetic stimulation. Technical considerations. *Electroencephalogr Clin Neurophysiol* 1990; 75:350-357.

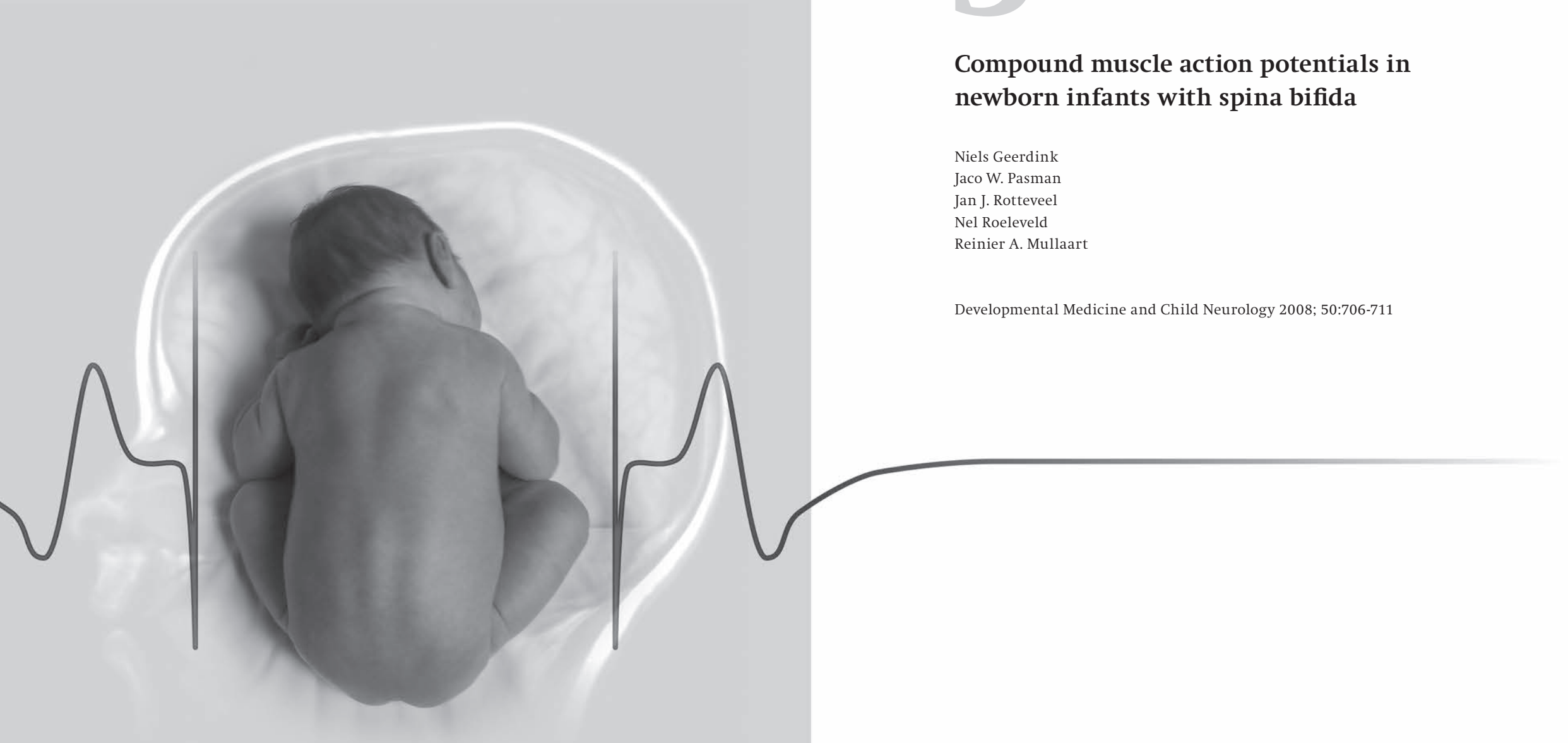

3

Compound muscle action potentials in newborn infants with spina bifida

Niels Geerdink
Jaco W. Pasman
Jan J. Rotteveel
Nel Roeleveld
Reinier A. Mullaart

Developmental Medicine and Child Neurology 2008; 50:706-711

Abstract

The aim of this study was to investigate the relationship between compound muscle action potentials (CMAPs) and neurological impairment in newborn infants with spina bifida. Thirty-one newborn infants (17 males, 14 females, mean gestational age 39 weeks [SD 2]; mean birth weight 3336 grams [SD 496]) with spina bifida were investigated at a median age of 2 days (range 1-18 days). Motor and sensory impairment and muscle stretch reflexes were assessed and neuroimaging was performed. CMAPs were recorded from the tibialis anterior muscle and the gastrocnemius muscle after percutaneous electrical nerve stimulation. CMAPs were obtained in almost all infants. The area under the curve of the CMAP (CMAP area) was associated with motor and sensory impairment and with the presence of muscle stretch reflexes, but not with the morphological level of the spinal anomaly. These associations were stronger for the gastrocnemius muscle than for the tibialis anterior muscle. In conclusion, the CMAP area correlates with neurological impairment in neonatal spina bifida and provides an estimate of residual lower motor neuron function in affected spinal segments. The assessment of CMAPs after percutaneous electrical nerve stimulation is recommended as an additional instrument to the clinical neurological examination and imaging studies.

Introduction

Spina bifida is a congenital malformation of the nervous system, which usually results in severe disabilities [1-4]. These disabilities mainly depend on neonatal neurological impairment, especially on sensory impairment [5]. Traditionally, neurological impairment is assessed by clinical examination, but the clinical neurological examination of a newborn infant with spina bifida may be complex and to a certain extent subjective. Potentially confounding factors are inconsistencies between patterns of muscle activity and neurosegmental innervation [6], the distinction between normal lower limb movements and purely reflex lower limb movements [7], and changing movement patterns in the first week of life [8]. In the past few years, neuroimaging is performed in most centers as well, but the morphological level of the spinal anomaly is only partly related to the neurological impairment [1,8,9]. An additional instrument that provides objective information about neurological impairment is desirable and may improve preoperative clinical decision-making in newborn infants with spina bifida.

Motor nerve conduction study may be an appropriate additional diagnostic instrument as it provides a diagnostic guide in several disorders [10]. Previously, we reported on the presence of compound muscle action potentials (CMAPs) in lower limb muscles after percutaneous electrical nerve stimulation in almost all newborn infants with spina bifida [11]. Therefore, the presence of a CMAP as such is of no diagnostic use, but the magnitude of the CMAP, which reflects the number and size of the activated motor units, may be of diagnostic value.

The aim of the present study was to investigate the association between the magnitude of the CMAP, as represented by the area under the curve (CMAP area), and neurological impairment in newborn infants with spina bifida considering a potential diagnostic value of the CMAP. We hypothesized that a larger CMAP area is associated with less neurological impairment. The clinical value, methodological aspects, and pathophysiological considerations are discussed.

Method

Participants

Thirty-one newborn infants (17 boys, 14 girls) with spina bifida born at or referred to the Radboud University Nijmegen Medical Centre were enrolled in the study. Fourteen of these children were diagnosed antenatally. Most infants were born at term (mean gestational age 39 weeks [SD 2]) and had a birth weight appropriate for gestational age. The mean birth weight was 3336 grams (SD 496) with a SD score to the population norm of 0.9. The mean head circumference was

35.6 cm [SD 2.8] with a SD score to the population norm of -0.3. At the time of investigation, the perinatal period was uneventful for all infants. The Regional Committee on Research involving Human Subjects approved the study protocol. Informed consent was obtained from all parents.

Clinical assessment

The clinical assessment was performed before surgical closure of the spinal anomaly and was based on repeated physical examinations, and brain and spinal cord MR imaging within 72 hours after birth. Motor impairment was assessed on each side separately and scored according to the lowest spinal segment with lasting non-stereotypical, non-reflex lower limb movements. Where motor impairment was thoracic, we did not attempt to assign it to a single spinal segment, because we considered this as too inaccurate. Sensory impairment was assessed on each side separately and scored according to the lowest dermatome with a behavioral reaction to pin prick. Muscle stretch reflexes were scored as present or absent. On MR images, the spinal anomaly was classified according to Tortori-Donati et al. [12] and its morphological level and its size was described by identifying the cranial and caudal margins of the spinal anomaly with the corresponding vertebra. Cerebral comorbidity was assessed by the presence or absence of hydrocephalus, Chiari II malformation, and corpus callosum dysgenesis.

Neurophysiologial assessment

The neurophysiological assessment took place at a median age of two days (range 1-18 days) before surgical closure of the spinal anomaly. The same assessor performed the procedure in all infants. CMAPs were obtained from the tibialis anterior and the gastrocnemius muscle by supramaximal percutaneous electrical stimulation of the peroneal and the posterior tibial nerve, respectively, at the popliteal fossa. CMAPs were recorded using surface electrodes (tendon-belly montage) and an Oxford Synergy electromyograph (Oxford Instruments, Old Woking, Surrey, UK; band-pass filter 20 Hz and 3 kHz, amplifier range 100 mV, and display sensitivity of 0.5 mV/division). The latency was measured from the stimulus artifact to the onset of the first negative deflection of the CMAP. The area under curve of the first negative wave was calculated as a measure of the magnitude of the CMAP (Figure 1). Measurements of the gastrocnemius muscle were obtained in only 18 newborn infants as it was added to the protocol later during the investigation.

Analysis

As the gastrocnemius muscle was added to the protocol later, two subgroups were present in our study. Possible differences in clinical impairment and CMAP

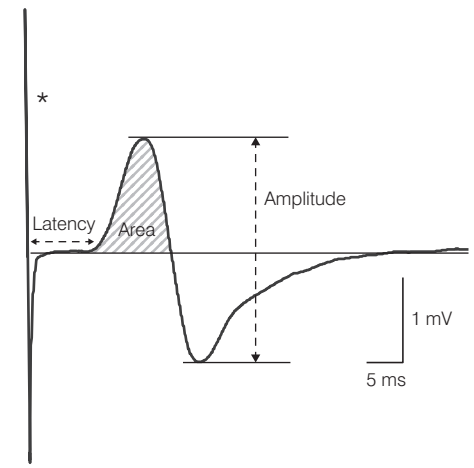

Figure 1 Measurements of the compound muscle action potential. Asterisk indicates stimulus artifact.

measurements between these subgroups were analyzed using the Mann-Whitney U test or the Fisher exact test. In order to allow statistical tests, the scores for motor and sensory impairment and morphological level were consecutively numbered from 1 (T1) to 22 (S5). These variables were handled as continuous variables. In addition, the scores for motor impairment were dichotomized according to the spinal segmental innervation of the investigated muscles. This dichotomy was achieved by dividing the variable for both muscles separately into impairment cranial to the spinal segments innervating the muscle or impairment at or caudal to these segments. For that purpose the spinal segmental innervation according to Sharrard [13] was applied. This resulted in dichotomization for the tibialis anterior muscle into above L4 and from L4 downward and for the gastrocnemius muscle into above S1 and from S1 downward. The CMAP measurements were summarized in box plots to show similarities, differences, and associations between CMAP and impairment measurements. Associations between CMAP and impairment measurements were further analyzed with Spearman rank correlation coefficients and in case of dichotomous variables with the Mann-Whitney U test. In addition, the CMAP area data were logistically transformed to generate approximately normal distributions. Multivariable linear regression analyses were then performed for the subgroup in which both muscles were investigated. In these analyses, motor and sensory impairment were defined as dependent variables and the CMAP areas as independent variables. Statistical analyses were performed using SPSS version 14.0.

Results

Clinical impairment

The clinical impairment measurements of the investigated newborn infants are summarized in Table 1. In the 31 infants included in the study, motor impairment was thoracic in 10 infants, lumbar in 14, sacral in seven, and clearly asymmetrical in four infants. Sensory impairment was thoracic in six infants, lumbar in 15, sacral in 10, and clearly asymmetric in five infants. The patellar reflex was present in 15 infants, the Achilles reflex was present in six of these 15 infants, and in one infant the Achilles reflex was present and the patellar reflex was absent. In the remaining 15 infants, both reflexes were absent. Most spinal anomalies could be classified as myelomeningocele (n = 23), whereas four anomalies were classified as myelocele. The other four anomalies were other types of spina bifida. The morphological level was thoracic in six infants, lumbar in 24, and sacral in one infant. Most spinal anomalies covered five or more vertebrae. All infants with myelomeningocele or myelocele had hydrocephalus and Chiari II malformation. Corpus callosum dysgenesis was identified in 24 of these infants.

Regarding the clinical impairment measurements, no differences were present between the subgroup in which only the tibialis anterior muscle was investigated and the subgroup in which both the gastrocnemius and the tibialis anterior muscle were investigated.

Compound muscle action potentials

The muscles responded to stimulation in almost all infants: for the tibialis anterior muscle 26 of the 31, and for the gastrocnemius muscle 15 of the 18 infants. When the gastrocnemius muscle did not respond, neither did the tibialis anterior muscle.

The distributions of the CMAP latency and the CMAP area are depicted in Figure 2. Regarding the tibialis anterior latency and CMAP area, no differences were present between the subgroup in which only the tibialis anterior muscle was investigated and the subgroup in which both the gastrocnemius muscle and the tibialis anterior muscle were investigated.

Associations between CMAP and clinical impairment

We found strong associations between the CMAP area and motor and sensory impairment, and muscle stretch reflexes (i.e. the less the impairment, the larger the CMAP area). No associations were found between latency and impairment, between CMAP measurements and morphological characteristics of the spinal anomaly or between CMAP measurements and cerebral comorbidity (hydrocephalus, Chiari II malformation, and corpus callosum dysgenesis).

Table 1 Impairment measurements (n=31)

Impairment	Number
Motor impairment	
Thoracic[a]	10
Lumbar[b]	14
Sacral	7
Sensory impairment	
Thoracic[c]	6
Lumbar[d]	15
Sacral	10
Muscle stretch reflexes	
Both reflexes absent	15
Patellar reflex present, Achilles reflex absent[e]	9
Achilles reflex present[e]	7
Type of spinal anomaly	
Myelomeningocele	23
Myelocele	4
Lipomyelomeningocele	1
Meningocele	1
Other type of closed spina bifida	2
Cranial margin of spinal anomaly	
Thoracic	6
Lumbar	24
Sacral	1
Size of spinal anomaly	
≥ 10 vertebrae	4
7-9 vertebrae	9
5-6 vertebrae	14
< 5 vertebrae	4
Cerebral co-morbidity	
Hydrocephalus	27
Chiari II malformation	27
Corpus callosum dysgenesis	24

[a] Two asymmetric (L1-Th; Th-L2)
[b] Two asymmetric (L5-S1; S1-L5)
[c] One asymmetric (Th12-L1)
[d] Four asymmetric (L2-L3 [2]; L4-L5; L5-S2)
[e] One asymmetric
L, lumbar; Th, thoracic

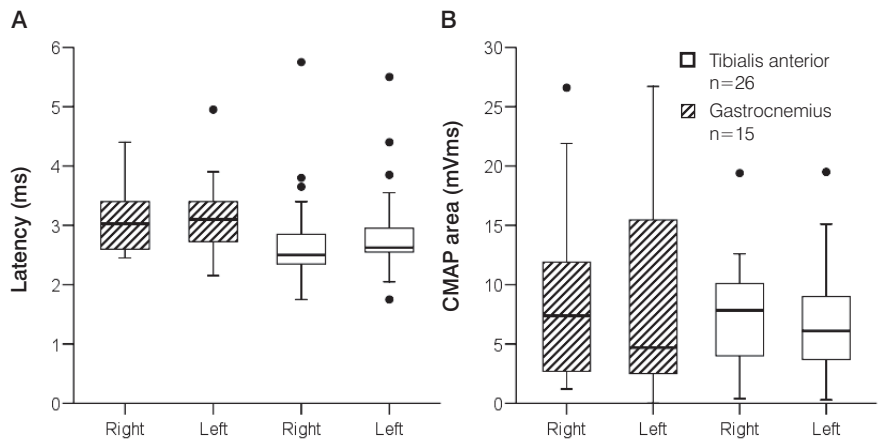

Figure 2 Distribution of CMAP latency (**A**) and CMAP area (**B**). The horizontal bar, upper and lower borders of each box mark median, 25th, and 75th percentiles, respectively. Error bars mark 5th and 95th percentiles. Points lie beyond 5th and 95th percentiles. CMAP, compound muscle action potential; CMAP area, area under the curve of the first negative wave of the CMAP.

The associations between the CMAP area and the muscle stretch reflexes are presented in Figure 3. The CMAP areas of both muscles were almost negligible when both reflexes were absent. The gastrocnemius CMAP area was considerably larger when the patellar reflex was present and even larger when the Achilles reflex was present as well. This applied to a lesser extent to the tibialis anterior muscle: the CMAP area was slightly larger when the patellar reflex was present, but did not increase any further when the Achilles reflex was present as well.

The associations between the CMAP area and motor and sensory impairment are specified in Figure 4. Correlation coefficients for these associations are presented in Table 2. The associations were stronger for motor impairment than for sensory impairment, but both associations were clearly stronger than the weak associations between the CMAP area and the morphological level of the spinal anomaly. These findings applied in particular to the gastrocnemius muscle and to a lesser extent to the tibialis anterior muscle.

The analyses concerning motor impairment as a dichotomous variable are illustrated in Figure 5. This figure clearly shows that the CMAP areas of both the gastrocnemius and the tibialis anterior muscle were statistically significantly larger when motor impairment was at or caudal to the spinal segmental innervation

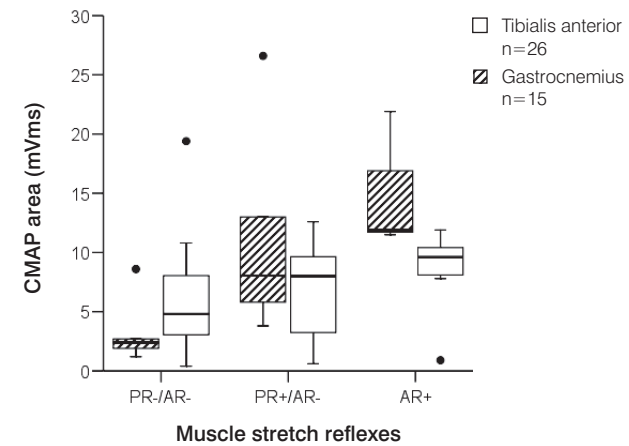

Figure 3 Associations between CMAP area and muscle stretch reflexes. Data are expressed as described for Figure 2. As the results for both sides were almost identical, only data for the right side are presented. CMAP area, area under the curve of the first negative wave of the compound muscle action potential; AR, Achilles reflex; PR, patellar reflex; plus sign indicates reflex present; minus sign indicates reflex absent.

Table 2 Spearman rank correlation of CMAP area with motor and sensory impairment and morphological level of the spinal anomaly

CMAP area	Motor impairment		Sensory impairment		Level of the spinal anomaly	
	Right	Left	Right	Left	Right	Left
Gastrocnemius, n=15	0.78***	0.70***	0.42	0.58**	0.11	0.14
Tibialis anterior, n=26	0.46**	0.34*	0.36*	0.30	0.21	0.20

* p<0.10; ** p<0.05; *** p<0.01.
CMAP area, area under the curve of the first negative wave of the compound muscle action potential

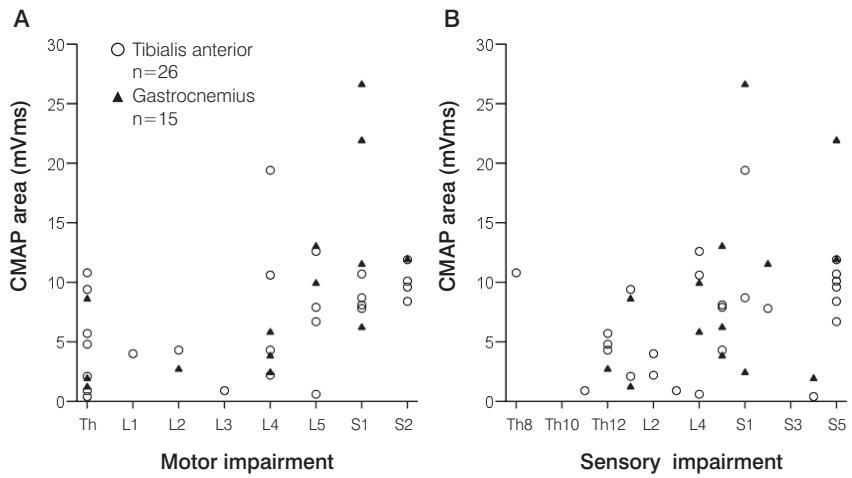

Figure 4 Associations between CMAP area and motor impairment (**A**) and sensory impairment (**B**). As results for left side were almost identical, only data for right side are presented. CMAP area, area under the curve of the first negative wave of the compound muscle action potential; L, lumbar; Th, thoracic.

of the muscle in question, than when motor impairment was cranial to these segments.

Multivariable linear regression analyses showed that the CMAP areas of both muscles together were a better predictor for motor impairment than for sensory impairment. In all analyses, the gastrocnemius CMAP area determined the majority of the predictive value for motor and sensory impairment (Table 3).

Discussion

The present study shows strong associations between the CMAP and the severity of spina bifida in newborn infants. To be more specific, the magnitude of the CMAP, represented by the area under the curve, relates to the presence of muscle stretch reflexes and motor impairment, and to a lesser degree to sensory impairment. To our best knowledge, this has not been reported before. Although other authors reported motor nerve conduction studies in neonatal spina bifida [14,15], the magnitude of the CMAP was mentioned in only one study [16]. Compatible with our results, other authors also reported responses to be present in almost all assessed muscles. This is also compatible with studies using other

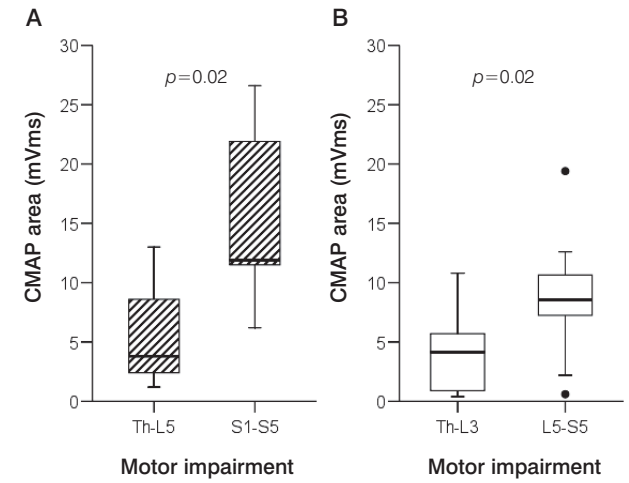

Figure 5 Associations between CMAP area and motor impairment. Data are expressed as described for Figure 2. As the results for both sides were almost identical, only data for the right side are presented. Motor impairment was dichotomized according to segmental innervation of gastrocnemius muscle (**A**) and tibialis anterior muscle (**B**), respectively (see text for details). CMAP area, area under the curve of the first negative wave of the compound muscle action potential; L, lumbar; Th, thoracic; p, P-value based on Mann-Whitney U test.

Table 3 Results of multivariable linear regression for CMAP area predicting motor and sensory impairment[a] (n=15)

Step	Predictor CMAP area	Right		Left	
		R^2	P-value	R^2	P-value
Motor impairment					
1	GC	0.52	0.004	0.67	<0.001
2	GC-TA	0.60	0.01	0.73	0.001
Sensory impairment					
1	GC	0.33	0.03	0.16	0.15
2	GC-TA	0.34	0.10	0.24	0.22

[a] CMAP area data were transformed logistically. CMAP area, area under the curve of the first negative wave of the compound muscle action potential; GC, gastrocnemius muscle; TA, tibialis anterior muscle; R^2, coefficient of determination

methods of stimulation, such as electrical neural plaque stimulation [14,17], faradic muscle stimulation [18,19], and lumbar magnetic stimulation [11]. The presence or absence of a response cannot be a diagnostic criterion, when responses are present in virtually every case. The results in the present study demonstrate that the CMAP area is indeed distinctive and that it may provide an additional measure for neonatal neurological impairment. A larger CMAP area is associated with less neurological impairment.

Before further interpreting the results, some methodological remarks have to be made. To quantify the magnitude of the CMAP, the area under the curve of the first negative wave was calculated. The CMAP area provides an estimate of the amount of functioning motor units [20]. The area was taken instead of the more commonly used amplitude, because the amplitude is more liable to temporal dispersion resulting in a larger variability in the amplitude compared to the area [21,22]. As additional temporal dispersion due to abnormal myelination can be expected in pathological neurons, the CMAP area was considered to reflect the amount of activated motor units most appropriately.

In addition, our assessment of neurological impairment needs consideration. We assessed three modalities of neurological impairment (muscle stretch reflexes, motor and sensory impairment). These modalities are to a certain extent interdependent, but each modality can be affected to a different degree. No consensus exists about which modality is most specific or reliable for determining neurological impairment. Therefore, we used all three modalities in the analyses. The cranial demarcation of impairment to a single spinal segment may be arbitrary. However, more reliable methods are not available [23] and categorization of impairment as thoracic, lumbar, or sacral was not specific enough considering the aim of the study.

Contrasting our findings to CMAPs obtained from healthy newborn infants might be interesting from a pathophysiological point of view. However, valid normative data are not available. To subject healthy newborn infants to neurophysiological examinations as applied in the present study, for merely scientific reasons might be considered as ethically unacceptable, as the main aim of our study was to differentiate mildly affected from severely affected infants. That aim, unlike the differentiation from the healthy state, requires only data of affected infants.

The CMAP area was most strongly associated with motor impairment and with the presence of muscle stretch reflexes, but less strongly with sensory impairment. This difference is plausible, as the CMAP above all represents motor function. However, the association with sensory impairment was more pronounced than the association between the CMAP area and the morphological level of the spinal anomaly. This is in accordance with the assumption that the

neurological impairment only partly relates to the morphological abnormalities in spina bifida [9].

In all analyses the gastrocnemius CMAP area seems much more specific for neurological impairment than the tibialis anterior CMAP area. This might be due to the smaller variability in the tibialis anterior CMAP area compared to the variability in the gastrocnemius CMAP area (Figure 2). Considering the spinal segmental organization and the distribution of impairment levels within our study group, the tibialis anterior muscle is usually less affected than the gastrocnemius muscle. Furthermore, the ability to recruit motor neurons from spinal segments cranial to the spinal anomaly applies more to the tibialis anterior muscle than to the gastrocnemius muscle.

Clear associations exist between the presence of muscle stretch reflexes and the CMAP area with differences between the two muscles (Figure 3). The neurosegmental association between the gastrocnemius muscle and the Achilles reflex, and the partial neurosegmental association between the tibialis anterior muscle and the patellar reflex may cause this difference. The difference in CMAP area between the two muscles when the Achilles reflex is present, can be explained by a difference in muscle volume. Furthermore, the association between the gastrocnemius CMAP area and the presence of the Achilles reflex suggests that non-excitability of a reflex results from an insufficient amount of functioning efferent motor neurons, rather than from an interrupted reflex arc. For infants in whom the Achilles reflex could not be elicited, a CMAP was still obtainable. This proves the integrity of efferent neurons. Evidence for the integrity of afferent neurons is provided by Sival et al. [8].

In spina bifida, both upper and lower motor neuron dysfunction might be present. To what extent the upper or the lower motor neuron determines the neurological impairment remains a matter of debate [8,14]. The CMAP area provides an estimate of the residual lower motor neuron function in affected spinal segments. The association between the CMAP area and motor impairment shows that this residual function decreases when more cranial spinal segments are involved in motor impairment. This suggests a cranio-caudal gradient (i.e. a cranio-caudal decrease) in lower motor neuron function in the affected spinal segments. This gradient might be related to the degree of upper motor neuron function. In normal neurodevelopment, the upper motor neuron is involved in the activity dependent regulation of the development of the lower motor neuron, as described by Eyre et al. [24]. In spina bifida, the upper motor neuron must pass through disordered spinal segments to synapse to the lower motor neuron in affected spinal segments. In longer tracts, the integrity of the upper motor neuron is more vulnerable than in shorter tracts. This might result in a more definite underdevelopment of lower motor neurons in affected caudal segments than in affected cranial segments.

The results on motor impairment as a dichotomous variable show that a large CMAP area is related to normal lower limb movements and a small CMAP area to paralysis, considering our method to assess motor impairment (Figure 5). The presence of normal movements denotes that the upper motor neuron integrity is at least partially preserved. This implies that the CMAP area also provides indirect information about the degree of upper motor neuron function in spina bifida.

The above-mentioned considerations imply that the demarcation of motor impairment to spinal segments is a simplification of the actual impairment, because residual motor function is present in affected spinal segments caudally from this demarcation. This residual function might explain the disagreement between patterns of muscle activity and neurosegmental innervation, as described by McDonald et al. [6]. Evaluation of the residual motor function by assessment of the CMAP area may provide a more precise estimate of motor impairment. Since the method as used is easy to perform and well tolerated, we recommend CMAP assessment as an additional instrument in the preoperative neonatal assessment of spina bifida. For clinical use, we suggest that the assessment of only the gastrocnemius muscle would be sufficient, since this muscle is most sensitive. To what extent this method has predictive value for neurological impairment and disability in later life requires further follow-up study. The present results support the hypothesis that the CMAP area may be indicative of neurological impairment at a later age as well and that a larger CMAP area may predict a better functional outcome.

Acknowledgements

The authors thank Y.M. van den Bogaard-Visco, Electroneurodiagnostic Technologist, for her efforts and technical support in the measurements, and R. Ripley, PhD, for his native linguistic corrections.

References

1. Hunt GM. Open spina bifida: outcome for a complete cohort treated unselectively and followed into adulthood. *Dev Med Child Neurol* 1990; 32:108-118.
2. Appleton PL, Minchom PE, Ellis NC, Elliott CE, Boll V, Jones P. The self-concept of young people with spina bifida: a population-based study. *Dev Med Child Neurol* 1994; 36:198-215.
3. Bowman RM, McLone DG, Grant JA, Tomita T, Ito JA. Spina bifida outcome: a 25-year prospective. *Pediatr Neurosurg* 2001; 34:114-120.
4. Verhoef M, Barf HA, Post MW, van Asbeck FW, Gooskens RH, Prevo AJ. Secondary impairments in young adults with spina bifida. *Dev Med Child Neurol* 2004; 46:420-427.
5. Hunt GM, Poulton A. Open spina bifida: a complete cohort reviewed 25 years after closure. *Dev Med Child Neurol* 1995; 37:19-29.
6. McDonald CM, Jaffe KM, Shurtleff DB, Menelaus MB. Modifications to the traditional description of neurosegmental innervation in myelomeningocele. *Dev Med Child Neurol* 1991; 33:473-481.
7. Stark GD. Neonatal assessment of the child with a myelomeningocele. *Arch Dis Child* 1971; 46:539-548.
8. Sival DA, van Weerden TW, Vles JS, et al. Neonatal loss of motor function in human spina bifida aperta. *Pediatrics* 2004; 114:427-434.
9. Rintoul NE, Sutton LN, Hubbard AM, et al. A new look at myelomeningoceles: functional level, vertebral level, shunting, and the implications for fetal intervention. *Pediatrics* 2002; 109:409-413.
10. Miller RG, Kuntz NL. Nerve conduction studies in infants and children. *J Child Neurol* 1986; 1:19-26.
11. Geerdink N, Pasman JW, Roeleveld N, Rotteveel JJ, Mullaart RA. Responses to lumbar magnetic stimulation in newborns with spina bifida. *Pediatr Neurol* 2006; 34:101-105.
12. Tortori-Donati P, Rossi A, Cama A. Spinal dysraphism: a review of neuroradiological features with embryological correlations and proposal for a new classification. *Neuroradiology* 2000; 42:471-491.
13. Sharrard WJ. The segmental innervation of the lower limb muscles in man. *Ann R Coll Surg Engl* 1964; 35:106-122.
14. Stark GD, Drummond M. Neonatal electromyography and nerve conduction studies in myelomeningocele. *Neuropädiatrie* 1972; 3:409-420.
15. Sugar M, Kennedy C. The use of electrodiagnostic techniques in the evaluation of the neurological deficit in infants with myelomeningocele. *Neurology* 1965; 15:787-793.
16. Mortier W, von Bernuth H. The neural influence on muscle development in myelomeningocele: histochemical and electrodiagnostic studies. *Dev Med Child Neurol* 1971; 13(Suppl.25):82-89.
17. Stark GD, Drummond M. The spinal cord lesion in myelomeningocele. *Dev Med Child Neurol* 1971; 13(Suppl.25):1-14
18. Stoyle TF. Prognosis for paralysis in myelomeningocele. *Dev Med Child Neurol* 1966; 8:755-760.
19. Duckworth T, Brown BH. Changes in muscle activity following early closure in myelomeningocele. *Dev Med Child Neurol* 1970; 12(Suppl.22):39-45.
20. Daude JR. Nerve conduction studies. In: Aminoff MJ, ed. *Electrodiagnosis in clinical neurology.* 4th ed. Philadelphia: Churchill Livingstone, 1999: 253-289.
21. Schulte-Mattler WJ, Jakob M, Zierz S. Assessment of temporal dispersion in motor nerves with normal conduction velocity. *Clin Neurophysiol* 1999; 110:740-747.
22. Johnsen B, Fuglsang-Frederiksen A, de Carvalho M, Labarre-Vila A, Nix W, Schofield I. Amplitude, area and duration of the compound muscle action potential change in different ways over the length of the ulnar nerve. *Clin Neurophysiol* 2006; 117:2085-2092.
23. Bartonek A, Saraste H, Knutson LM. Comparison of different systems to classify the neurological level of lesion in patients with myelomeningocele. *Dev Med Child Neurol* 1999; 41:796-805.
24. Eyre JA, Miller S, Clowry GJ, Conway EA, Watts C. Functional corticospinal projections are established prenatally in the human foetus permitting involvement in the development of spinal motor centres. Brain 2000; 123(Pt.1):51-64.

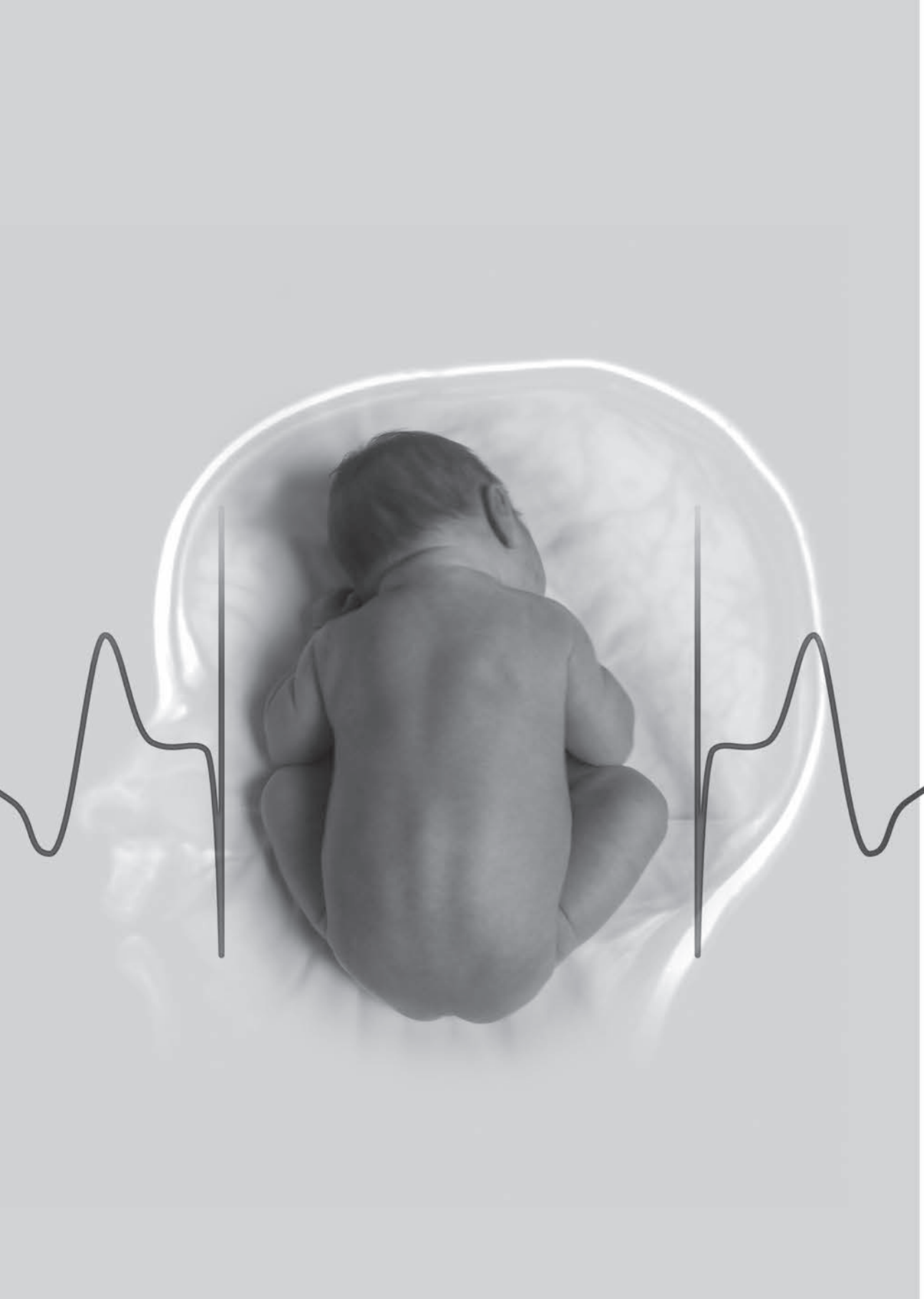

4

Motor evoked potentials in relation to clinical impairment in neonatal spina bifida

Niels Geerdink
Inge Cuppen
Jan J. Rotteveel
Reinier A. Mullaart
Nel Roeleveld
Jaco W. Pasman

Submitted

Abstract

The aim of this study was to investigate the relationship between motor evoked potentials (MEPs) after lumbar magnetic stimulation and neurological impairment in newborn infants with spina bifida. Thirty-six affected newborn infants were investigated at a median age of 2 days (range 0-18 days). Motor and sensory impairment and muscle stretch reflexes were assessed and neuroimaging was performed. MEPs were recorded from the quadriceps, the tibialis anterior, and the gastrocnemius muscle after lumbar magnetic stimulation; from the biceps brachii muscle after cervical magnetic stimulation; and from all four muscles after transcranial magnetic stimulation. Lumbar and cervical magnetic stimulation resulted in MEPs in almost all infants, but transcranial magnetic stimulation resulted in MEPs in only a few infants. The areas under the curve of the MEPs in the lower limb muscles were associated with the presence of muscle stretch reflexes and with motor and sensory impairment. These associations were strongest for the gastrocnemius muscle. Although lumbar magnetic stimulation has its limitations, MEPs measure neurological impairment. These MEPs can not substitute the clinical neurological examination, but they may provide additional quantitative information about neurological impairment. Assessment of the gastrocnemius and quadriceps femoris MEP is suggested.

Introduction

Spina bifida is a congenital malformation of the nervous system which usually results in severe disabilities [1-3]. These disabilities mainly depend on neonatal neurological impairment, especially sensory impairment [4]. Traditionally, neurological impairment is assessed by physical examination, but the neurological examination of a newborn infant may be complex and, to a certain extent, subjective. Potentially confounding factors are inconsistencies between muscle activity and the neurosegmental innervation [5], the distinction between normal and purely reflex movements [6], and changing movement patterns in the first week of life [7]. In the past few years, neuroimaging is performed in most centers as well, but the morphological level of the spinal anomaly is only partly related to neurological impairment [1,7,8]. An instrument that provides additional information about neurological impairment is desirable and may improve preoperative clinical decision-making in newborn infants with spina bifida.

Motor evoked potentials (MEPs) after lumbar magnetic stimulation may provide this additional information. Magnetic stimulation is a non-invasive method to evaluate motor pathways, which has diagnostic value in several disorders [9-11]. Previously, we described the feasibility of lumbar magnetic stimulation in newborn infants with spina bifida [12]. Studying compound muscle action potentials (CMAPs) after percutaneous electrical nerve stimulation, we found that the magnitude of the CMAP is related to neurological impairment in neonatal spina bifida [13]. In addition, lumbar magnetic stimulation may provide a method to investigate muscles that are difficult to access by percutaneous electrical nerve stimulation.

The aim of the present study was to investigate the relationship between the magnitude of the MEP, as represented by the area under the curve (MEP area), and neurological impairment in newborn infants with spina bifida in light of a potential diagnostic value. We hypothesized that a larger MEP is associated with less neurological impairment.

Methods

Subjects

Thirty-six newborn infants (22 boys, 14 girls) with spina bifida, born at or referred to the Radboud University Nijmegen Medical Centre were enrolled in the study. Fifteen of these infants were diagnosed antenatally. Most infants were born at term (mean gestational age 39 weeks; SD 1.6 weeks) and had a birth weight appropriate for gestational age (mean birth weight 3279 grams; SD 528

grams). The Regional Committee on Research Involving Human Subjects approved the study protocol. Informed consent was obtained from all parents.

Clinical assessment

The clinical assessment was performed before surgical closure of the spinal anomaly and was based on repeated physical examinations and a brain and spinal cord MR imaging within 72 hours after birth. Motor impairment was assessed on each side separately and scored according to the lowest spinal segment with lasting non-stereotypical, non-reflex lower limb movements. Where motor impairment was thoracic, we did not attempt to assign it to a single segment, because we considered this as too inaccurate. Sensory impairment was also assessed on each side separately and scored according to the lowest dermatome with a behavioral reaction on pin prick. Muscle stretch reflexes were scored as present or absent. On MR images, the spinal anomaly was classified according to Tortori- Donati [14] and its morphological level and size were described by identifying the cranial and caudal margin of the spinal anomaly with the corresponding vertebra. Cerebral comorbidity was assessed by the presence or absence of hydrocephalus, Chiari II malformation, and corpus callosum dysgenesis.

Neurophysiological assessment

The neurophysiological assessment took place at the median age of 2 days (range 0-18 days) and before surgical closure of the spinal anomaly. In all infants, the same assessor performed the procedure using a Magstim 200 magnetic stimulator and a 90 mm circular coil (outer diameter 130 mm, inner diameter 50 mm). The infants were investigated lying in prone position in an incubator and magnetic stimulation was performed through an access on the right side of the incubator. Lumbar and cervical magnetic stimulation (100%) was performed with the coil positioned over the lumbar and cervical spine, respectively. Transcranial magnetic stimulation (100%) was performed with the coil positioned tangentially over the vertex. MEPs were recorded during complete relaxation of the muscles using surface electrodes (tendon-belly montage) and an Oxford Synergy electromyograph (Oxford Instruments, Old Woking Surrey, UK; band-pass filter 20 Hz and 3 kHz, amplifier range 100 mV, and display sensitivity of 0.5 mV/division). MEPs were recorded bilaterally from the quadriceps femoris, the tibialis anterior, and the gastrocnemius muscle after lumbar magnetic stimulation; from the biceps brachii muscle after cervical magnetic stimulation; and from all four muscles after transcranial magnetic stimulation. The muscles were assessed one by one and per muscle, magnetic stimulation was repeated several times with slight variation in coil position (including alternation of clockwise and counter-clockwise current flow in the coil) in search of the best reproducible MEP. The

MEP with the highest amplitude was used for further analysis. Since lower limb muscles generally do not respond to transcranial magnetic stimulation before the age of four [15,16], this stimulation was performed just two or three times. The latency of the MEP was measured from the stimulus artifact to the onset of the first negative deflection of the MEP. The area under curve of the first negative wave was calculated as a measure of the magnitude of the MEP. Measurements of the gastrocnemius muscle were obtained in only 23 infants as this muscle was added to the protocol later during the investigation.

Analysis

As the gastrocnemius muscle was added to the protocol later, our study population comprised two subgroups. Possible confounding differences in clinical impairment and MEP measurements between these subgroups were analyzed using the Mann-Whitney U test or the Fisher exact test. To allow statistical tests, the scores for motor impairment, sensory impairment, and morphological level were converted to a numeric scale: 1 (Th1), 2 (Th2), 3 (Th3) etcetera, until 22 (S5). The mean values, standard deviations, and ranges of the MEP measurements were computed to show similarities and differences between the assessed muscles. The associations between MEPs and muscle stretch reflexes were summarized in box plots. Associations between MEPs and impairment measures were further analyzed with the Spearman rank correlation coefficient and in case of dichotomous variables with the Mann-Whitney U test. In addition, the MEP area data were logistically transformed to generate approximately normal distributions. Multivariable linear regression analyses were then performed for motor and sensory impairment with the MEP area variables as predictors. Statistical analyses were performed using SPSS version 14.0.1.

Results

Clinical impairment

The clinical impairment measurements are summarized in Table 1. Of the 36 newborn infants included in the study, motor impairment was thoracic in 12 infants, lumbar in 16, and sacral in eight. In five infants, motor impairment was asymmetric. Sensory impairment was thoracic in seven infants, lumbar in 18, and sacral in 11. In seven infants, sensory impairment was asymmetric. The patellar reflexes were present in 17 infants and the Achilles reflexes in eight of these infants, whereas in one infant the Achilles reflexes were present and the patellar reflexes were absent. In the remaining 18 infants both reflexes were absent. Most spinal anomalies were classified as myelomeningocele (n = 27), and

Table 1 Clinical impairment measurements in 36 newborn infants with spina bifida

	Number
Level of motor impairment	
Thoracic[a]	12
Lumbar[b]	16
Sacral	8
Level of sensory impairment	
Thoracic[c]	7
Lumbar[d]	18
Sacral	11
Muscle stretch reflexes	
Patellar and Achilles reflex, both absent	18
Patellar reflex present, Achilles reflex absent[e]	10/9
Achilles reflex present[e]	8/9
Type of spinal anomaly on MRI	
Myelomeningocele	27
Myelocele	5
Lipomyelemeningocele	1
Meningocele	1
Other type of closed spina bifida	2
Cranial margin of spinal anomaly on MRI	
Thoracic	7
Lumbar	27
Sacral	2
Size of spinal anomaly on MRI	
≥10 vertebrae	4
7-9 vertebrae	10
5-6 vertebrae	18
< 5 vertebrae	4
Cerebral comorbidity on MRI	
Hydrocephalus	31
Chiari II malformation	32
Corpus callosum dysgenesis	28

[a] Two asymmetric (L1-Th12; Th12-L2)
[b] Three asymmetric (L1-L2; L5-S1; S1-L5)
[c] Two asymmetric (Th10-L2; Th12-L1)
[d] Five asymmetric (L2-L3 [2]; L4-L5; L5-S2; L5-L3)
[e] One asymmetric
L, lumbar; Th, thoracic

five anomalies were classified as myelocele. The other four anomalies were other types of spina bifida (Table 1). The morphological level of the spinal anomaly was thoracic in seven, lumbar in 27, and sacral in two infants. Most spinal anomalies covered five or more vertebrae. All infants with myelomeningocele or myelocele had a Chiari II malformation. Of these infants, 31 had hydrocephalus and 28 had corpus callosum dysgenesis.

Regarding the clinical impairment measurements, no differences were present between the subgroup in which only the tibialis anterior and the quadriceps femoris muscle were investigated (n = 13) and the subgroup in which all three lower limb muscles were investigated (n = 23).

Motor evoked potentials

Lumbar magnetic stimulation resulted in MEPs in the lower limb muscles in almost all infants (see Figure 1 for examples). In 27 of the 36 infants, all investigated lower limb muscles responded to lumbar magnetic stimulation. In eight infants, one or more muscles did not respond. In only one infant, no MEPs were obtained in any of the investigated lower limb muscles. Cervical stimulation resulted in

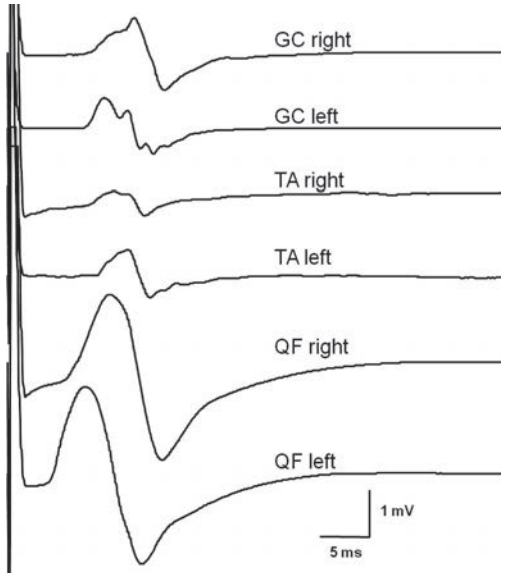

Figure 1 Motor evoked potentials recorded in lower limb muscles after lumbar magnetic stimulation. GC, gastrocnemius muscle; TA, tibialis anterior muscle; QF, quadriceps femoris muscle

MEPs in the biceps brachii muscle in 31 of the 36 infants. In two infants cervical stimulation did not result in a MEP and in three infants cervical stimulation was technically impossible due to anatomical impediments (e.g. extreme macrocephaly). Transcranial magnetic stimulation rarely resulted in reliable MEPs (in two infants, the quadriceps femoris muscle responded and in one infant, the biceps brachii muscle responded).

The mean values, standard deviations, and ranges of latency and area under the curve of the obtained MEPs are presented in Table 2. The quadriceps femoris muscle differed from other muscles: shorter latency and larger area, but only the shorter latency was statistically significant.

Regarding the MEP results, no differences were present between the subgroup in which only the tibialis anterior and quadriceps femoris muscle were investigated (n = 13) and the subgroup in which all three lower limb muscles were investigated (n = 23).

Table 2 Mean values, standard deviations and ranges for latency and area under the curve of motor evoked potentials after lumbar magnetic stimulation

Muscle	Latency (ms)			MEP area (mVms)			n
	Mean	SD	Range	Mean	SD	Range	
GC right	8.8	1.7	6.3-12.4	3.8	5.2	0.1-20.7	19
GC left	9.4	1.6	7.1-12.5	3.0	4.7	0.1-20.9	19
TA right	8.6	1.4	5.6-11.4	3.2	4.8	0.1-19.7	29
TA left	8.6	1.4	4.9-11.4	2.7	3.9	0.1-19.9	31
QF right	5.1	1.3	2.8-8.2	3.7	4.1	0.1-16.6	32
QF left	5.1	1.6	3.4-10.7	4.5	5.5	0.1-19.8	32
BB right	7.5	3.1	3.6-16.5	3.2	3.8	0.1-14.2	30
BB left	7.5	2.9	3.1-15.1	3.7	5.0	0.1-20.9	31

GC, gastrocnemius muscle; TA, tibialis anterior muscle; QF, quadriceps femoris muscle; BB, biceps brachii muscle

Associations between MEP and clinical impairment

In the lower limb muscles, the MEP area was associated with the presence of muscle stretch reflexes and with motor and sensory impairment (i.e. the less the impairment, the larger the MEP area). No associations were found between the

MEP area and morphological characteristics of the spinal anomaly, between the MEP area and cerebral comorbidity, or between the MEP latency and any of the clinical impairment measures. In the biceps brachii muscle, we did not find any association between the MEP parameters and clinical impairment measures.

The associations between the MEP area and the muscle stretch reflexes are presented in Figure 2. The three boxes on the left show that the MEP area was negligible in all lower limb muscles, when both the patellar and the Achilles reflex were absent. Substantial MEP areas were measurable in the quadriceps femoris muscle, but not in the other muscles, when only the patellar reflex was present. When the Achilles reflex was present, substantial MEP areas were obtained in all muscles, in particular in the tibialis anterior and the gastrocnemius muscle.

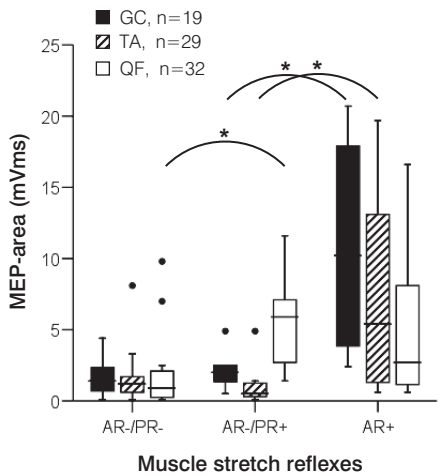

Figure 2 Associations between MEP area and muscle stretch reflexes. The horizontal bar and the upper and lower border of each box mark median, 25th, and 75th percentiles, respectively. Error bars mark 5th and 95th percentiles. Points lie beyond 5th and 95th percentiles. As the results for both sides were almost identical, only data for the right side are presented. MEP, motor evoked potential; MEP area, area under the curve of first negative wave of the MEP; GC, gastrocnemius muscle; TA, tibialis anterior muscle; QF, quadriceps femoris muscle; AR, achilles tendon reflex; PR, patellar tendon reflex; +, reflex present; −, reflex absent; * $p<0.05$ based on Mann-Whitney U test.

The associations between the MEP area and motor and sensory impairment are illustrated in Figure 3. Correlation coefficients for these associations are specified in Table 3. The associations with sensory impairment demonstrated a cranio-caudal gradient (i.e. the more cranial the neurosegmental innervation of the muscle the weaker the association), with statistically significant correlation coefficients for the gastrocnemius and the tibialis anterior muscle only. Surprisingly, the associations with motor impairment were stronger at the right side than at the left side. No meaningful associations were found between the MEP area and the morphological level of the spinal anomaly.

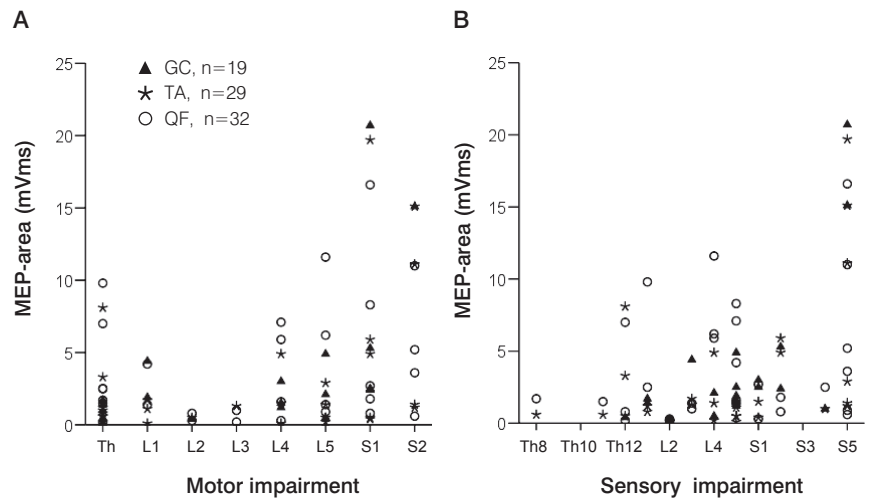

Figure 3 Associations between MEP area and motor impairment (**A**) and sensory impairment (**B**). As the results for both sides were almost identical, only data for the right side are presented. MEP, motor evoked potential; MEP area, area under the curve of first negative wave of the MEP; GC, gastrocnemius muscle; TA, tibialis anterior muscle; QF, quadriceps femoris muscle; L, lumbar; Th, thoracic

The multivariable linear regression analyses showed that a model including the MEP areas of all lower limb muscles had a predictive value of up to 46 % for sensory impairment and up to 34 % for motor impairment. Again, remarkable discrepancies between the left and right side were noticed, with the left side MEPs not being predictive for motor impairment. In all analyses, the gastrocnemius MEP area determined the majority of the predictive value for motor and sensory impairment (Table 4).

Table 3 Correlations (Spearman rank correlation coefficients) between MEP area and motor impairment, sensory impairment, and morphological level of spinal anomaly

MEP area	Motor impairment		Sensory impairment		Level of spinal anomaly		n
	Right	Left	Right	Left	Right	Left	
Gastrocnemius	0.66***	0.38	0.60***	0.56**	-0.18	-0.30	19
Tibialis anterior	0.31	0.26	0.39**	0.35*	-0.01	0.00	29/31[a]
Quadriceps femoris	0.31*	0.22	0.26	0.20	-0.03	-0.05	32
Biceps brachii	-0.05	0.04	-0.22	-0.05	-0.17	-0.04	30/31[b]

* p<0.10; ** p<0.05; *** p<0.01.
[a] n = 29 on the right side and n = 31 on the left side
[b] n = 30 on the right side and n = 31 on the left side

Table 4 Results of multivariable linear regression for MEP area[a] predicting motor and sensory impairment (n=18)

Step	Predictor MEP area	Right		Left	
		R^2	P-value	R^2	P-value
Motor impairment					
1	GC	0.33	0.01	0.08	0.25
2	GC-TA	0.34	0.04	0.08	0.52
3	GC-TA-QF	0.34	0.11	0.10	0.69
Sensory impairment					
1	GC	0.43	<0.01	0.28	0.03
2	GC-TA	0.46	0.01	0.29	0.08
3	GC-TA-QF	0.46	0.03	0.30	0.17

[a] MEP area data were logistically transformed
GC, gastrocnemius muscle; TA, tibialis anterior muscle; QF, quadriceps femoris muscle; R^2, coefficient of determination

Discussion

The present study shows associations between MEPs after lumbar magnetic stimulation and neurological impairment in newborn infants with spina bifida. The magnitude of the MEP in the lower limb muscles, represented by the area under the curve of the first negative wave, relates to the presence of muscle stretch reflexes and to motor and sensory impairment. As far as we know, similar results on lumbar magnetic stimulation have not been reported before. However, these findings are compatible with the associations we found between the CMAP after percutaneous electrical nerve stimulation and neurological impairment in newborn infants with spina bifida [13]. Other authors also reported motor responses to be present in lower limb muscles in almost all infants with spina bifida, although using other methods of stimulation, such as percutaneous electrical nerve stimulation [17-19], electrical neural plaque stimulation [17,20], and faradic muscle stimulation [21,22]. In these studies, only the presence or absence of a response was evaluated in relation to clinical impairment. However, the presence or absence of a response cannot be a diagnostic criterion, when responses are present in virtually every infant. In contrast, the associations between the MEP area and neurological impairment in our study show that the MEP area is distinctive and that MEPs may provide additional information about neurological impairment.

As opposed to lumbar magnetic stimulation, transcranial magnetic stimulation did hardly result in any MEPs. This is in accordance with other studies. In healthy infants, the lower limb muscles generally do not respond to transcranial magnetic stimulation before the age of four [15,16]. Consequently, direct assessment of the corticospinal tract is not possible using this method in newborn infants. The almost complete absence of responses after transcranial magnetic stimulation on the other hand, implies that the responses after lumbar magnetic stimulation are indeed MEPs and not startle responses provoked by the acoustic click that accompanies magnetic stimulation.

The MEP latency did not relate to neurological impairment. The spread of the MEP latency in the lower limb muscles was small, as can be seen from the low SDs in Table 2. Moreover, the MEP latency in the quadriceps femoris muscle was shorter than the MEP latency in the other muscles, which is in accordance with the difference in distances from point of excitation to the site of recording between the investigated muscles. Therefore, the MEP latency might be considered as relatively unaffected.

Before further interpreting the results on the MEP area, some methodological remarks have to be made. First, lumbar magnetic stimulation is complicated by spatial dispersion [23] and by temporal dispersion which results from abnormal

myelination in pathological neurons [24]. To deal with this, we used the area under the curve instead of the amplitude to quantify the magnitude of the MEP. The MEP area is less liable to dispersion than the amplitude [24,25]. Second, the magnitude of the MEP is proportional to the number and size of activated motor units [26], but it may vary between and within individuals [27,28]. Lumbar magnetic stimulation does not result in the activation of all motor units present [27,29] and the magnitude of the MEP depends on the stimulus site and the thickness of the intervening tissue between the coil and the motor neurons [28,30]. Third, we used surface electrodes instead of needle electrodes to record the MEPs, because surface electrodes provide a better representation of the amount of activated motor units than needle electrodes. Furthermore, surface electrodes are more convenient and non-invasive. However, recordings with surface electrodes are prone to crosstalk, i.e. activity generated in muscles adjacent to the muscle of interest, which can, through volume spread, contaminate the MEP recording [31]. In the current study, some crosstalk was hardly preventable, because of relatively large electrodes compared to small body proportions.

Despite the limitations mentioned, we found clear associations between the magnitude of the MEP and neurological impairment. The results concerning the muscle stretch reflexes can easily be explained, since two of the muscles studied (gastrocnemius and quadriceps femoris) are the agonistic muscles of the reflexes. The MEP areas in these muscles were larger and extended over a broader range of values, when the reflexes were present (Figure 2). This suggests that the MEP area might provide quantitative information about the reflexes.

The results on sensory impairment reflect the neurosegmental innervation of the muscles studied: the more cranial the neurosegmental innervation of the muscle, the weaker the association with sensory impairment. These results are compatible with results on CMAPs after percutaneous electrical nerve stimulation [13].

In contrast, the association between the MEP area and motor impairment was less definite. This may be explained in several ways. First, the weak association on the left side might be a consequence of the assessment position during examination. We investigated all infants in an incubator and performed magnetic stimulation through an access on the right side. Complicated accessibility might have hampered optimal stimulation on the left side. Second, considering the neonatal neurological examination, the reliability of muscle stretch reflexes and sensory impairment scores might be better than the reliability of motor impairment scores. To ascertain the presence of a reflex or a behavioral reaction to pin-prick is more straightforward, than ascertaining motor impairment based on observed spontaneous lower limb movements and distinguishing normal movements from reflex movements. If the MEP area

provides valid information, it is expected to relate better to a reliable instrument than to a less reliable instrument. Third, lumbar magnetic stimulation primarily activates large diameter motor neurons [23,32] and consequently, the amount of small diameter motor neurons is not completely reflected in the MEP. The small motor neurons are likely to be more essential in normal lower limb movements than in the excitability of muscle stretch reflexes, further explaining the differences between motor impairment and muscle stretch reflexes.

In all analyses, the gastrocnemius muscle was most indicative of neurological impairment. Differences in neurosegmental innervation between the muscles studied might explain this. Since the gastrocnemius has the most caudal neurosegmental innervations, the gastrocnemius muscle was more often affected than the other two muscles. Moreover, the ability to recruit motor neurons from spinal segments cranial to the spinal anomaly should apply more to the quadriceps femoris and the tibialis anterior muscle than to the gastrocnemius muscle. The quadriceps femoris muscle may have also more potential to compensate for affected segments, because this muscle is multi-segmentally innervated whereas the other muscles are bi-segmentally innervated. In our results, the differences between the gastrocnemius and the quadriceps femoris muscle (cranial versus caudal innervation) were more pronounced than the differences between the tibialis anterior and the quadriceps femoris muscle (multi- versus bi-segmental innervation). Therefore, the first explanation seems to be most relevant.

The clinical determination of neurological impairment in newborn infants with spina bifida is complex. The demarcation of impairment to spinal segments is a simplification of the actual impairment, because residual lower motor neuron function is present in affected spinal segments caudally from this demarcation. Lumbar magnetic stimulation might be a method to assess this residual function. Although this method has its limitations, the present study shows that MEPs after lumbar magnetic stimulation measure neurological impairment. These MEPs can not substitute the clinical neurological examination, but they may provide additional quantitative information about neurological impairment. Therefore, for the diagnostic workup of neonatal spina bifida, we suggest the assessment of gastrocnemius and quadriceps femoris MEPs after lumbar magnetic stimulation as an additional instrument to the clinical neurological examination. To what extent MEPs have a predictive value for neurological impairment at a later age requires further study. However, we hypothesize that neonatal MEPs might be indicative of neurological impairment at a later age.

Acknowledgements

The authors thank Y.M. van den Bogaard-Visco, M. Heykers, and J. Bor, Electrophysiological Technologists, for their efforts in the data acquisition and technical support in the measurements.

References

1. Hunt GM. Open spina bifida: outcome for a complete cohort treated unselectively and followed into adulthood. *Dev Med Child Neurol* 1990; 32:108-118.
2. Appleton PL, Minchom PE, Ellis NC, Elliott CE, Boll V, Jones P. The self-concept of young people with spina bifida: a population-based study. *Dev Med Child Neurol* 1994; 36:198-215.
3. Verhoef M, Barf HA, Post MW, van Asbeck FW, Gooskens RH, Prevo AJ. Secondary impairments in young adults with spina bifida. *Dev Med Child Neurol* 2004; 46:420-427.
4. Hunt GM, Poulton A. Open spina bifida: a complete cohort reviewed 25 years after closure. *Dev Med Child Neurol* 1995; 37:19-29.
5. McDonald CM, Jaffe KM, Shurtleff DB, Menelaus MB. Modifications to the traditional description of neurosegmental innervation in myelomeningocele. *Dev Med Child Neurol* 1991; 33:473-481.
6. Stark GD. Neonatal assessment of the child with a myelomeningocele. *Arch Dis Child* 1971; 46:539-548.
7. Sival DA, van Weerden TW, Vles JS, et al. Neonatal loss of motor function in human spina bifida aperta. *Pediatrics* 2004; 114:427-434.
8. Rintoul NE, Sutton LN, Hubbard AM, et al. A new look at myelomeningoceles: functional level, vertebral level, shunting, and the implications for fetal intervention. *Pediatrics* 2002; 109:409-413.
9. Rossini PM, Rossi S. Clinical applications of motor evoked potentials. *Electroencephalogr Clin Neurophysiol* 1998; 106:180-194.
10. Di Lazarro V, Oliviero A, Profice P, et al. The diagnostic value of motor evoked potentials. *Clin Neurophysiol* 1999; 110:1297-1307.
11. Garvey MA, Gilbert DL. Transcranial magnetic stimulation in children. *Eur J Paediatr Neurol* 2004; 8:7-19.
12. Geerdink N, Pasman JW, Roeleveld N, Rotteveel JJ, Mullaart RA. Responses to lumbar magnetic stimulation in newborns with spina bifida. *Pediatr Neurol* 2006; 34:101-105.
13. Geerdink N, Pasman JW, Rotteveel JJ, Roeleveld N, Mullaart RA. Compound muscle action potentials in newborn infants with spina bifida. *Dev Med Child Neurol* 2008; 50:706-711.
14. Tortori-Donati P, Rossi A, Cama A. Spinal dysraphism: a review of neuroradiological features with embryological correlations and proposal for a new classification. *Neuroradiology* 2000; 42:471-491.
15. Muller K, Homberg V, Lenard HG. Magnetic stimulation of motor cortex and nerve roots in children. Maturation of cortico-motoneuronal projections. *Electroencephalogr Clin Neurophysiol* 1991; 81:63-70.
16. Nezu A, Kimura S, Uehara S, Kobayashi T, Tanaka M, Saito K. Magnetic stimulation of motor cortex in children: maturity of corticospinal pathway and problem of clinical application. *Brain Dev* 1997; 19:176-180.
17. Stark GD, Drummond M. Neonatal electromyography and nerve conduction studies in myelomeningocele. *Neuropädiatrie* 1972; 3:409-420.
18. Sugar M, Kennedy C. The use of electrodiagnostic techniques in the evaluation of the neurological deficit in infants with myelomeningocele. *Neurology* 1965; 15:787-793.
19. Mortier W, von Bernuth H. The neural influence on muscle development in myelomeningocele: histochemical and electrodiagnostic studies. *Dev Med Child Neurol* 1971; 13(Suppl.25):82-89.
20. Stark GD, Drummond M. The Spinal Cord Lesion in Myelomeningocele. *Dev Med Child Neurol* 1971; 13(Suppl.25):1-14.
21. Stoyle TF. Prognosis for paralysis in myelomeningocele. *Dev Med Child Neurol* 1966; 8:755-760.
22. Duckworth T, Brown BH. Changes in muscle activity following early closure in myelomeningocele. *Dev Med Child Neurol* 1970; 12(Suppl.22):39-45.
23. Cros D, Day TJ, Shahani BT. Spatial dispersion of magnetic stimulation in peripheral nerves. *Muscle Nerve* 1990; 13:1076-1082.
24. Schulte-Mattler WJ, Jakob M, Zierz S. Assessment of temporal dispersion in motor nerves with normal conduction velocity. *Clin Neurophysiol* 1999; 110:740-747.
25. Johnsen B, Fuglsang-Frederiksen A, de Carvalho M, Labarre-Vila A, Nix W, Schofield I. Amplitude, area and duration of the compound muscle action potential change in different ways over the length of the ulnar nerve. *Clin Neurophysiol* 2006; 117:2085-2092.
26. Daube JR. Nerve Conduction Studies. In: Aminoff MJ, ed. *Electrodiagnosis in Clinical Neurology*. 4th ed. Philadelphia: Churchill Livingstone, 1999: 253-289.
27. Macdonell RA, Cros D, Shahani BT. Lumbosacral nerve root stimulation comparing electrical with surface magnetic coil techniques. *Muscle Nerve* 1992; 15:885-890.
28. Maegaki Y, Maeoka Y, Takeshita K. Magnetic stimulation of the lumbosacral vertebral column in children: normal values and possible sites of stimulation. *Electroencephalogr Clin Neurophysiol* 1997; 105:102-108.
29. Evans BA, Litchy WJ, Daube JR. The utility of magnetic stimulation for routine peripheral nerve conduction studies. *Muscle Nerve* 1988; 11:1074-1078.
30. Ugawa Y, Rothwell JC, Day BL, Thompson PD, Marsden CD. Magnetic stimulation over the spinal enlargements. *J Neurol Neurosurg Psychiatry* 1989; 52:1025-1032.
31. Koh TJ, Grabiner MD. Cross talk in surface electromyograms of human hamstring muscles. *J Orthop Res* 1992; 10:701-709.
32. Britton TC, Meyer BU, Herdmann J, Benecke R. Clinical use of the magnetic stimulator in the investigation of peripheral conduction time. *Muscle Nerve* 1990; 13:396-406.

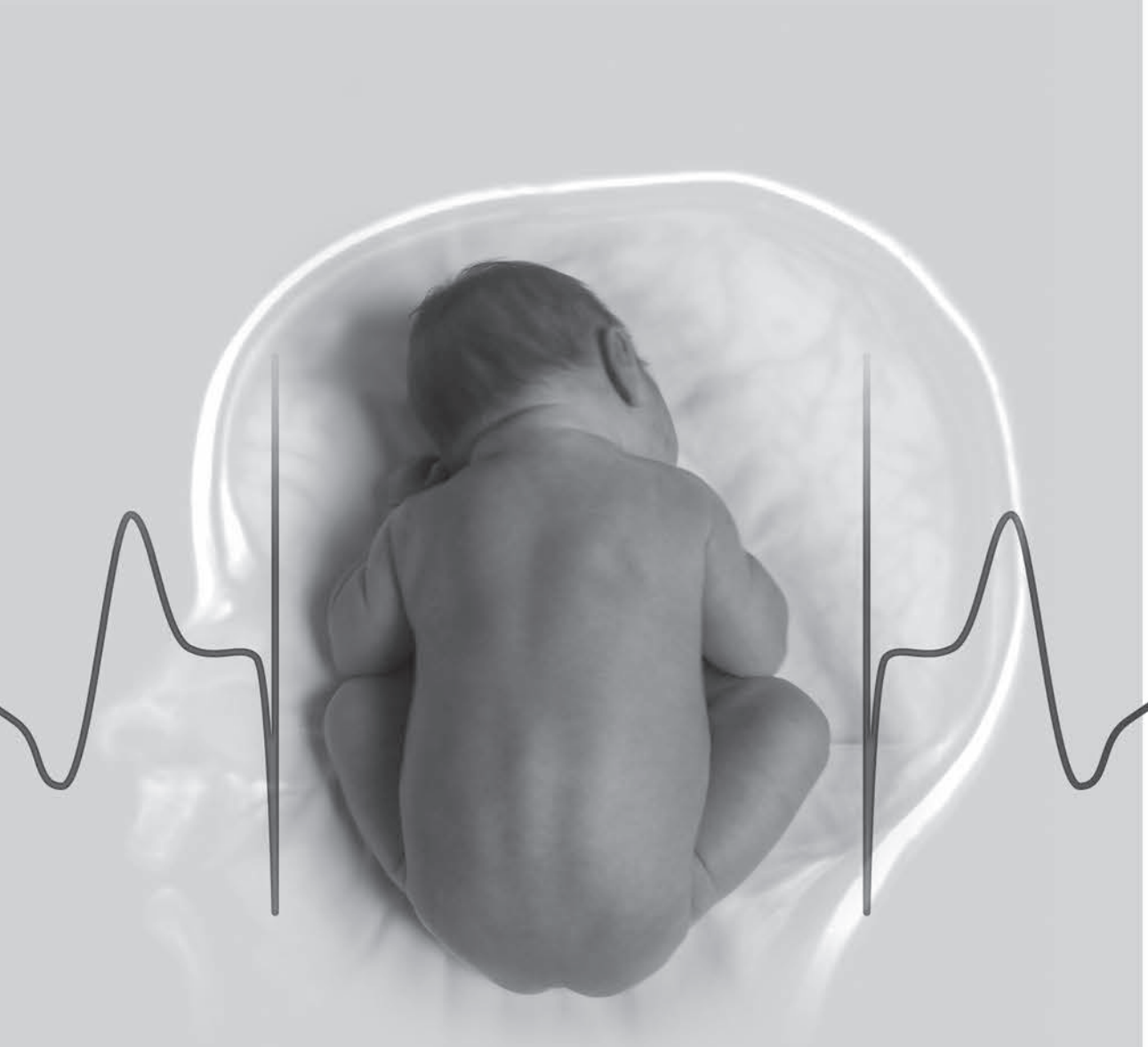

5

Motor evoked potentials and compound muscle action potentials as prognostic tools for neonates with spina bifida

Inge Cuppen*
Niels Geerdink*
Jan J. Rotteveel
Reinier A. Mullaart
Nel Roeleveld
Jaco W. Pasman

*Both authors qualify as first author

European Journal of Paediatric Neurology 2012;
http://dx.doi.org/10.1016/j.ejpn.2012.06.003

Abstract

Aim The aim of this prospective study was to determine the prognostic value of neurophysiological investigations compared to clinical neurological examination in infants with spina bifida.

Methods Thirty-six neonates born with spina bifida between 2002 and 2007 were evaluated and followed for two years. Lumbar motor evoked potentials (MEPs) and compound muscle action potentials (CMAPs) were obtained at the median age of two days before surgical closure of the spinal anomaly. MEPs were recorded from the quadriceps femoris, tibialis anterior, and gastrocnemius muscles and CMAPs from the latter two muscles. Areas under the curve and latencies of the MEPs and CMAPs were measured. Clinical neurological outcome at the age of 2 years was assessed using muscle function classes and ambulation status.

Results The areas under the curve of MEPs and CMAPs in the lower limbs were associated with neonatal levels of motor and sensory impairment. A better muscle function class at two years of age was associated with larger MEP and CMAP areas of the gastrocnemius and tibialis anterior muscles at neonatal age.

Discussion MEPs and CMAPs of the gastrocnemius and tibialis anterior muscles have some prognostic value for early neurodevelopmental outcome in neonates born with spina bifida.

Introduction

Spina bifida is a severe congenital malformation with a prevalence of 1-5 in 10.000 live births worldwide [1,2]. It is associated with complex physical and neuropsychological morbidity [3,4]. In this century, where choices have to be made regarding continuation or termination of treatment of neonates born with spina bifida, or regarding new treatment options such as prenatal surgery [5], it is important to have instruments to estimate the degree of neurological impairment [3,6]. Traditionally, neurological impairment has been assessed by physical examination after birth [7,8], but potentially confounding factors are inconsistencies between muscle activity and neurosegmental innervation [9-11], the distinction between normal and purely reflex movements [12,13], and changing movement patterns during the first weeks of life [11,14,15]. A variety of other methods, including prenatal ultrasounds [16], neuroimaging, and neurophysiological evaluation [15], have also been used in an attempt to predict the long-term neurodevelopmental outcome of neonates with spina bifida [17,18]. Instruments providing additional information about neurological impairment are desirable and may improve the preoperative clinical decision-making process in fetuses and newborn infants with spina bifida.

Modern neurophysiological methods, among others, by means of motor evoked potentials (MEPs) after magnetic stimulation, may provide this additional information. Magnetic stimulation is a non-invasive method to evaluate motor pathways, which has diagnostic value in several disorders [19]. Previously, the feasibility of spinal magnetic stimulation in newborn infants with spina bifida was reported [20], as well as the relation between compound muscle action potentials (CMAPs) and early neurological impairment in neonatal spina bifida [21].

The aim of the present study was to investigate the prognostic value of neonatal MEPs and CMAPs for neurological impairment in children with spina bifida at two years of age compared to the prognostic value of neonatal clinical neurological assessment.

Methods

Participants

Thirty-six newborn infants (22 boys, 14 girls) with spina bifida, recruited at the Radboud University Nijmegen Medical Centre during the period 2002-2007, were included in a prospective study. The study protocol was approved by the Regional Committee on Research Involving Human Subjects and written informed consent was obtained from the parents of all children. Inclusion criteria were

the presence of a congenital defect of one or more vertebral arches and a developmental anomaly of the spinal cord confirmed by magnetic resonance (MR) imaging, in combination with a median muscle-skin defect or a cystic or lipomatous mass on the back. The congenital anomaly was further specified according to the following two characteristics: (1) Type and size of spinal anomaly scored with diagnostic codes as closed or open. An open defect, such as a myelo-meningocele or meningocele, is characterized by exposure of neural tissue or meninges to the environment through a congenital defect of vertebral arches. A closed defect is covered with skin [22]. (2) Cerebral comorbidity scored as hydrocephalus, Chiari II malformation, or corpus callosum dysgenesis based on specific MR imaging features.

During the study all infants took part in the same rehabilitation program. They were seen in our 'spina bifida' follow up outpatient clinic every six months, comprising of a permanent multidisciplinary team of doctors, including a child rehabilitation specialist, pediatric physiotherapist, orthopedic surgeon, and pediatric neurologist. The advices of the team were incorporated in the regional rehabilitation programs.

Neurophysiological assessment

Neurophysiological assessment was performed at a median age of two days after birth (range 0-18 days) before surgical closure of the spinal anomaly. The infants were investigated lying in prone position in an incubator, while MEPs and CMAPs were recorded bilaterally from the tibialis anterior and gastrocnemius muscles, as well as MEPs from the quadriceps femoris muscle using surface electrodes (tendon-belly montage) and an Oxford Synergy electromyograph (Oxford Instruments, Old Woking Surrey, UK; band-pass filter 20 Hz and 3 kHz, amplifier range 100 mV, and display sensitivity of 0.5 mV/division). Spinal magnetic stimulation (100% stimulation intensity) was performed with the coil positioned over the lumbosacral spine and was repeated several times with slight variations in coil position (including alternation of clockwise and counter-clockwise current flow in the coil) in search of the best reproducible MEP. In all infants, the same assessor performed the procedure using a Magstim 200 magnetic stimulator and a 90mm circular coil (outer diameter 130mm, inner diameter 50mm). The MEP with the highest amplitude was used for further analyses. In addition, supramaximal percutaneous electrical stimulation of the peroneal and posterior tibial nerves was performed at the popliteal fossa to obtain CMAPs in the tibialis anterior and gastrocnemius muscles, respectively. The onset latencies from the stimulus artifact to the onset of the first negative deflection and the area under the curve of the first negative wave of the MEPs and CMAPs were measured. Because the area under the curve is less liable to dispersion than the amplitude

[23-25], the area was used as a measure of the magnitude of the MEPs and CMAPs (Figure 1). Measurements of the gastrocnemius muscle were obtained in only 23 infants, as this muscle was added to the protocol later during the investigation.

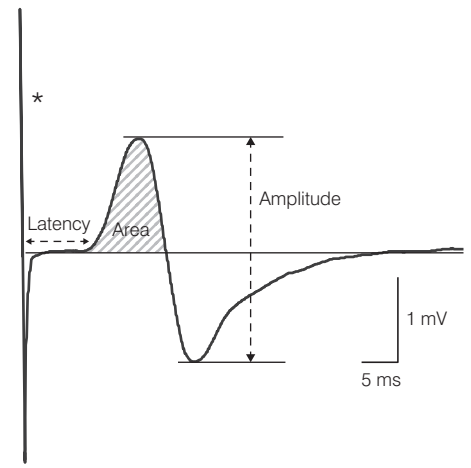

Figure 1 Measurements of motor evoked potentials and compound muscle action potentials. Asterisk indicates stimulus artifact.

Radiological assessment

MR imaging of the whole neural axis was performed in all infants before surgery using a 1.5 T MR imaging unit (Siemens Avanto; Siemens Medical Solutions, Erlangen, Germany) with a standard head coil. T1-weighted images in the sagittal plane and T2-weighted images in the axial and coronal plane were acquired. The spinal anomaly was classified as closed or open spinal dysraphism [22]. In addition, the presence of Chiari II malformation, hydrocephalus, and callosal dysgenesis was assessed. The anatomical level of the spinal anomaly was defined by identifying the cranial margin of the spinal anomaly with the corresponding vertebra on sagittal T1-weighted images.

Clinical assessment

Neonatal assessment

Clinical neonatal assessment was based on repeated physical examination within 72 hours after birth before surgical procedures were performed, as neurological impairment may be influenced by surgery [26,27]. All children were examined by the same two pediatric neurologists. Motor impairment was

assessed on each side separately and scored according to the lowest intact spinal segment with lasting non-stereotypical, non-reflex lower limb movements. Sensory impairment was also assessed on each side separately and scored according to the lowest intact dermatome, defined as the presence of behavioral reactions to pin prick or light touch in this dermatome.

Outcome assessment at the age of two years

Two outcome measures were assessed at two years of age. First, muscle function classes (MFCs) based on muscle strength in the lower limb muscles according to McDonald et al. [10] were used as a measure of impairment. Children were categorized into one of five MFCs. MFC 1 indicates good to normal intrinsic foot muscles and plantar flexion (MRC grade 4-5); MFC 2 indicates weakness of plantar flexion (MRC grade ≤ 3), good to normal knee flexion (MRC grade ≥ 3), and poor to fair or better hip extension and/or abduction activity (MRC grade ≥ 2); MFC 3 indicates good to normal hip flexion and knee extension (MRC grade 4-5), weakness of knee flexion (MRC grade ≤ 3), and traces of hip extension, hip abduction, and below-knee muscles; MFC 4 indicates weak or no knee extension with poor or less hip flexion (MRC grade ≤ 2) and good pelvic elevation activity; MFC 5 indicates no muscle activity in the lower limbs. As a second outcome measure, ambulation was assessed and classified into three categories: (a) community ambulation, when walking outdoors, (b) household ambulation, when only walking indoor, and (c) non-functional ambulation.

Statistical analysis

For the analyses, the motor and sensory impairment levels and the anatomical levels of the spinal anomalies were converted to a numeric index: 1 for Th1, 2 for Th2, etcetera, until 22 for S5. The MFC scores were dichotomized into two groups: MFC 1 and 2 as group 1 (mildly impaired subgroup) and MFC 3, 4 and 5 as group 2 (severely impaired subgroup), because of expected community ambulation for MFC 1 and 2 and only household or non-functional ambulation for the other MFCs. Because of possible differences between the left and right side of the body for MFC, analyses were performed for each side of the body separately. Ambulation was also dichotomized into community ambulation and non-community (household and non-functional) ambulation.

As measurements of the gastrocnemius muscle were added to the protocol later, our study population comprised two subgroups, with and without measurements of the gastrocnemius muscle. Possible differences in clinical impairment and MEP and CMAP measurements between these subgroups were analyzed using the Fisher exact test or Mann-Whitney U test, because of non-normal distributions.

For the MEP and CMAP measurements, median values and ranges were computed. Associations of MEPs and CMAPs with neonatal clinical neurological impairment measures were analyzed with Spearman rank correlation coefficients, and associations of MEPs and CMAPs with MFCs and ambulation status at two years of age were analyzed with the Mann-Whitney U test. Statistical analyses were performed using SPSS version 17.0.1. A P-value of less than 0.05 was considered statistically significant.

Results

Patients

Infant characteristics (n=36) are presented in Table 1. Fifteen infants were diagnosed antenatally. Most infants were born at term (median gestational age 39 weeks; range 35-42 weeks) and had a birth weight and head circumference appropriate

Table 1 Patients characteristics

	n
Type of spina bifida	
Open spinal dysraphism	33
Closed spinal dysraphism	3
Cerebral comorbidity	
Hydrocephalus	30
Chiari II malformation	31
Corpus callosum dysgenesis	28
Anatomical level of spinal anomaly	
Thoracic	7
Lumbar	27
Sacral	2
Level of motor impairment	
Thoracic	12
Lumbar	16
Sacral	8
Level of sensory impairment	
Thoracic	7
Lumbar	18
Sacral	11

n, number of patients

for gestational age (median birth weight 3245 grams, range 2305-4100 grams; median head circumference 35 cm, range 30-46 cm). Most spinal anomalies were classified as open spinal dysraphism (n=33). Thirty-one infants (86%) had Chiari II malformation, 30 infants (83%) had hydrocephalus, and 28 infants (78%) had corpus callosum dysgenesis.

Neurophysiological assessment

Motor evoked potentials

Spinal magnetic stimulation resulted in MEPs in almost all infants. In 27 of the 36 infants (75%), all investigated lower limb muscles responded to lumbar magnetic stimulation. In eight infants (22%), one or more muscles did not respond. In only one infant, no MEPs were obtained in any of the investigated lower limb muscles. The median values and ranges of the latency and the area under the curve of the MEPs obtained are presented in Table 2. The quadriceps femoris muscle differed from the other muscles: shorter latencies and mostly larger MEP areas were seen, but only the shorter latencies were statistically significantly different.

Table 2 Motor evoked potentials after lumbar magnetic stimulation

Muscle	Latency (ms)		MEP area (mVms)		n
	Median	Range	Median	Range	
QF right	5.0	2.8-8.2	1.8	0.1-16.6	32
QF left	4.9	3.4-10.7	2.3	0.1-19.8	32
TA right	8.2	5.6-11.4	1.2	0.1-19.7	29
TA left	8.6	4.9-11.4	1.3	0.1-19.9	31
GC right	8.3	6.3-12.4	2.1	0.1-20.7	19
GC left	9.2	7.1-12.5	1.6	0.1-20.9	19

QF, quadriceps femoris muscle; TA, tibialis anterior muscle; GC, gastrocnemius muscle; n, number of patients

Compound muscle action potentials

The muscles responded to percutaneous electrical nerve stimulation in almost all infants: the tibialis anterior muscle in 31 of the 36 infants (86%) and the gastrocnemius muscle in 20 of the 23 infants (87%). If the gastrocnemius muscle did not respond, neither did the tibialis anterior muscle. The median values and

ranges of the latency and the CMAP area are shown in Table 3. Some differences were noticed between the two muscles. The gastrocnemius latencies were slightly longer than the tibialis anterior latencies, while gastrocnemius areas were smaller than the tibialis anterior areas. The variability in the CMAP area was larger for the gastrocnemius muscle than for the tibialis anterior muscle.

Table 3 Compound muscle action potential after percutaneous electrical nerve stimulation

Muscle	Latency (ms)		CMAP area (mVms)		n
	Median	Range	Median	Range	
TA right	2.6	1.8-5.8	6.7	0.3-19.4	31
TA left	2.6	1.8-5.5	4.7	0.2-19.5	31
GC right	3.3	2.5-4.5	4.0	0.0-26.6	19
GC left	3.1	2.1-5.0	3.6	0.0-26.7	20

TA, tibialis anterior muscle; GC, gastrocnemius muscle; n, number of patients

Only slight left-to-right differences were observed for MEP and CMAP parameters, but none of these differences were statistically significant. No differences were present between the subgroup in which only the tibialis anterior and quadriceps femoris muscle were investigated (n = 13) and the subgroup in which all three lower limb muscles were investigated (n = 23). Therefore, further analyses pertain to the total group of patients, while results are presented for the right side only.

Radiological and clinical assessment

The anatomical level of the spinal anomaly was thoracic in seven infants (19%), lumbar in 27 infants (75%), and sacral in two infants (6%). See Table 1. Neonatal motor impairment level was assessed as thoracic in 12 infants (33%), as lumbar in 16 infants (44%), and as sacral in eight infants (22%). Neonatal sensory impairment level was assessed as thoracic in seven infants (19%), as lumbar in 18 infants (50%), and as sacral in 11 infants (31%).

Associations between neurophysiological measures and clinical and radiological assessment at neonatal age

The associations between the neurophysiological measures and neonatal clinical assessment are shown in Table 4. Lower levels of neonatal motor and sensory impairment were statistically significantly associated with larger gastrocnemius

Table 4 Spearman rank correlation coefficients (r) of MEP and CMAP parameters with neonatal neurological impairment and level of the spinal anomaly

	Motor impairment		Sensory impairment		Level of the spinal anomaly		n
	r	P-value	r	P-value	r	P-value	
MEP area							
Quadriceps femoris	0.31	0.09	0.26	0.16	-0.02	0.90	32
Tibialis anterior	0.31	0.10	0.39	*0.04*	-0.01	0.96	29
Gastrocnemius	0.66	*0.00*	0.60	*0.01*	-0.18	0.48	19
MEP latency							
Quadriceps femoris	-0.10	0.60	-0.11	0.56	-0.10	0.60	32
Tibialis anterior	-0.05	0.78	-0.13	0.50	0.24	0.21	29
Gastrocnemius	-0.24	0.33	-0.12	0.62	0.20	0.42	19
CMAP area							
Tibialis anterior	0.54	*0.00*	0.43	*0.02*	0.14	0.46	31
Gastrocnemius	0.79	*0.00*	0.56	*0.01*	0.13	0.61	19
CMAP latency							
Tibialis anterior	-0.34	0.06	-0.12	0.52	-0.22	0.24	31
Gastrocnemius	-0.26	0.28	-0.37	0.12	0.02	0.95	19

P-values <0.05 are indicated in italics; n, number of patients

and tibialis anterior CMAP areas and with larger gastrocnemius MEP areas, whereas these associations were slightly weaker for the quadriceps femoris and tibialis anterior MEP areas. Especially for sensory impairment, a cranio-caudal gradient was demonstrated for the MEP area: the more cranial the neurosegmental innervation of the muscle, the weaker the association seems to be. No meaningful associations were found between the latencies and motor or sensory impairment, or between any of the MEP or CMAP parameters and the anatomical level of the spinal anomaly.

Associations between clinical and neurophysiological measures at neonatal age and outcome measures

Five children (14%) died before the age of two years and two children (6%) were lost to follow up due to emigration. The remaining 29 children were further examined. Three children were assigned to MFC 1 (10%), four to MFC 2 (14%), nine to MFC 3 (31%), eight to MFC 4 (28%), and five to MFC 5 (17%). Of the 29 children, nine children were community ambulators (31%), four were household ambulators (14%), and 16 were non-functional ambulators (55%) at the age of two years.

The associations between the neurophysiological and clinical measures assessed after birth and MFC and ambulation status at two years of age are shown in Table 5. Lower neonatal motor en sensory impairment levels were seen in the

Table 5 Neonatal neurophysiological measurements and clinical impairment (median values) in relation to the outcome at two years of age

	Muscle function class		P-value[c]	Community ambulator		P-value[c]
	Mild[a] (n=7)	Severe[b] (n=22)		Yes (n=9)	No (n=20)	
MEP area						
Quadriceps femoris	2.7	2.1	0.83	3.6	1.6	0.23
Tibialis anterior	4.9	1.1	0.05	1.4	1.0	0.45
Gastrocnemius	2.5	1.8	0.15	2.5	1.6	0.44
CMAP area						
Tibialis anterior	8.7	4.3	*0.03*	8.1	4.3	0.15
Gastrocnemius	11.5	3.8	*0.03*	8.1	2.2	0.10
Clinical impairment						
Motor impairment	18.0	14.5	*0.00*	18.0	13.5	*0.00*
Sensory impairment	19.0	15.0	*0.00*	17.0	14.0	*0.01*
Level of the spinal anomaly	15.0	14.0	0.12	15.0	13.5	0.03

P-values <0.05 are indicated in italics
[a] Mildly impaired according to muscle function class 1 and 2
[b] Severely impaired according to muscle function class 3-5
[c] P-value based on Mann-Whitney U test
n, number of patients; these numbers pertain to the group in total and may be slightly different for the specific parameters assessed.

mildly impaired subgroups compared to the severely impaired subgroups for both MFC and ambulation. For the tibialis anterior and gastrocnemius MEP areas, the differences between mildly and severely impaired MFC subgroups approached statistical significance. The CMAP areas were statistically significantly larger in the mildly impaired children compared to the severely impaired children according to MFC (p=0.03). All MEP and CMAP areas were larger in the community ambulators compared to the non-community ambulators, but these differences did not reach statistical significance. The CMAP and MEP latencies did not differ between mildly and severely impaired children (data not shown).

Discussion

This study is the first to evaluate the prognostic value of MEP and CMAP recordings for infants with spina bifida, assuming that MEP and CMAP recordings may provide additional information about neonatal neurological impairment in the lower limb muscles. As such, this study showed associations between MEPs and neonatal neurological impairment in newborn infants with spina bifida. The magnitudes of the MEP in the lower limb muscles, represented by the area under the curve of the first negative wave, related to the levels of motor and sensory impairment. CMAP areas were also associated with these levels of impairment. The results on spinal magnetic stimulation have not been reported before. Findings on associations between the CMAP areas and neurological impairment in newborn infants with spina bifida have previously been described for a smaller group of patients [21]. Other authors also reported responses to be present in lower limb muscles in almost all infants with spina bifida, although they used other methods of stimulation, such as electrical neural plaque stimulation and faradic muscle stimulation [28], in addition to percutaneous electrical nerve stimulation [13]. In these studies, only the presence or absence of a response was evaluated in relation to clinical impairment. This cannot be a diagnostic criterion, however, when responses are present in virtually every infant. In contrast, the associations found between the MEP and CMAP areas and neurological impairment in our study showed that these areas provide information about the degree of neurological impairment.

The latencies did not relate to neurological impairment, probably because the ranges of the latency values were relatively small (Tables 2 and 3). The MEP latencies in the quadriceps femoris muscle were shorter than the MEP latencies in the other muscles, which is in accordance with the difference in distances from the point of excitation to the site of recording between the muscles.

A possible disadvantage of spinal magnetic stimulation is temporal dispersion [23,24]. However, as the MEP area is less liable to temporal dispersion than the amplitude, the area under the first negative curve was used as measure for the magnitude of the MEP. Other possible disadvantages of spinal magnetic stimulation are the inability to obtain maximal responses and the fact that the magnitude of the MEP depends on the stimulus site and the thickness of the intervening tissue between the coil and the motor neurons [29]. Maegaki et al. [30] suggested that the structure of vertebral bone surrounding the nerve roots interferes with the spread of magnetically induced currents. In children with spina bifida, all the structures surrounding the spinal cord and the nerve roots may be involved in the spinal anomaly, which may be of influence on the magnetically induced currents. Percutaneous electrical nerve stimulation was performed only for the tibialis anterior and gastrocnemius muscles. It would have been interestingly to perform electrical stimulation of the femoral nerve as well. However, this may be technically difficult as all infants had to be assessed in prone position in an incubator, because of the spinal anomaly. As such, femoral nerve stimulating would have resulted in unreliable responses. Besides, electrical stimulation of the femoral nerve may be too painful in infants. Despite these limitations, clear associations were found between the magnitudes of the MEPs and CMAPs and neonatal neurological impairment.

The results on sensory and motor impairment reflect the neurosegmental innervation of the muscles studied: the more cranial the neurosegmental innervation of the muscle, the weaker the association between the MEP area and sensory or motor impairment. These results are compatible with the results on the CMAPs after percutaneous electrical nerve stimulation. The results on neonatal motor impairment presented strong associations with CMAP areas of the gastrocnemius and tibialis anterior muscles and with the MEP areas of the gastrocnemius muscle, but no statistically significant associations with the MEP areas of the tibialis anterior and quadriceps femoris muscles were found.

Furthermore, the MEPs and CMAPs of the gastrocnemius and tibialis anterior muscles seem to be of prognostic value for motor development towards ambulation at two years of age. We found statistically significant differences in tibialis anterior and gastrocnemius CMAP areas and tibialis anterior MEP areas between the MFC subgroups. These MFCs are indicative of ambulation ability later in life. As the walking milestone might be delayed in children with spina bifida, some children will eventually become community ambulators at the age of six years [31]. This might explain why we did not find clear differences in the MEP and CMAP areas between the community ambulators and non-community ambulators, as ambulation status was assessed at the relatively early age of two years. The quadriceps femoris MEP areas did not differ between the two MFC

groups, which may be explained by the fact that children in MFC 1 and 2 (group 1) as well as children in MFC 3 (part of group 2) represent good knee extension.

The neonatal clinical parameters, motor and sensory impairment, showed strong segregations regarding MFC and ambulation status as well. To what extent MEPs and CMAPs are as accurate as neonatal clinical neurological examinations and whether they have additional prognostic value for ambulation reached at a later age than two years requires further study. Important in this respect are the quality of the neurological examination on the one hand and the skill level of the assessor performing the neurophysiological assessment on the other hand.

Conclusion

Clinical determination of neurological impairment in newborn infants with spina bifida is complex. The demarcation of impairment to spinal segments is a simplification of the actual impairment, because residual motor function is present in affected spinal segments caudally from this demarcation. MEPs and CMAPs might be useful tools to assess this residual function. Although these neurophysiological methods need some refinement, the present study showed that MEPs after spinal magnetic stimulation and CMAPs after percutaneous electrical nerve stimulation are promising additional instruments in the clinical evaluation of infants with spina bifida. They have some prognostic value regarding the early neurodevelopmental outcome and they may be valuable in complex cases and in research settings, where objective information is needed about the degree of neurological impairment.

Acknowledgements

The authors thank Y.M. van den Bogaard-Visco, M. Heykers, and J. Bor, Electrophysiological Technologists, for their efforts in the data acquisition and technical support of the measurements. Funding support was received from the Johanna Kinderfonds, Arnhem, The Netherlands and from the Kinderrevalidatie Fonds Adriaanstichting, Rotterdam, The Netherlands.

References

1. Busby A, Abramsky L, Dolk H, et al. Preventing neural tube defects in Europe: a missed opportunity. *Reprod Toxicol* 2005; 20:393-402.
2. Van der Pal-de Bruin KM, Buitendijk SE, Hirasing RA, den Ouden AL. Prevalence of neural tube defects in births before and after promotion of periconceptional folic acid supplementation. *Ned Tijdschr Geneeskd* 2000; 144:1732-1736.
3. Oakeshott P, Hunt GM, Poulton A, Reid F. Expectation of life and unexpected death in open spina bifida: a 40-year complete, non-selective, longitudinal cohort study. *Dev Med Child Neurol* 2010; 52:749-753
4. Verhoef M, Barf HA, Post MW, van Asbeck FW, Gooskens RH, Prevo AJ. Secondary impairments in young adults with spina bifida. *Dev Med Child Neurol* 2004; 46:420-427.
5. Adzick NS, Thom EA, Spong CY, et al. A Randomized trial of prenatal versus postnatal repair of myelomeningocele. *N Engl J Med* 2011; 364:993-1004.
6. Bruner JP, Tulipan N. Tell the truth about spina bifida. *Ultrasound Obstet Gynecol* 2004; 24:595-596.
7. Seitzberg A, Lind M, Biering-Sorensen F. Ambulation in adults with myelomeningocele. Is it possible to predict the level of ambulation in early life? *Childs Nerv Syst* 2008; 24:231-237.
8. Hunt GM, Oakeshott P, Kerry S. Link between the CSF shunt and achievement in adults with spina bifida. *J Neurol Neurosurg Psychiatry* 1999; 67:591-595.
9. Sharrard WJ. The segmental innervations of the lower limb muscles in man. *Ann R Coll Surg Engl* 1964; 35:106-122.
10. McDonald CM, Jaffe KM, Mosca VS, Shurtleff DB. Ambulatory outcome of children with myelomeningocele: effect of lower-extremity muscle strength. *Dev Med Child Neurol* 1991; 33:482-490.
11. McDonald CM, Jaffe KM, Shurtleff DB. Assessment of muscle strength in children with meningomyelocele: accuracy and stability of measurements over time. *Arch Phys Med Rehabil* 1986; 67:855-861.
12. Stark GD. Neonatal assessment of the child with a myelomeningocele. *Arch Dis Child* 1971; 46:539-548.
13. Stark GD, Drummond M. Neonatal electromyography and nerve conduction studies in myelomeningocele. *Neuropädiatrie* 1972; 3:409-420.
14. Sival DA, Brouwer OF, Bruggink JLM, et al. Movement analysis in neonates with spina bifida aperta. *Early Hum Dev* 2006; 82:227-234.
15. Sival DA, van Weerden TW, Vles JS, et al. Neonatal loss of motor function in human spina bifida aperta. *Pediatrics* 2004; 114:427-434.
16. Van der Vossen S, Pistorius LR, Mulder EJ, et al. Role of prenatal ultrasound in predicting survival and mental and motor functioning in children with spina bifida. *Ultrasound Obstet Gynecol* 2009; 34:253-258.
17. Beeker TW, Scheers MM, Faber JA, Tulleken CA. Prediction of independence and intelligence at birth in meningomyelocele. *Childs Nerv Syst* 2006; 22:33-37.
18. Hunt GM. Open spina bifida: outcome for a complete cohort treated unselectively and followed into adulthood. *Dev Med Child Neurol* 1990; 32:108-118.
19. Di Lazarro V, Pilato F, Oliviero A, Saturno E, Dileone M, Tonali PA. Role of motor evoked potentials in diagnosis of cauda equina and lumbosacral cord lesions. *Neurology* 2004; 63:2266-2271.
20. Geerdink N, Pasman JW, Roeleveld N, Rotteveel JJ, Mullaart RA. Responses to lumbar magnetic stimulation in newborns with spina bifida. *Pediatr Neurol* 2006; 34:101-105.
21. Geerdink N, Pasman JW, Rotteveel JJ, Roeleveld N, Mullaart RA. Compound muscle action potentials in newborn infants with spina bifida. *Dev Med Child Neurol* 2008; 50:706-711.
22. Tortori-Donati P, Rossi A, Cama A. Spinal dysraphism: a review of neuroradiological features with embryological correlations and proposal for a new classification. *Neuroradiology* 2000; 42:471-491.
23. Cros D, Day TJ, Shahani BT. Spatial dispersion of magnetic stimulation in peripheral nerves. *Muscle Nerve* 1990; 13:1076-1082.
24. Schulte-Mattler WJ, Jakob M, Zierz S. Assessment of temporal dispersion in motor nerves with normal conduction velocity. *Clin Neurophysiol* 1999; 110:740-747.

25. Johnson B, Fuglsang-Frederiksen A, de Carvalho M, Labarre-Vila A, Nix W, Schofield I. Amplitude, area and duration of the compound muscle action potential change in different ways over the length of the ulnar nerve. *Clin Neurophysiol* 2006; 117:2085-2092.
26. McCarthy GT. Treating children with spina bifida. *BMJ* 1991; 12:65-66
27. Charney EB, Weller SC, Sutton LN, Bruce DA, Schut LB. Management of the newborn with myelomeningocele; time for a decision-making process. *Pediatrics* 1985: 75:58-64.
28. Sugar M, Kennedy C. The use of electrodiagnostic techniques in the evaluation of the neurological deficit in infants with meningomyelocele. *Neurology* 1965; 15:787-793.
29. Macdonell RA, Cros D, Shahani BT. Lumbosacral nerve root stimulation comparing electrical with surface magnetic coil techniques. *Muscle Nerve* 1992; 15:885-890.
30. Maegaki Y, Maeoka Y, Takeshita K. Magnetic stimulation of the lumbosacral vertebral column in children: normal values and possible sites of stimulation. *Electroencephalogr Clin Neurophysiol* 1997; 105:102-108.
31. Bartonek A. Motor Development toward ambulation in preschool children with myelomeningocele – A prospective study. *Pediatr Phys Ther* 2010; 22:52-60.

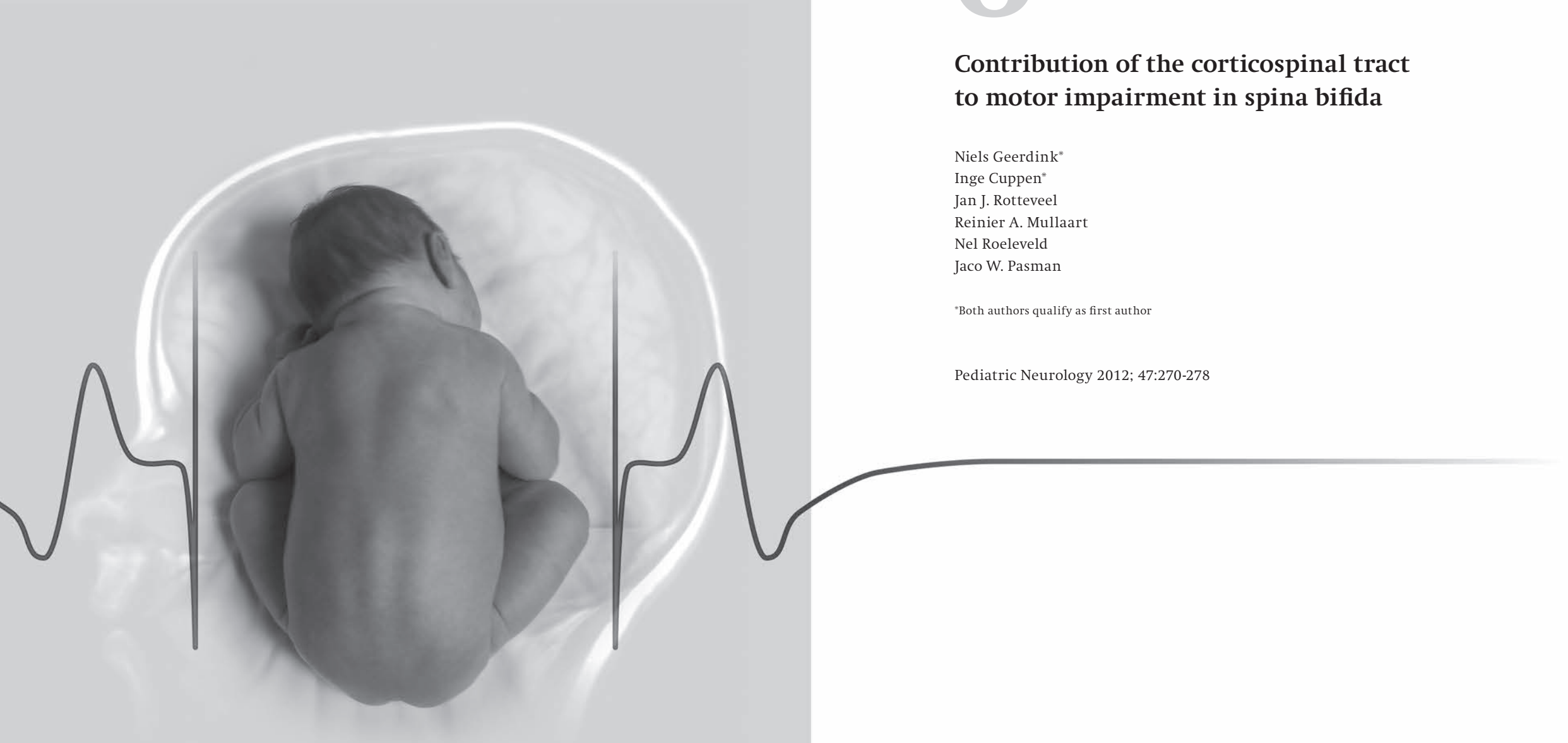

6

Contribution of the corticospinal tract to motor impairment in spina bifida

Niels Geerdink*
Inge Cuppen*
Jan J. Rotteveel
Reinier A. Mullaart
Nel Roeleveld
Jaco W. Pasman

*Both authors qualify as first author

Pediatric Neurology 2012; 47:270-278

Abstract

We aimed to disentangle the proportional contributions of upper motor neuron (UMN) and lower motor neuron (LMN) dysfunction to motor impairment in children with spina bifida. We enrolled 42 children (mean [SD] age, 11.2 [2.8] years) with spina bifida and 36 control children (mean [SD] age, 11.4 [2.6] years). Motor impairment was graded to known severity scales in children with spina bifida. Motor evoked potentials (MEPs) after transcranial and lumbosacral magnetic stimulation and compound muscle action potentials (CMAPs) after electrical nerve stimulation were recorded in all children. Regarding LMN function, severely impaired children with spina bifida demonstrated smaller CMAP areas and lumbosacral MEP areas than control children, whereas mildly impaired children hardly differed from control children. CMAP latencies and lumbosacral MEP latencies did not differ between children with spina bifida and control children. Regarding UMN function, children with spina bifida demonstrated smaller transcranial MEP areas and longer central motor conduction times (CMCTs) than control children. Smallest MEP areas and longest CMCTs were observed in severely impaired children. These findings suggest that in children with spina bifida, the contribution of UMN dysfunction to motor impairment is more considerable than expected from clinical neurological examination.

Introduction

Spina bifida is a complex congenital malformation of the nervous system in which lower limb motor impairment may result from lower motor neuron (LMN) and upper motor neuron (UMN) dysfunction. LMN dysfunction directly results from segmental disorders in the spinal anomaly. UMN dysfunction, however, may result from disorders of the corticospinal tract either in or above the spinal anomaly. Disorders above the spinal anomaly are Chiari II malformation and white [1,2] and gray matter [3,4] abnormalities, whether or not related to hydrocephalus. Given the complex neuropathology, knowledge about the proportional contribution of LMN and UMN dysfunction to lower limb motor impairment is limited. However, when choices about treatment opportunities, such as prenatal surgery, are necessary, it is essential to distinguish corticospinal from spinal motor dysfunction in spina bifida.

In prenatal surgery, secondary damage to neural tissue may be prevented by covering the spinal anomaly at an early gestational age [5,6]. A randomized trail demonstrated improvement of motor outcome and reductions of hindbrain herniation and hydrocephalus shunting after prenatal surgery compared to postnatal surgery [7]. These important improvements at more than one level along the neural axis may be associated with corticospinal and spinal motor function improvement.

Distinguishing UMN from LMN dysfunction in neurological examinations is difficult, because predominant flaccid paresis may mask UMN involvement. Traditionally, the level of motor impairment is classified according to the segmental innervation scheme of Sharrad [8,9], but for prognostic purposes, the use of specific patterns of muscle strength seems more robust [10,11]. Although UMN signs are important in predicting outcomes [12], classifications do not differentiate between UMN and LMN dysfunction.

Motor evoked potentials (MEPs) after magnetic stimulation are particularly useful to investigate UMN and LMN dysfunction, and are of diagnostic value in several neurological disorders in adults and children [13,14]. They constitute a safe and noninvasive method that is easily used and well tolerated [15,16]. Transcranial magnetic stimulation provides information about cortical motor function and the integrity of the corticospinal tract, whereas lumbosacral magnetic stimulation and nerve conduction studies, among others, by means of compound muscle action potential (CMAP) recording, provide information about spinal motor function [17].

The present study sought to disentangle the proportional contributions of UMN and LMN dysfunction to lower limb motor impairment in children with spina bifida. We hypothesized that clinically hidden UMN dysfunction could be revealed using transcranial magnetic stimulation.

Methods

Participants

Children with spina bifida were recruited from the Outpatient Clinic of Pediatric Neurology at the Radboud University Nijmegen Medical Centre in the Netherlands. Inclusion criteria comprised: 1) Birth between January 1988 and December 1997; 2) Presence of an open spinal dysraphism, such as myelomeningocele or myelocele, or a closed spinal dysraphism with a subcutaneous mass, such as lipomyelocele, lipomyelomeningocele, or meningocele [18], as assessed by neonatal physical examination and magnetic resonance imaging in the context of a larger research project and classified according to Rossi et al [18]. Exclusion criteria comprised: 1) Presence of a closed dysraphic state without a subcutaneous mass, such as intradural lipoma, tight filum terminale, dermal sinus, or diastematomyelia [18]; 2) Additional congenital malformations, except for cerebral malformations that are commonly associated with spinal dysraphism, such as hydrocephalus, Chiari II malformation, and corpus callosum dysgenesis.

Control children were recruited from the Outpatient Clinics of General Pediatrics, Pediatric Surgery, and Pediatric Orthopedics at the Radboud University Nijmegen Medical Centre. Inclusion criteria comprised: 1) Good health and physical condition; 2) Transient disease with complete recovery. Exclusion criteria comprised: 1) Suspicion or presence of neurological abnormalities, developmental delay, or behavioral disorder, as ascertained from chart review, interview, and complete neurological examination; 2) Chronic disease.

The Regional Committee on Research involving Human Subjects approved the study design. Written informed consent was obtained from parents of all participating children, and from all children above 12 years of age.

Clinical evaluation

We used three measures to assess lower limb motor function: muscle strength, muscle function class, and ambulation. Muscle strength was graded bilaterally on a 0-5 scale by manual muscle testing [19]. The muscle strengths of the quadriceps femoris, tibialis anterior, and gastrocnemius muscles were analyzed as separate variables. Muscle function classes were defined according to patterns of muscle strength [10,11]: 0, no weakness in any lower limb muscle; 1, weakness of intrinsic foot muscles; 2, weakness or absence of plantar flexion; 3, weakness or absence of knee flexion; 4, weakness or absence of knee extension; and 5, no muscle activity in the lower limbs. Ambulation was classified according to modified Hoffer criteria [11,20] into: 1, community ambulation; 2, community ambulation with wheelchair use only for long distances outdoors; 3, household ambulation with wheelchair use outdoors only; 4, household ambulation with wheelchair use indoors and outdoors; and 5, nonfunctional ambulation.

In addition, the spinal anomaly and the presence of Chiari II malformation, hydrocephalus, or corpus callosum dysgenesis were assessed by magnetic resonance imaging (1.5 T magnetic resonance imaging unit, Siemens Avanto, Siemens Medical Solutions, Erlangen, Germany).

Neurophysiological assessment

The children with spina bifida and the control children without spina bifida underwent the same neurophysiological investigations. All children were sitting on a chair or lying on a couch while MEPs and CMAPs were recorded using surface electrodes (standard tendon-belly montage) and an Oxford Synergy Electromyograph (Oxford Instruments, Old Woking, Surrey, UK; band-pass filter 20 Hz and 3 kHz, amplifier range 100 mV, and display sensitivity 0.5 mV/division). We obtained MEPs bilaterally from the quadriceps femoris, tibialis anterior, gastrocnemius, and biceps brachii muscles; and CMAPs from the tibialis anterior and gastrocnemius muscles.

For magnetic stimulation, a monophasic stimulator (Magstim 200, The Magstim Co. Ltd., UK) was used. Transcranial magnetic stimulation was performed at 100 % stimulation, intensity with a double 110mm cone coil positioned centrally over the vertex to record MEPs from the lower limb muscles, and with a 90mm circular coil positioned centrally over the vertex to record MEPs from the biceps brachii muscle. Unfacilitated MEPs were recorded during relaxation of the target muscle and facilitated MEPs during active isometric contraction of the target muscle against manual resistance. If children with spina bifida were unable to perform a contraction, we asked them to pretend they were performing a contraction. This strategy will also result in facilitated MEPs [17].

Spinal magnetic stimulation was performed with a 90mm circular coil positioned centrally over the spine. In all children, cervical magnetic stimulation was performed over C7 to record MEPs from the biceps brachii muscle. In control children, lumbosacral stimulation was performed at L5 for the quadriceps femoris muscle and at S1 for the tibialis anterior and gastrocnemius muscles, where we expected the largest MEPs [21]. Because of the abnormal anatomy of the spine, lumbosacral stimulation was performed successively at four levels (L4, L5, S1, and S2) to search for the largest MEP in children with spina bifida. This MEP was then used in the analyses. Stimulation intensity was 100% in all children, except for a few control children in whom this intensity led to discomfort. In these children, we used stimulation intensities of 80% or 90%. No substantial response differences were expected at intensities ranging from 80% to 100% [22].

In addition, percutaneous electrical stimulation of the peroneal nerve and the posterior tibial nerve was performed at the popliteal fossa to assess the maximal CMAP in the tibialis anterior and gastrocnemius muscles, respectively.

For each MEP and CMAP the onset latency (ms) and the area under the curve of the first negative wave (mVms) were calculated. For each target muscle, the central motor conduction time (CMCT; ms) was calculated from the difference between the onset latency of the facilitated transcranial MEP and the onset latency of the spinal MEP.

During investigation, children were observed for discomfort by an independent observer. In case of discomfort, we terminated the investigation prematurely.

Statistical analysis

The three clinical measures were analyzed as dichotomized variables resulting in a mildly and a severely impaired subgroup for each measure: muscle strength of 0-3 (weakness) versus muscle strength of 4-5 (no or little weakness); muscle function classes 0-2 (expected to be ambulant) versus muscle function classes 3-5 (expected not to be ambulant); and ambulation groups 1-2 (community ambulant) versus ambulation groups 3-5 (non-community ambulant).

Because the neurophysiological data were not normally distributed, we used nonparametric tests. The Mann-Whitney U test was used to study differences in neurophysiological parameters between children with spina bifida and control children, and between mildly and severely impaired children with spina bifida. Differences between unfacilitated and facilitated MEPs were analyzed using the Wilcoxon test for paired observations. P-values less than 0.05 were considered statistically significant.

Results

Participants

Forty-two children (16 boys and 26 girls) with spina bifida were enrolled in the study. Twenty-six children manifested open spinal dysraphism and 16 manifested closed spinal dysraphism with a subcutaneous mass. The level of the spinal anomaly was thoracic in nine, lumbar in 31, and sacral in two children. Twenty-four children manifested hydrocephalus, 23 manifested Chiari II malformation, and 18 manifested corpus callosum dysgenesis. The mean age ± SD was 11.2 ± 2.8 years (range, 6.5 – 16.8 years). All children had undergone neonatal spinal surgery, and all children with hydrocephalus were shunted within the first month of age. At the moment of investigation, none of the children presented signs of shunt malfunction.

Thirty-six control children (13 boys and 23 girls) were enrolled in the study. The mean age ± SD was 11.4 ± 2.6 years (range, 6.1 – 15.8 years).

Clinical evaluation

Lower limb motor function in the children with spina bifida was assessed by three clinical measures: muscle strength, muscle function class, and ambulation. Regarding muscle strength, nine children demonstrated weakness (grade 0-3 on manual muscle testing) of the quadriceps femoris muscles, 18 of the tibialis anterior muscles, and 20 of the gastrocnemius muscles. Muscle function class 0-2 applied to 29 children, and muscle function class 3-5 applied to 13 children. Regarding ambulation, 25 children were community ambulant, and 17 were noncommunity ambulant. In our description of the results on upper and lower motor neuron function, the subgroups based on these three clinical measures will be referred to as mildly or severely impaired.

Recorded MEPs and CMAPs

In a few children with spina bifida, the measurements were incomplete because of premature termination of the investigation upon discomfort, or else transcranial or spinal magnetic stimulation did not result in MEPs. As such, the number of available MEPs per target muscle ranged from 23 to 34 after transcranial magnetic stimulation, and from 34 to 38 after spinal magnetic stimulation. CMAPs in the tibialis anterior and gastrocnemius muscles were available for 40 and 36 children with spina bifida, respectively. In 12 control children, the measurements were incomplete because of premature termination. In the remaining control children, all responses were obtained. The number of available MEPs per target muscle ranged from 24 to 30 after transcranial magnetic stimulation and from 29 to 31 after spinal magnetic stimulation. CMAPs in the tibialis anterior and gastrocnemius muscles were available for 30 control children for each muscle.

Lower motor neuron function

CMAPs and lumbosacral MEPs provide information about LMN function. CMAP areas (area under the curve of the first negative wave of a CMAP) were smaller in children with spina bifida than in control children. Among children with spina bifida, CMAP areas were smallest in severely impaired children, whereas mildly impaired children differed from control children only for gastrocnemius CMAP areas (Table 1, Figure 1). Results for the lumbosacral MEP area in the quadriceps femoris muscle were similar to the results for the CMAP area. Lumbosacral MEP areas were smaller in children with spina bifida than in control children, except for the tibialis anterior muscle. Among children with spina bifida, MEP areas

Table 1 CMAP area and latency (median values) in control children and children with spina bifida

	Area (mVms)				Latency (ms)			
	TA	P-value[a]	GM	P-value	TA	P-value	GM	P-value
Spina bifida versus control								
Control	12.2		21.2		2.9		3.3	
Spina bifida	7.5	<0.01	8.3	<0.01	2.7	0.30	3.1	0.12
Among children with spina bifida								
Muscle strength target muscle								
No or little weakness (4-5)	10.9		9.8		2.5		2.8	
Weakness (0-3)	4.3	<0.01	6.8	0.07	3.1	0.02	3.5	0.01
Muscle function class								
Class 0-2	10.5		9.2		2.5		2.8	
Class 3-5	3.3	<0.01	6.7	0.03	3.3	0.01	3.5	0.05
Ambulation								
Community ambulation	10.5		9.2		2.6		2.8	
Non-community ambulation	5.2	<0.01	6.7	0.07	3.1	0.04	3.5	0.08

[a] P-value based on Mann-Whitney U test.
CMAP, compound muscle action potential; TA, tibialis anterior muscle; GM, gastrocnemius muscle

were smallest in severely impaired children, whereas mildly impaired children differed slightly from control children (Table 2, Figure 1).

CMAP latencies and lumbosacral MEP latencies did not differ between children with spina bifida and control children. Among children with spina bifida, CMAP latencies were longest in severely impaired children, whereas lumbosacral MEP latencies did not differ between mildly and severely impaired children (Tables 1 and 2, Figure 1).

Upper motor neuron function

Transcranial MEPs and CMCTs provide information about UMN function. Facilitated transcranial MEP areas were smaller in children with spina bifida than in control children for the lower limb muscles, as well as for the upper limb muscle. MEP areas were smallest in severely impaired children, while mildly

Table 2 Lumbosacral MEP area and latency (median values) in control children and children with spina bifida

	Area (mVms)				Latency (ms)			
	QF	P-value[a]	TA	P-value	QF	P-value	TA	P-value	GM	P-value
Spina bifida versus control										
Control	35.2		5.6		6.1		10.1		10.4	
Spina bifida	23.4	0.01	6.8	0.63	6.1	0.35	9.6	0.12	9.7	0.04
Among children with spina bifida										
Muscle strength target muscle										
No or little weakness (4-5)	27.9		8.1		6.1		9.7		9.2	
Weakness (0-3)	15.3	0.01	5.7	0.04	6.1	0.97	9.3	0.64	9.9	0.09
Muscle function class										
Class 0-2	32.6		8.1		6.1		9.7		9.5	
Class 3-5	15.3	<0.01	4.8	0.02	6.1	0.71	9.3	0.83	9.7	0.47
Ambulation										
Community ambulation	34.5		7.9		6.1		9.7		9.5	
Non-community ambulation	15.6	<0.01	5.7	0.04	6.1	0.71	9.2	0.48	9.7	0.71

[a] P-value based on Mann-Whitney U test.
MEP, motor evoked potential; QF, quadriceps femoris muscle; TA, tibialis anterior muscle; GM, gastrocnemius muscle

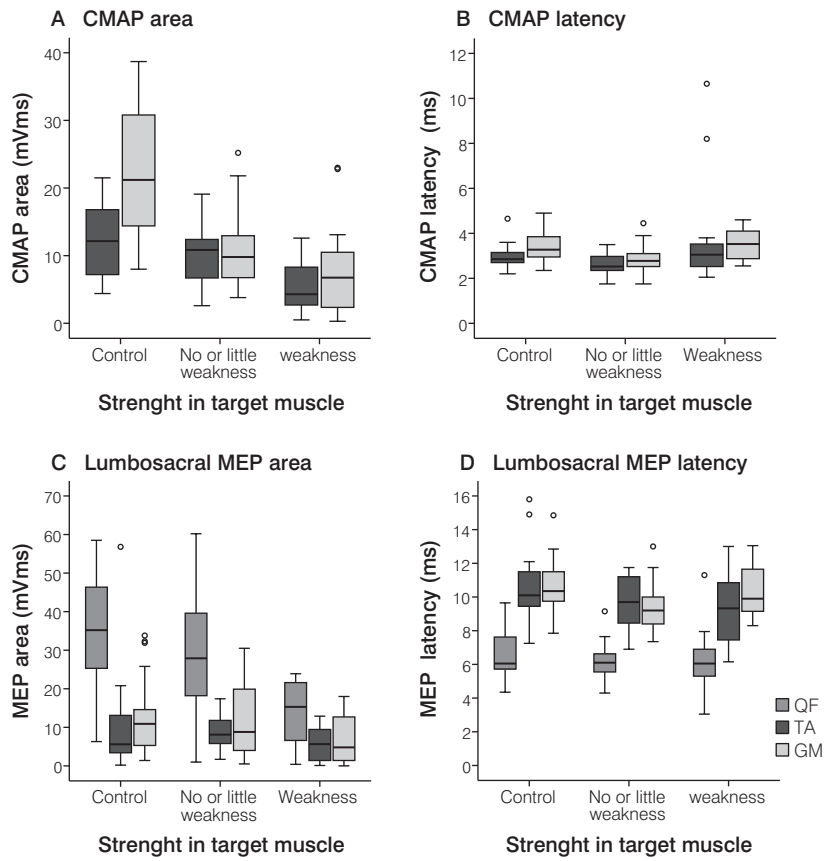

Figure 1 Box plots showing CMAP area (**A**), CMAP latency (**B**), lumbosacral MEP area (**C**), and lumbosacral MEP latency (**D**) in lower limb muscles in control children and in children with spina bifida grouped according to muscle strength in the target muscles. Bold horizontal lines indicate median values; boxes represent interquartile ranges (IQR), vertical lines represent 1.5 IQR, and separate points are outliers. QF, quadriceps femoris muscle; TA, tibialis anterior muscle; GM, gastrocnemius muscle.

impaired children still demonstrated substantially smaller MEP areas than did control children (Table 3, Figure 2). We observed similar results for facilitated MEP latencies, i.e., longer latencies in children with spina bifida compared to control children, and in severely impaired children compared with mildly impaired children (data not shown). In contrast, unfacilitated transcranial MEP areas and latencies did not differ between children with spina bifida and control children,

Table 3 MEP area (mVms; median values) of facilitated transcranial MEPs in control children and children with spina bifida

	QF	P-value[a]	TA	P-value	GM	P-value	BB	P-value
Spina bifida versus control								
Control	16.6		8.4		7.0		23.2	
Spina bifida	7.1	<0.01	4.2	0.02	2.9	<0.01	7.0	<0.01
Among children with spina bifida								
Muscle strength target muscle								
No or little weakness (4-5)	9.0		5.3		3.1			
Weakness (0-3)	1.0	<0.01	1.4	0.03	1.5	0.38		
Muscle function class								
Class 0-2	10.5		5.2		3.7		8.8	
Class 3-5	1.7	<0.01	1.4	0.02	0.7	0.02	5.0	0.12
Ambulation								
Community ambulation	10.7		5.2		4.1		8.1	
Non-community ambulation	1.9	<0.01	1.4	0.01	0.8	0.01	5.7	0.35

[a] P-value based on Mann-Whitney U test.
MEP, motor evoked potential; QF, quadriceps femoris muscle; TA, tibialis anterior muscle; GM, gastrocnemius muscle; BB, biceps brachii muscle

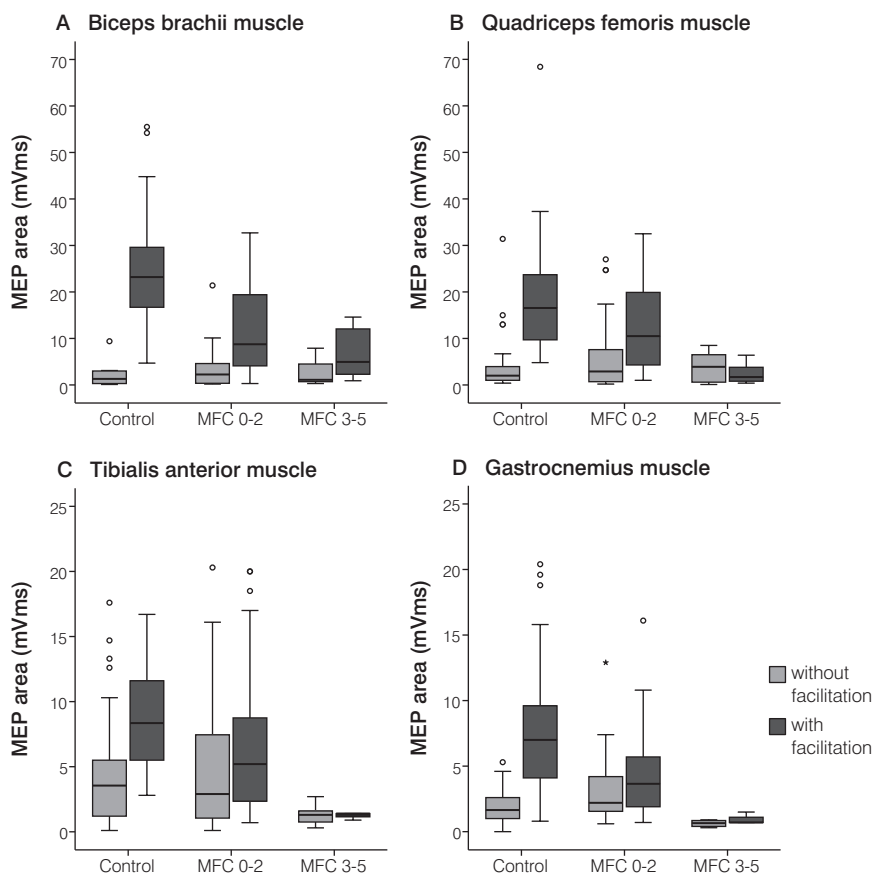

Figure 2 Box plots showing differences between facilitated and unfacilitated transcranial MEP areas in control children, mildly impaired children (MFC 0-2) and severely impaired children (MFC 3-5) with spina bifida for four muscles: biceps brachii muscle (**A**), quadriceps femoris muscle (**B**), tibialis anterior muscle (**C**), and gastrocnemius muscle (**D**). Bold horizontal lines indicate median values; boxes represent interquartile ranges (IQR), vertical lines represent 1.5 IQR, and separate points are outliers. MFC, muscle function class.

or among children with spina bifida. Hence, facilitated MEP areas were larger than unfacilitated MEP areas in control children and in mildly impaired children with spina bifida, but not in severely impaired children. These results are illustrated according to muscle function class in Figure 2.

Table 4 Central motor conduction time (ms; median values) in control children and children with spina bifida

	QF	P-value[a]	TA	P-value	GM	P-value	BB	P-value
Spina bifida versus control								
Control	11.1		12.1		14.6		4.6	
Spina bifida	12.7	<0.01	16.1	<0.01	16.4	0.02	5.6	<0.01
Among children with spina bifida								
Muscle strength target muscle								
No or little weakness (4-5)	12.5		15.1		15.7			
Weakness (0-3)	14.9	0.53	21.5	0.01	19.4	0.04		
Muscle function class								
Class 0-2	12.4		15.3		16.2		5.3	
Class 3-5	15.0	0.09	21.7	0.03	19.4	0.32	6.8	0.01
Ambulation								
Community ambulation	12.7		15.3		16.4		5.2	
Non-community ambulation	13.6	0.63	21.7	0.03	17.3	0.57	6.6	0.07

[a] P-value based on Mann-Whitney U test.
QF, quadriceps femoris muscle; TA, tibialis anterior muscle; GM, gastrocnemius muscle; BB, biceps brachii muscle

CMCTs were longer in children with spina bifida than in control children for the lower limb muscles, as well as for the upper limb muscle. CMCTs were longer in severely impaired children compared to mildly impaired children, although not statistically significant for all muscles, whereas mildly impaired children still had longer CMCTs than did control children (Table 4, Figure 3).

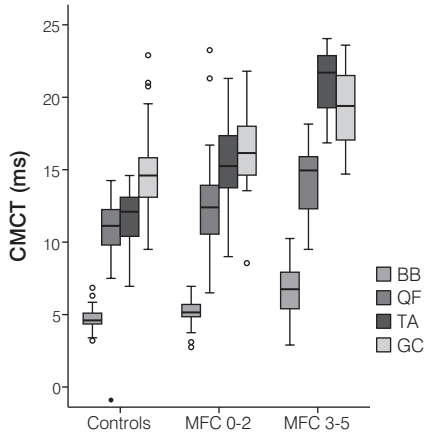

Figure 3 Box plots showing differences in CMCT between control children, mildly impaired children (MFC 0-2) and severely impaired children (MFC 3-5) with spina bifida. Bold horizontal lines indicate median values; boxes represent interquartile ranges (IQR), vertical lines represent 1.5 IQR, and separate points are outliers. MFC, muscle function class; BB, biceps brachii muscle; QF, quadriceps femoris muscle; TA, tibialis anterior muscle; GM, gastrocnemius muscle.

Discussion

Spina bifida is a congenital malformation of the nervous system with complex neuropathology involving corticospinal and spinal motor pathways. In an attempt to disentangle UMN involvement from LMN involvement in lower limb motor impairment, this study demonstrated UMN dysfunction in both mildly and severely impaired children with spina bifida, whereas LMN dysfunction was mainly observed in severely impaired children.

UMN dysfunction was identified by reduced transcranial MEP areas and prolonged CMCTs. The transcranial MEP area may also reflect LMN dysfunction, but the CMCT above all reflects UMN dysfunction. The degree of UMN dysfunction

seemed to be associated with the severity of clinical motor impairment. Moreover, the CMCTs resembled the different neurosegmental innervations of the investigated muscles. In the complex neuropathology of spina bifida, the origin of UMN dysfunction may occur in the corticospinal tract in or above the spinal anomaly. Because the results were similar for both upper and lower limb muscles, we considered UMN dysfunction to be located above the spinal anomaly, or to be more specific, above the neurosegmental innervation of the biceps brachii muscle. This may result from damage to the corticospinal tract at the cervicomedullary junction due to hindbrain herniation or from white matter abnormalities, whether or not related to hydrocephalus. This latter explanation may be supported by diffusion tensor imaging studies revealing complex white matter abnormalities in spina bifida [1].

As observed in the control children, voluntary muscle contraction during transcranial magnetic stimulation results in shorter MEP latencies and larger MEP areas [23]. This facilitation was substantially decreased in children with spina bifida (Figure 2). Although the physiology of facilitation is not entirely understood, changes in both spinal and cortical excitability seem to be involved [24]. Based on our results, it difficult to deduce whether abnormalities in spinal or cortical excitability are responsible for the decreased facilitation. Remarkably, even in muscles with no or little weakness (i.e., children were able to perform a contraction of at least MRC grade 4) and with substantial CMAPs, facilitated MEPs were smaller than in control muscles. Therefore, the simple explanation that the inability to perform a muscle contraction results in smaller facilitated MEPs is not applicable. We suggest that abnormal cortical excitability is responsible for the decreased facilitation in spina bifida.

LMN dysfunction can be identified from CMAPs and lumbosacral MEPs. CMAP areas and lumbosacral MEP areas were reduced mainly in severely impaired children with spina bifida, whereas latencies were unaffected in both mildly and severely impaired children. Therefore, the number of motor units may be reduced, because of axonal loss, particularly in severely impaired children, whereas the conduction ability of the preserved motor units seems to be relatively intact. Moreover, CMAPs and lumbosacral MEPs were still obtainable in clinically paralytic muscles. These results are compatible with previously reported LMN function in newborn infants with spina bifida [25,26].

Differentiation between UMN and LMN dysfunction is scarcely addressed in reports on neurological outcome of spina bifida. In observational studies of newborn infants, the disappearance of lower limb movements has been related to LMN dysfunction, whereas neural conduction through the spinal anomaly was related to preserved UMN function [27]. Although we investigated older children, our results are slightly in contrast with those previous results, because

UMN dysfunction was more obviously involved in motor impairment, whereas LMN function seems to be relatively preserved throughout the childhood years. We hypothesize that LMN dysfunction is secondary to UMN dysfunction, because the UMN is involved in the activity-dependent regulation of the development of the LMN [28].

These findings may involve consequences for clinical practice. Although flaccid paresis is generally the most prominent clinical sign, LMN dysfunction may play a minor role in motor impairment. UMN dysfunction, on the other hand, although it is masked by flaccid paresis, seems to contribute considerably to motor impairment. Our results also indicate that UMN dysfunction is related to functional outcome, because the ability to walk was associated with the degree of UMN dysfunction. Moreover, UMN dysfunction should be considered in case of unexplained deterioration of function. For example, secondary tethering of the spinal cord is commonly observed in growing children with spina bifida, and is generally associated with additional UMN dysfunction. Transcranial magnetic stimulation may be helpful in the early recognition of this complication.

Furthermore, transcranial and spinal magnetic stimulation may provide objective information about corticospinal and spinal motor function in research settings, with particular relevance for the outcomes of prenatal surgery for spina bifida. Prenatal surgery offers promise for improvements in motor function and reductions of hindbrain herniation and hydrocephalus shunting [7]. Using transcranial and spinal magnetic stimulation, the improvement of UMN and LMN function in relation to the reported clinical and morphological improvements may be disclosed.

The study contains some limitations. 1) Because of our cross-sectional design, the study group was heterogeneous. We did not differentiate the neurophysiological results between open and closed spinal dysraphism or between presence and absence of cerebral comorbidity, because we were primarily interested in lower limb motor impairment in relation to LMN and UMN dysfunction. 2) The level of lumbosacral magnetic stimulation differed between children with spina bifida and control children. Performing lumbosacral stimulation at one level does not make sense in children with spina bifida, because of the abnormal anatomy of the spine and spinal cord. Nevertheless, abnormal anatomy may have had some influence on the results of lumbosacral magnetic stimulation. 3) We estimated the CMCT from the difference between the latencies of the transcranial MEP and the lumbosacral MEP. Using this method, the calculated CMCT includes a small part of the proximal LMN, because lumbosacral magnetic stimulation results in activation of motor nerve roots at the site where they leave the intervertebral foramen [21,29]. However, considering the unaffected lumbosacral MEP latency in children with spina bifida, the part of the proximal LMN included will be

equal for children with spina bifida and control children. Therefore, the differences in CMCT primarily reflect a difference in corticospinal motor conduction between children with spina bifida and control children. 4) In some children, the study protocol was incompletely applied. However, a sufficient number of responses were available for the analyses. In children with spina bifida, a few muscles were unresponsive. We did not use these results in the analyses, as this would have rendered the differences with the control children unjustifiably large. 5) We did not relate the results to body height or age. This factor may hold some relevance for the MEP latency, but not for the MEP area and the CMCT. The CMCT in particular is unrelated to age and body height after the age of five years [30,31].

In conclusion, the contribution of UMN dysfunction to lower limb motor impairment is more considerable than expected from neurological examination in children with spina bifida. This UMN dysfunction seems to originate in the corticospinal tract above the spinal anomaly. These findings provide additional understanding of the complex corticospinal and spinal pathology of spina bifida. As such, transcranial magnetic stimulation may be of value in clinical settings and in research settings to objectively asess motor impairment in spina bifida.

Acknowledgments

We thank Jos Draaisma MD, PhD, Jean Gardeniers MD, PhD, and René Severijnen MD, PhD for the enrolment of control children; Yvonne van den Bogaard-Visco, Mirjam Heykers, and Jose Bor, Electrophysiological Technologists, for their diligence in the data acquisition and technical support of the measurements; and Michèl Willemsen MD, PhD for his comments on the manuscript.

References

1. Hasan KM, Eluvathingal TJ, Kramer LA, Ewing-Cobbs L, Dennis M, Fletcher JM. White matter microstructural abnormalities in children with spina bifida myelomeningocele and hydrocephalus: a diffusion tensor tractography study of the association pathways. *J Magn Reson Imaging* 2008; 27:700-709.
2. Herweh C, Akbar M, Wengenroth M, et al. DTI of commissural fibers in patients with Chiari II-malformation. *Neuroimage* 2009; 44:306-311.
3. Juranek J, Fletcher JM, Hasan KM, et al. Neocortical reorganization in spina bifida. *Neuroimage* 2008; 40:1516-1522.
4. Miller E, Widjaja E, Blaser S, Dennis M, Raybaud C. The old and the new: supratentorial MR findings in Chiari II malformation. *Childs Nerv Syst* 2008; 24:563-575.
5. Adzick NS, Sutton LN, Crombleholme TM, Flake AW. Successful fetal surgery for spina bifida. *Lancet* 1998; 352:1675-1676.
6. Adzick NS. Fetal myelomeningocele: natural history, pathophysiology, and in-utero intervention. *Semin Fetal Neonatal Med* 2010; 15:9-14.
7. Adzick NS, Thom EA, Spong CY, et al. A randomized trial of prenatal versus postnatal repair of myelomeningocele. *N Engl J Med* 2011; 364:993-1004.
8. Sharrard WJ. The segmental innervation of the lower limb muscles in man. *Ann R Coll Surg Engl* 1964; 35:106-122.
9. Bartonek A, Saraste H, Knutson LM. Comparison of different systems to classify the neurological level of lesion in patients with myelomeningocele. *Dev Med Child Neurol* 1999; 41:796-805.
10. McDonald CM, Jaffe KM, Mosca VS, Shurtleff DB. Ambulatory outcome of children with myelomeningocele: effect of lower-extremity muscle strength. *Dev Med Child Neurol* 1991; 33:482-490.
11. Bartonek A, Saraste H. Factors influencing ambulation in myelomeningocele: a cross-sectional study. *Dev Med Child Neurol* 2001; 43:253-260.
12. Bartonek A, Gutierrez EM, Haglund-Akerlind Y, Saraste H. The influence of spasticity in the lower limb muscles on gait pattern in children with sacral to mid-lumbar myelomeningocele: a gait analysis study. *Gait Posture* 2005; 22:10-25.
13. Chen R, Cros D, Curra A, et al. The clinical diagnostic utility of transcranial magnetic stimulation: report of an IFCN committee. *Clin Neurophysiol* 2008; 119:504-532.
14. Frye RE, Rotenberg A, Ousley M, Pascual-Leone A. Transcranial magnetic stimulation in child neurology: current and future directions. *J Child Neurol* 2008; 23:79-96.
15. Rossi S, Hallett M, Rossini PM, Pascual-Leone A. Safety, ethical considerations, and application guidelines for the use of transcranial magnetic stimulation in clinical practice and research. *Clin Neurophysiol* 2009; 120:2008-2039.
16. Gilbert DL, Garvey MA, Bansal AS, Lipps T, Zhang J, Wassermann EM. Should transcranial magnetic stimulation research in children be considered minimal risk? *Clin Neurophysiol* 2004; 115:1730-1739.
17. Weber M, Eisen AA. Magnetic stimulation of the central and peripheral nervous systems. *Muscle Nerve* 2002; 25:160-175.
18. Rossi A, Gandolfo C, Morana G, et al. Current classification and imaging of congenital spinal abnormalities. *Semin Roentgenol* 2006; 41:250-273.
19. Hislop HJ, Montgomery J. *Daniel's and Worthingham's muscle testing: techniques of manual examination.* 6th ed. Philadelphia: W.B. Saunders, 1995.
20. Hoffer MM, Feiwell E, Perry R, Perry J, Bonnett C. Functional ambulation in patients with myelomeningocele. *J Bone Joint Surg Am* 1973; 55:137-148.
21. Ugawa Y, Rothwell JC, Day BL, Thompson PD, Marsden CD. Magnetic stimulation over the spinal enlargements. *J Neurol Neurosurg Psychiatry* 1989; 52:1025-1032.
22. Van Kuijk AA, Anker LC, Pasman JW, Hendriks JC, van Elswijk G, Geurts AC. Stimulus-response characteristics of motor evoked potentials and silent periods in proximal and distal upper-extremity muscles. *J Electromyogr Kinesiol* 2009; 19:574-583.
23. Hess CW, Mills KR, Murray NM. Responses in small hand muscles from magnetic stimulation of the human brain. *J Physiol* 1987; 388:397-419.
24. Di Lazzaro V, Restuccia D, Oliviero A, et al. Effects of voluntary contraction on descending volleys evoked by transcranial stimulation in conscious humans. *J Physiol* 1998; 508:625-633.
25. Geerdink N, Pasman JW, Roeleveld N, Rotteveel JJ, Mullaart RA. Responses to lumbar magnetic stimulation in newborns with spina bifida. *Pediatr Neurol* 2006; 34:101-105.
26. Geerdink N, Pasman JW, Rotteveel JJ, Roeleveld N, Mullaart RA. Compound muscle action potentials in newborn infants with spina bifida. *Dev Med Child Neurol* 2008; 50:706-711.
27. Sival DA, Brouwer OF, Bruggink JL, et al. Movement analysis in neonates with spina bifida aperta. *Early Hum Dev* 2006; 82:227-234.
28. Eyre JA, Miller S, Clowry GJ, Conway EA, Watts C. Functional corticospinal projections are established prenatally in the human foetus permitting involvement in the development of spinal motor centres. *Brain* 2000; 123(Pt.1):51-64.
29. Chokroverty S, Flynn D, Picone MA, Chokroverty M, Belsh J. Magnetic coil stimulation of the human lumbosacral vertebral column: site of stimulation and clinical application. *Electroencephalogr Clin Neurophysiol* 1993; 89:54-60.
30. Eyre JA, Miller S, Ramesh V. Constancy of central conduction delays during development in man: investigation of motor and somatosensory pathways. *J Physiol* 1991; 434:441-452.
31. Fietzek UM, Heinen F, Berweck S, et al. Development of the corticospinal system and hand motor function: central conduction times and motor performance tests. *Dev Med Child Neurol* 2000; 42:220-227.

Part two

Brain MR imaging studies

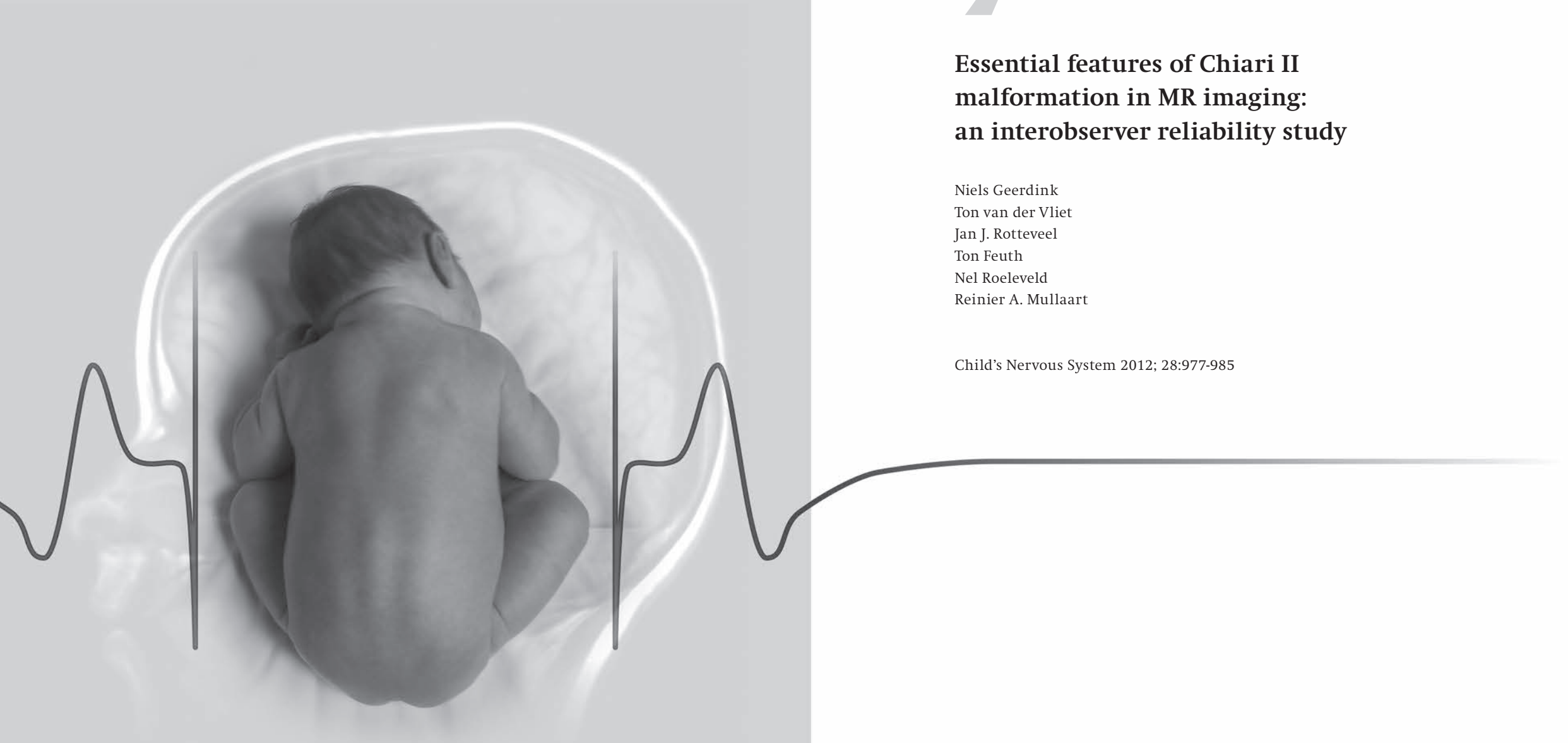

7

Essential features of Chiari II malformation in MR imaging: an interobserver reliability study

Niels Geerdink
Ton van der Vliet
Jan J. Rotteveel
Ton Feuth
Nel Roeleveld
Reinier A. Mullaart

Child's Nervous System 2012; 28:977-985

Abstract

Purpose Brain MR imaging is essential in the assessment of Chiari II malformation in clinical and research settings concerning spina bifida. However, the interpretation of morphological features of the malformation on MR images may not always be straightforward. In an attempt to select those features that unambiguously characterize the Chiari II malformation, we investigated the interobserver reliability of all its well-known MR features.

Methods Brain MR images of 79 children (26 presumed to have Chiari II malformation, 36 presumed to have no cerebral abnormalities, and 17 children in whom some Chiari II malformation features might be present; mean age 10.6 [SD 3.2; range 6 to 16] years) were blindly and independently reviewed by three observers. They rated 33 morphological features of the Chiari II malformation as present, absent, or indefinable in three planes (sagittal, axial, and coronal). The interobserver reliability was assessed using κ statistics.

Results Twenty-three of the features studied turned out to be unreliable, whereas the interobserver agreement was almost perfect (κ value > 0.8) for nine features (eight in the sagittal plane and one in the axial plane, but none in the coronal plane).

Conclusions This study presents essential features of the Chiari II malformation on MR images by ruling out the unreliable features. Using these features may improve the assessment of Chiari II malformation in clinical and research settings.

Introduction

Chiari II malformation is a complex developmental malformation of the central nervous system. It is characterized by a small posterior fossa and downward displacement of the cerebellum and brainstem through an enlarged foramen magnum (hindbrain herniation) [1]. Chiari II malformation is almost uniquely associated with open spinal dysraphism [2]. McLone and Knepper [3] hypothesized that leakage of cerebrospinal fluid through the spinal anomaly reduces the distension of the embryonic ventricular system. The decreased inductive pressure on the surrounding mesenchyme results in an abnormally small posterior fossa. Approximately one third of the patients with Chiari II malformation develop signs and symptoms of brainstem compression [4]. The mortality in this symptomatic group is 15 to 35% [5,6].

Usually, Chiari II malformation is clinically diagnosed with the help of MR imaging. On MR images, the malformation is characterized by a constellation of morphological features (Table 1). Most of these features were originally derived from post-mortem examinations [7-10] or computed tomography studies [11-14]. With the introduction of MR imaging, most features were simply adopted to evaluate MR images [15-19]. However, the interpretation of features as seen on MR images may not always be straightforward. First, the malformation is heterogeneous in itself and in its relation with spinal dysraphism. Second, an abundance of features exist, which may obscure unambiguous assessment of Chiari II malformation. Third, the definitions of some features are equivocal and reviewers may interpret features differently. Although most features are typical for Chiari II malformation, knowledge about the reliability of rating these features on MR images is lacking.

Still, brain MR imaging plays a substantial role in clinical decision making regarding the management of children with spina bifida [18,20]. On the one hand, the discussion on selective treatment of severely affected newborn infants is still ongoing [21]. On the other hand, fetal imaging and prenatal surgery are becoming more important every day. Recently, a randomized trial showed important improvement of hindbrain herniation following prenatal surgery for spina bifida [22]. However, the assessment of Chiari II malformation may be even more complicated in prenatal MR imaging. A discrepancy of 41% was seen in judgment of the degree of cerebellar herniation in prenatal MR imaging studies [23]. When choices have to be made about prenatal and postnatal treatment options, it is important to have consensus about the morphological features that unambiguously characterize Chiari II malformation. As a proper reference standard is not available, however, testing the validity of different features is unattainable. The next best method to appraise these features is to evaluate interobserver reliability.

Table 1 Definitions of features of Chiari II malformation

Feature	Definition	Reference
Sagittal plane		
Downward herniation cerebellum	Either vermis, tonsil, or part of the cerebellum, below the foramen magnum	Variend and Emery [9]
Downward herniation vermis	Vermis below the foramen magnum	Variend and Emery [9]
Downward herniation tonsil	At least one tonsil below the foramen magnum	Variend and Emery [9]
Upward herniation cerebellum	Bulging of the cerebellum through the tentorial incisura	Peach [7] and Naidich et al. [12]
Downward displacement medulla	Stretching and downward displacement of the medulla below the foramen magnum	Emery and MacKenzie [8]
Downward displacement pons	Stretching and downward displacement of the pons towards spinal canal	Naidich et al. [14]
Downward displacement fourth ventricle	Stretching and downward displacement of the fourth ventricle	Emery and MacKenzie [8]
Medullary kinking	Kink of the medulla dorsal to the upper cervical spinal cord	Emery and MacKenzie [8]
Flattened pons	Thin stretched pons	El Gammal et al. [16]
Abnormal width fourth ventricle	Collapsed or dilated fourth ventricle	Wolpert et al. [15]
Hypoplastic tentorium	Underdeveloped tentorium with abnormally low insertion at the occipital bone	Peach [7] and Naidich et al. [11]
Abnormal course straight sinus	Abnormally short, steep course, or low insertion of the straight sinus	El Gammal et al. [16] and Just et al. [17]
Beaked tectum	Deformity of the quadrigeminal plate appearing like a pointed or bulbous mass	Peach [7] and Wolpert et al. [15]
Enlarged massa intermedia	Thick interthalamic adhesion	Peach [7] and Naidich et al. [13]
Stenogyria	Innumerable, closely spaced small gyri at the occipital cortex	Peach [7] and Wolpert et al. [15]
Axial plane		
Cerebellum in cervical spinal canal	Cerebellum below the top of the dens or the base of the occipital condyles	Variend and Emery [9]
Vermis in cervical spinal canal	Vermis below the top of the dens or the base of the occipital condyles	Variend and Emery [9]
Tonsil in cervical spinal canal	At least one tonsil below the top of the dens or the base of the occipital condyles	Variend and Emery [9]
Cerebellum wrapped around brainstem	Cerebellar hemispheres wrapped around brainstem into cerebellopontine angle cisterns	Peach [7] and Naidich et al. [12]
Abnormal fissural pattern of cerebellum	Abnormal fissural and lobular pattern of the superior surface of the cerebellum	Variend et al. [10]
Small fourth ventricle	Collapsed fourth ventricle	Wolpert et al. [15]
Enlarged fourth ventricle	Dilated fourth ventricle	Wolpert et al. [15]
Beaked tectum	Quadrigeminal plate is stretched appearing beaked	Peach [7] and Naidich et al. [12]
Enlarged massa intermedia	Thick interthalamic adhesion	Peach [7] and Naidich et al. [13]
Gyral interdigitation	Gyri crossing the interhemispheric fissure and folding in contralateral sulci	Peach [7] and Just et al. [17]
Stenogyria	Innumerable, closely spaced small gyri at the occipital cortex	Peach [7] and Wolpert et al. [15]
Coronal plane		
Downward herniation cerebellum	Cerebellum below the base of the occipital condyles	Variend and Emery [9]
Downward herniation vermis	Vermis below the base of the occipital condyles	Variend and Emery [9]
Downward herniation tonsil	At least one tonsil below the base of the occipital condyles	Variend and Emery [9]
Upward herniation cerebellum	Upward bulging of the cerebellum [towering] through a wide tentorial incisura	Peach [7] and Wolpert et al. [15]
Indentation	Indentation of the cerebellum by the edge of the tentorium	Peach [7] and Naidich et al. [12]
Hypoplastic tentorium	Short tentorial leaves with a wide tentorial incisura	Peach [7] and Naidich et al. [11]
Gyral interdigitation	Gyri crossing interhemispheric fissure and folding in contralateral sulci	Peach [7] and Just et al. [17]

Therefore, we initiated a study to investigate the interobserver reliability of morphological features of the Chiari II malformation on MR images. The purpose of this study was to select those features among the abundance of features that are essential for the diagnosis of the malformation, hypothesizing that several features would be too unreliable to adequately characterize Chiari II malformation.

Material and methods

Patients

Brain MR images of 79 children (mean age 10.6 [SD 3.2; range 6 to16] years) were evaluated. Of these children, 26 had open spinal dysraphism, while 17 children had closed spinal dysraphism (13 with lipomyelomeningocele and four children with other types of closed spinal dysraphism). The children with open spinal dysraphism were presumed to have Chiari II malformation [2], while children with closed spinal dysraphism might have some features of hindbrain herniation according to the literature [24,25]. The latter group was included to reduce context bias [26]. The majority of these children with spinal dysraphism (n =36) were recruited at the Outpatient Clinics of Pediatric Neurology of the Radboud University Nijmegen Medical Centre (RUNMC) as part of a prospective research program dedicated to outcome and prognosis of spina bifida. MR images of the remaining seven children were obtained retrospectively from the archives of the Department of Radiology of the RUNMC, from which we also obtained MR images of 36 children without spinal dysraphism, who were presumed to have no cerebral pathology. Although MR imaging in these 36 children was performed with suspicion of or to rule out cerebral pathology, the images had been assessed as normal by an independent radiologist in a clinical setting before the start of the study.

MR imaging

All MR images were acquired using a 1.5 T MR imaging unit (Siemens Avanto; Siemens Medical Solutions, Erlangen, Germany) with a standard head coil. MR imaging in the 36 children who were part of the prospective research program consisted of T1-weigthed images in the sagittal plane and T2-weigthed images in the axial and coronal plane. The retrospectively obtained MR images were acquired using comparable sequences. For different reasons, MR images were not acquired in three planes for all 79 children. Images in the sagittal plane were available for 69 children (41 with spinal dysraphism), images in the axial plane for 58 children (32 with spinal dysraphism), and images in the coronal plane for 51 children (37 with spinal dysraphism).

The Regional Committee on Research involving Human Subjects approved the study protocol. Prior to inclusion in the study, written informed consent was obtained from the parents of all 36 children and all children above 12 years of age taking part in the prospective research program.

Image analysis

All MR images were blinded for demographic and diagnostic information. The MR images were mixed and arranged by plane into three data sets: a sagittal set, an axial set, and a coronal set. These three data sets were reviewed consecutively and independently by three observers: a junior pediatric neurologist (N.G.) with 6 years of experience in reviewing pediatric brain MR images, a senior pediatric neurologist (R.A.M.), and a senior neuroradiologist (T.V.), both with more than 20 years of experience in reviewing pediatric brain MR images. A few weeks separated the reviews of the three datasets to prevent bias by recognition of images from a former set as much as possible. The images were available on compact disks and were reviewed on an Agfa workstation or on a personal computer using Agfa software (Impax Client, release 4.5).

The morphological features of Chiari II malformation to be assessed were selected from the literature and incorporated in a review protocol (Table 1). First, the feasibility of the protocol was evaluated in a pilot study (n = 10), resulting in a final set of study features with their definitions. The observers rated all features as being present, absent, or indefinable.

Statistical analysis

For each feature, the ‘present’, ‘absent’, and ‘indefinable’ ratings were tallied up per observer. First, the ‘indefinable’ ratings were evaluated to assess the applicability of each feature. If two or three observers rated a feature as indefinable in more than 5% of the MR images, it was qualified as non-applicable and subsequently excluded from the further analyses.

Interobserver agreement analyses were performed for the applicable features using only the ‘present’ and ‘absent’ ratings. The percentages of agreement were obtained from contingency tables. Based on these tables, κ values for multiple observers were calculated to measure the extent of agreement among the three observers [27]. To comprehend possible sources of disagreement, κ values were also calculated for pairs of observers. We considered a feature reliable when the κ value was above 0.8, which denotes almost perfect agreement [28]. The analyses were performed using SAS software version 8.2 (SAS Institute).

Results

For each feature, the percentages of 'present' and 'indefinable' ratings are summarized per observer in Table 2. All observers rated most features in the sagittal plane as present in 20-35% of the MR images, whereas the percentages of 'present' ratings in the axial and coronal planes varied substantially among features and among observers. In general, observer C rated features as 'present' less often than the other two observers did, whereas observer B rated features as 'indefinable' more often than the other two observers did. In the sagittal plane, all but one feature (*Stenogyria)* turned out to be applicable. In contrast, in the axial and coronal plane more than half of the features turned out to be non-applicable (Table 2). One observer rated *Enlarged massa intermedia* in the axial plane as indefinable in all but one MR image. The ratings of features in children with open or closed spinal dysraphism or without spinal dysraphism are presented in Table 3. With a few exceptions, features were quite common in children with open spinal dysraphism and hardly seen in the other children.

Table 2 Proportions of 'present' and 'indefinable' ratings per observer for each feature of Chiari II malformation

Feature	Present			Indefinable			Non-applicable[a]
	A	B	C	A	B	C	
Sagittal plane							
Downward herniation cerebellum	35	33	35	-	-	-	
Downward herniation vermis	25	28	35	3	3	-	
Downward herniation tonsil	33	30	26	1	1	6	
Upward herniation cerebellum	13	17	6	-	6	3	
Downward displacement medulla	30	26	20	-	-	3	
Downward displacement pons	26	26	13	-	3	3	
Downward displacement fourth ventricle	25	23	20	-	4	1	
Medullary kinking	17	14	14	1	1	6	
Flattened pons	25	38	23	-	-	-	
Abnormal width fourth ventricle	25[b]	25	29[b]	-	-	1	
Hypoplastic tentorium	26	22	22	-	13	3	
Abnormal course straight sinus	23	23	29	9	4	3	
Beaked tectum	25	28	23	-	-	-	

Table 2 Continued

Feature	Present			Indefinable			Non-applicable[a]
	A	B	C	A	B	C	
Enlarged massa intermedia	43	62	10	-	-	4	
Stenogyria	19	7	9	3	22	12	+
Axial plane							
Cerebellum in cervical spinal canal	21	21	19	10	19	12	+
Vermis in cervical spinal canal	2	2	14	26	36	16	+
Tonsil in cervical spinal canal	7	5	16	24	34	16	+
Cerebellum wrapped around brainstem	29	24	3	-	5	2	
Abnormal fissural pattern of cerebellum	29	59	47	7	7	5	+
Small fourth ventricle	26	28	26	-	3	-	
Enlarged fourth ventricle	3	2	3	-	9	-	
Beaked tectum	19	26	19	7	7	7	+
Enlarged massa intermedia	17	12	-	-	3	98	+
Gyral interdigitation	22	31	17	5	7	5	+
Stenogyria	17	9	7	7	91	12	+
Coronal plane							
Downward herniation cerebellum	35	26	24	8	8	4	+
Downward herniation vermis	10	69	14	18	31	6	+
Downward herniation tonsil	35	24	24	8	10	2	+
Upward herniation cerebellum	26	12	8	2	6	6	+
Indentation	12	12	6	2	4	-	
Hypoplastic tentorium	26	2	14	4	61	2	
Gyral interdigitation	18	26	14	2	10	4	

Data are percentages
[a] At least two observers considered the feature as indefinable in more than 5% of the MR images
[b] All abnormally small fourth ventricles, except for one dilated fourth ventricle
A, observer A; B, observer B; C, observer C

The interobserver agreement of the applicable features is presented in Table 4. The right panel of the table shows the percentages of agreement and disagreement, while the left panel shows the κ values. The interobserver agreement among all three observers was almost perfect (κ value > 0.8) for the following features in

Table 3 Features of Chiari II malformation present on MR images in children with open or closed spinal dysraphism or without spinal dysraphism

Feature	Spinal dysraphism		No spinal dysraphism
	Open	Closed	
Sagittal plane (n=207)	(%[a])	(%[a])	(%[a])
Downward herniation cerebellum	83	16	4
Downward herniation vermis	74	10	2
Downward herniation tonsil	75	14	1
Upward herniation cerebellum	33	2	-
Downward displacement medulla	68	8	-
Downward displacement pons	61	2	-
Downward displacement fourth ventricle	64	2	-
Medullary kinking	40	6	-
Flattened pons	75	2	-
Abnormal width fourth ventricle	74	2	-
Hypoplastic tentorium	67	-	-
Abnormal course straight sinus	71	-	7
Beaked tectum	72	-	-
Enlarged massa intermedia	36	35	43
Stenogyria	32	2	-
Axial plane (n=174)			
Cerebellum in cervical spinal canal	47	7	3
Vermis in cervical spinal canal	15	-	-
Tonsil in cervical spinal canal	24	-	-
Cerebellum wrapped around brainstem	50	-	-
Abnormal fissural pattern of cerebellum	68	43	26
Small fourth ventricle	68	3	-
Enlarged fourth ventricle	8	-	-
Beaked tectum	56	-	-
Enlarged massa intermedia	23	-	3
Gyral interdigitation	56	7	3
Stenogyria	21	-	-

Table 3 Continued

Feature	Spinal dysraphism		No spinal dysraphism
	Open	Closed	
Coronal plane (n=153)			
Downward herniation cerebellum	67	6	-
Downward herniation vermis	65	6	-
Downward herniation tonsil	20	-	-
Upward herniation cerebellum	38	-	-
Indentation	25	-	-
Hypoplastic tentorium	35	-	-
Gyral interdigitation	38	12	-

[a] The numbers represent percentages of present ratings based on the overall ratings of three observers

the sagittal plane: *Downward herniation cerebellum*, *Downward herniation tonsil*, *Downward displacement medulla*, *Downward displacement fourth ventricle*, *Medullary kinking*, *Abnormal width fourth ventricle*, *Hypoplastic tentorium*, and *Beaked tectum* (Figure 1). Only one feature in the axial plane (*Small fourth ventricle*) showed almost perfect agreement, while none of the features in the coronal plane did. The overall κ values for the remaining features ranged from 0.50 (*Cerebellum wrapped around brainstem*) to 0.75 (*Downward displacement pons*), except for a very low κ value for *Enlarged massa intermedia* (0.10). Table 4 also lists the κ values for pairs of observers. For seven features, the κ values differed substantially among pairs of observers: *Downward herniation vermis*, *Upward herniation cerebellum*, *Downward displacement pons*, and *Abnormal course straight sinus* in the sagittal plane; *Cerebellum wrapped around brainstem* in the axial plane; and *Indentation* and *Gyral interdigitation* in the coronal plane. In general, the agreement between observers A and B was stronger than the agreement of each of them with observer C.

Table 4 Overall and pairwise interobserver agreement of the applicable features of Chiari II malformation

Feature	κ value				Agreement (%)		Disagreement (%)	n
	Overall	Pairwise			All rated 'Present'	All rated 'Absent'		
		A - B	A - C	B - C				
Sagittal plane								
Downward herniation cerebellum	*0.85*	0.90	0.87	0.77	29	61	10	69
Downward herniation vermis	0.72	0.84	0.66	0.67	20	63	17	66
Downward herniation tonsil	*0.85*	0.85	0.89	0.80	24	67	9	64
Upward herniation cerebellum	0.56	0.66	0.57	0.42	5	82	13	63
Downward displacement medulla	*0.83*	0.88	0.83	0.78	19	72	9	65
Downward displacement pons	0.75	0.96	0.64	0.60	12	76	12	65
Downward displacement fourth ventricle	*0.84*	0.87	0.85	0.80	17	75	8	65
Medullary kinking	*0.88*	0.94	0.88	0.81	12	83	5	64
Flattened pons	0.70	0.70	0.72	0.67	19	62	19	69
Abnormal width fourth ventricle	*0.85*	0.92	0.81	0.81	21	70	9	67
Hypoplastic tentorium	*0.84*	0.86	0.76	0.91	19	73	8	60
Abnormal course straight sinus	0.73	0.85	0.61	0.75	17	71	12	55
Beaked tectum	*0.90*	0.92	0.88	0.89	22	72	6	69
Enlarged massa intermedia	0.10	0.27	0.00	0.03	4	26	70	66
Axial plane								
Cerebellum wrapped around brainstem	0.50	0.95	0.18	0.20	4	73	23	55
Small fourth ventricle	*0.85*	0.87	0.91	0.78	23	68	9	56
Enlarged fourth ventricle	-[a]	-[a]	-[a]	-[a]	2	98	0	53
Enlarged massa intermedia	-[a]	-[a]	-[a]	-[a]	0	100	0	1
Coronal plane								
Indentation	0.70	0.81	0.63	0.63	6	86	8	48
Hypoplastic tentorium	-[a]	-[a]	-[a]	-[a]	5	85	10	20
Gyral interdigitation	0.63	0.61	0.76	0.54	11	71	18	44

Overall κ value > 0.8 indicating almost perfect agreement are presented in italics
[a] κ value could not be calculated, because one or more counts were too small
A, observer A; B, observer B; C, observer C; n, number of ratings

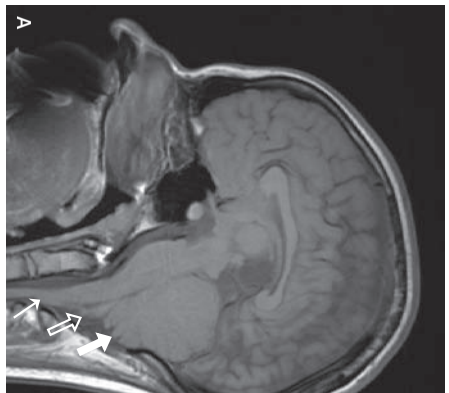

Figure 1 **A**. Sagittal T1-weighted brain MR image in 16-year-old child with open spinal dysraphism. The image shows herniation of the vermis (*large white arrow*), herniation of the tonsil (*large white open arrow*), and medullary kinking (*small white arrow*). **B**. Sagittal T1-weighted brain MR image in 12-year-old child with open spinal dysraphism. The image shows herniation of the cerebellum (*large white arrow*). The vermis and tonsil cannot be demarcated from each other. Note the beaked tectum (*small white arrow*) and the hypoplastic tentorium. Also, note the downward displacement of the medulla and pons and the small fourth ventricle in both images.

Discussion

On brain MR images, Chiari II malformation is generally assessed based on a constellation of morphological features. The current study reports on the reliability of these features leading to the identification of essential features that may improve consensus on the diagnosis of Chiari II malformation.

In this study, reliable features were distinguished from unreliable features, with reliable features predominantly being found in the sagittal plane. This in itself is not surprising, as most of the morphological abnormalities are best shown in the midsagittal plane, which is usually used to assess Chiari II malformation. Still, a substantial number of features in the sagittal plane (six out of 14) showed less than perfect or poor reliability and most features in the axial and coronal plane were non-applicable. These results support our assumption that the MR interpretation of Chiari II malformation is not always straightforward. The unreliability of features may be explained by their qualitative nature

and the fact that the distinction between normal and abnormal brain development is not defined by an unambiguous cutoff point. Judgment of the features is further complicated by the morphological diversity of the malformation and the fact that MR images capture features to various degrees. These general explanations mainly apply to features with random disagreement, that is to say, when the overall κ value and all pairwise κ values are low (e.g., *Upward herniation cerebellum*, *Flattened pons*, and *Gyral interdigitation*; Table 4).

On the other hand, the results for pairwise agreement showed systematic disagreement for some features; i.e., stronger agreement between observers A and B than the agreement for each of them with observer C. Perhaps, reappraisal of some definitions may further improve reliability, for instance, for *Cerebellum wrapped around brainstem* and *Indentation* (Figures 2 and 3).

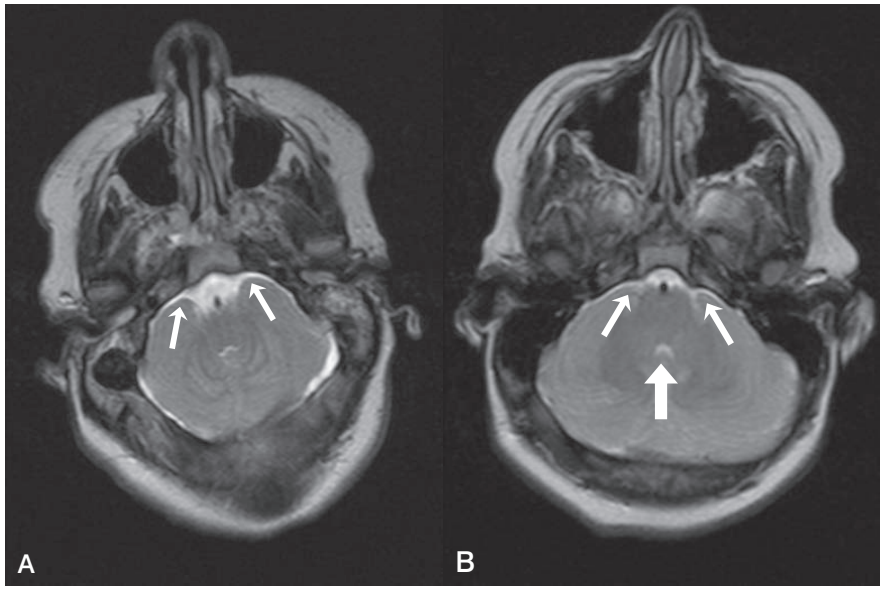

Figure 2 **A**. Axial T2-weighted brain MR image in 16-year-old child with open spinal dysraphism. The image clearly shows that the cerebellar hemispheres are wrapped around the brainstem (*small white arrows*). **B**. Axial T2-weighted brain MR image in 12-year-old child with open spinal dysraphism. In this image, it is questionable whether the cerebellar hemispheres are wrapped around the brainstem (*small white arrows*). Also note the small fourth ventricle (*large white arrow*).

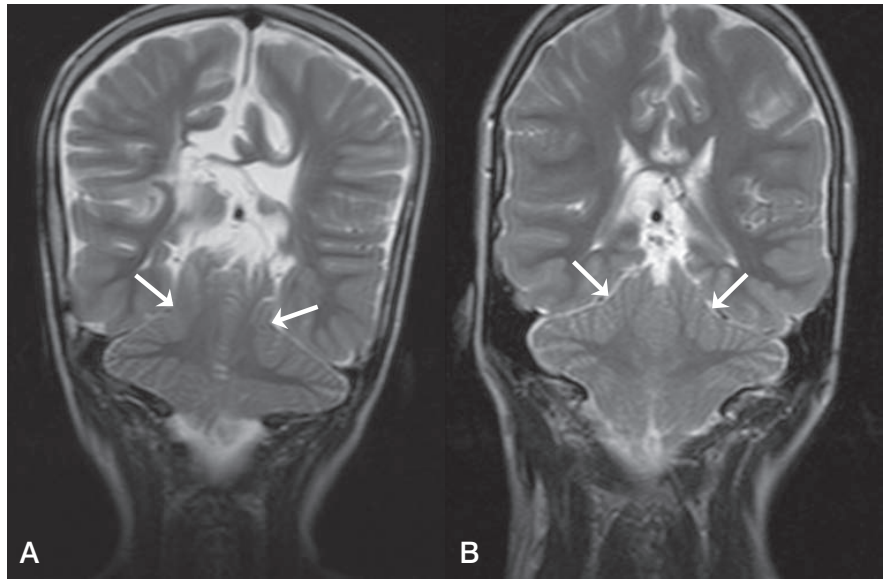

Figure 3 **A**. Coronal T2-weighted brain MR image in 9-year-old child with open spinal dysraphism. The image clearly shows that the tentorium indents the cerebellar hemispheres (*white arrows*); **B**. Coronal T2-weighted brain MR image in 12-year-old child with open spinal dysraphism. In this image, it is questionable whether the tentorium indents the cerebellar hemispheres (*white arrows*).

The systematic disagreement for *Downward herniation vermis* is of special interest. Blurred cerebellar contours in a crowded posterior fossa and partial volume effects may hamper precise demarcation of the vermis and may make it difficult to distinguish the vermis from the tonsil and from medullary kinking (Figure 1). This is in agreement with previous studies that reported that the vermis could not be clearly delineated in about 50% of children with Chiari II malformation [15,16]. On the other hand, systematic disagreement may have resulted from different concepts about the morphology of Chiari II malformation. Observer C, in contrast to the other two observers, considered *Downward herniation vermis* to be present more often than *Downward herniation tonsil* (Table 2). Yet, from post-mortem studies, it is known that herniation of the vermis without herniation of the tonsils does not occur [9]. Therefore, we recommend to assess downward herniation of the cerebellum irrespective of this being herniation of the vermis or herniation of the tonsils.

One of the limitations of this study was the possibility of context bias, i.e., knowledge from other sources that exaggerated interobserver agreement [26]. To deal with this phenomenon, we mixed the images expected to show Chiari II malformation with images expected to be without abnormalities and with images in which some features of hindbrain herniation could be present. However, observers may have tended to rate a feature according to the general appearance of the cerebellum, as complete blinding of each solitary feature was impossible. Another potential source of bias was the ratio between present and absent ratings as excess of one of the two affects the κ value [29]. In the current study, the proportion of present ratings per feature generally ranged from 25 to 35% (Table 2). Within this small range, κ values can be safely compared among features. Yet, a few features were rated as present in considerably lower proportions. As the κ value will underestimate agreement in case of low proportions [29], reliability of the features in question may be better than expected from the actual κ values. Furthermore, response bias may have decreased κ values [29,30]. This is particularly relevant when a rating is ambiguous. Although the observers had the opportunity to rate ambiguous features as indefinable, response bias was not completely avoided, since observers A and B generally rated features more often as present than observer C. As this was clearly the case for *Downward displacement pons* and the κ value was just below the cutoff point of 0.8, underestimation of agreement may be relevant for this feature. Potential institutional bias may be another limitation of the study. All observers worked at the same academic hospital, which might have increased agreement. However, the observers differed in terms of experience and educational and professional background. These differences might have reduced the interobserver agreement. On the other hand, the participation of senior and junior specialists with different backgrounds implies that the results are particularly useful for radiologist and other specialists who might be less familiar with reviewing brain MR images.

Nevertheless, this study showed that among all features that are evaluated while diagnosing Chiari II malformation, only a subset seems to be reliable. Although the Chiari II malformation seems to be a clear entity, clinicians and researchers should be aware of the different interpretations of its features among observers. The use of reliable features may facilitate plain communication about Chiari II malformation in clinical and research settings. In the management of individual patients, decisions about treatment options should be based on clinical signs and symptoms in combination with reliable MR findings. Although Chiari II malformation is almost uniquely associated with open spinal dysraphism, there might be exceptions. In such cases, the reliable features presented might be useful. In discussions on prenatal surgery and postnatal

selective treatment of spina bifida, this study provides clinicians and researchers with features that unambiguously describe the Chiari II malformation.

In addition to the qualitative method, a morphometric approach quantifying the morphological distortions may be helpful to overcome the problems of unreliable features. Morphometric measures are less subjective and may be less liable to interobserver variability. They may also provide cutoff points that distinguish between normal and abnormal brain development. The reliability and diagnostic performance of morphometric measures is subject of the second part of our study on the MR assessment of Chiari II malformation.

In conclusion, the following morphological features can reliably be used to assess Chiari II malformation on MR images: downward herniation of the cerebellum, downward displacement of the medulla, pons, and fourth ventricle, medullary kinking, abnormally shaped fourth ventricle, hypoplastic tentorium, and beaked mesencephalic tectum. The use of these essential features may improve the MR assessment of Chiari II malformation by providing a solid basis for consensus on the diagnosis.

References

1. Barkovich AJ. Congenital malformations of the brain and skull. In: Barkovich AJ, ed. *Pediatric Neuroimaging*. 4th ed. Philadelphia: Lippincott Williams & Wilkins, 2005: 374-384.
2. Chiari H. Ueber veränderungen des kleinhirns infolge von hydrocephalie des grosshirns. *Deut Med Wochenschr* 1891; 17:1172-1175.
3. McLone DG, Knepper PA. The cause of Chiari II malformation: a unified theory. *Pediatr Neurosci* 1989; 15:1-12.
4. Stevenson KL. Chiari type II malformation: past, present, and future. *Neurosurg Focus* 2004; 16:E5.
5. McLone DG. Continuing concepts in the management of spina bifida. *Pediatr Neurosurg* 1992; 18:254-256.
6. Oakeshott P, Hunt GM. Long-term outcome in open spina bifida. *Br J Gen Pract* 2003; 53:632-636.
7. Peach B. Arnold-Chiari malformation: Anatomic features of 20 cases. *Arch Neurol* 1965; 12:613-621.
8. Emery JL, MacKenzie N. Medullo-cervical dislocation deformity (Chiari II deformity) related to neurospinal dysraphism (meningomyelocele). *Brain* 1973; 96:155-162.
9. Variend S, Emery JL. Cervical dislocation of the cerebellum in children with meningomyelocele. *Teratology* 1976; 13:281-289.
10. Variend S, Emery JL. The superior surface lesion of the cerebellum in children with myelomeningocele. *Z Kinderchir* 1979; 28:328-335.
11. Naidich TP, Pudlowski RM, Naidich JB, Gornish M, Rodriguez FJ. Computed tomographic signs of the Chiari II malformation. Part I: Skull and dural partitions. *Radiology* 1980; 134:65-71.
12. Naidich TP, Pudlowski RM, Naidich JB. Computed tomographic signs of Chiari II malformation. II: Midbrain and cerebellum. *Radiology* 1980; 134:391-398.
13. Naidich TP, Pudlowski RM, Naidich JB. Computed tomographic signs of the Chiari II malformation. III: Ventricles and cisterns. *Radiology* 1980; 134:657-663.
14. Naidich TP, McLone DG, Fulling KH. The Chiari II malformation: Part IV. The hindbrain deformity. *Neuroradiology* 1983; 25:179-197.
15. Wolpert SM, Anderson M, Scott RM, Kwan ES, Runge VM. Chiari II malformation: MR imaging evaluation. *AJR Am J Roentgenol* 1987; 149:1033-1042.
16. El Gammal T, Mark EK, Brooks BS. MR imaging of Chiari II malformation. *AJR Am J Roentgenol* 1988; 150:163-170.
17. Just M, Schwarz M, Ludwig B, Ermert J, Thelen M. Cerebral and spinal MR-findings in patients with postrepair myelomeningocele. *Pediatr Radiol* 1990; 20:262-266.
18. Kawamura T, Morioka T, Nishio S, Mihara F, Fukui M. Cerebral abnormalities in lumbosacral neural tube closure defect: MR imaging evaluation. *Childs Nerv Syst* 2001; 17:405-410.
19. Miller E, Widjaja E, Blaser S, Dennis M, Raybaud C. The old and the new: supratentorial MR findings in Chiari II malformation. *Childs Nerv Syst* 2008; 24:563-575.
20. Mitchell LE, Adzick NS, Melchionne J, Pasquariello PS, Sutton LN, Whitehead AS. Spina bifida. *Lancet* 2004; 364:1885-1895.
21. Barry S. Quality of life and myelomeningocele: an ethical and evidence-based analysis of the Groningen Protocol. *Pediatr Neurosurg* 2010; 46:409-414.
22. Adzick NS, Thom EA, Spong CY, et al. A randomized trial of prenatal versus postnatal repair of myelomeningocele. *N Engl J Med* 2011; 364:993-1004.
23. Mangels KJ, Tulipan N, Tsao LY, Alarcon J, Bruner JP. Fetal MRI in the evaluation of intrauterine myelomeningocele. *Pediatr Neurosurg* 2000; 32:124-131.
24. Tubbs RS, Bui CJ, Rice WC, et al. Critical analysis of the Chiari malformation type I found in children with lipomyelomeningocele. *J Neurosurg* 2007; 106:196-200.
25. Milhorat TH, Bolognese PA, Nishikawa M, et al. Association of Chiari malformation type I and tethered cord syndrome: preliminary results of sectioning filum terminale. *Surg Neurol* 2009; 72:20-35.
26. Egglin TK, Feinstein AR. Context bias. A problem in diagnostic radiology. *JAMA* 1996; 276:1752-1755.
27. Fleiss JL, Levin B, Paik MC. The measurement of interrater agreement. In: Shewart WA, Wilks SS, eds. *Statistical methods for rates and proportions*. 3rd ed. New York: Wiley, 2003: 598-626.
28. Landis JR, Koch GG. The measurement of observer agreement for categorical data. *Biometrics* 1977; 33:159-174.
29. Ker M. Issues in the use of kappa. *Invest Radiol* 1991; 26:78-83.
30. Hoehler FK. Bias and prevalence effects on kappa viewed in terms of sensitivity and specificity. *J Clin Epidemiol* 2000; 53:499-503.

8

Interobserver reliability and diagnostic performance of Chiari II malformation measures in MR imaging

Niels Geerdink
Ton van der Vliet
Jan J. Rotteveel
Ton Feuth
Nel Roeleveld
Reinier A. Mullaart

Child's Nervous System 2012; 28:987-995

Abstract

Purpose Brain MR imaging is essential in the assessment of Chiari II malformation in clinical and research settings concerning spina bifida. However, the interpretation of MR images of the malformation is not always straightforward. Morphometric analyses of the extent of Chiari II malformation may improve the assessment. In an attempt to select appropriate morphometric measures for this purpose, we investigated the interobserver reliability and diagnostic performance of several morphometric measures of Chiari II malformation on MR images.

Methods Brain MR images of 79 children (26 with open spinal dysraphism, 17 with closed spinal dysraphism, and 36 without spinal dysraphism; mean age 10.6 [SD 3.2; range 6 to 16] years) were evaluated. All children had been assessed for Chiari II malformation (defined as cerebellar herniation in combination with open spinal dysraphism; n = 23). Three observers blindly and independently reviewed the MR images for 21 measures of the cerebellum, brainstem, and posterior fossa in three planes. The interobserver reliability was assessed by an agreement index (AI = 1 − RRE) and the diagnostic performance by receiver operating characteristic analyses.

Results Reliability was good for most measures, except for the degree of herniation of the vermis and tonsils. Most values differed statistically significantly between children with Chiari II malformation and children without Chiari II malformation. The measures *Mamillopontine distance* and *Cerebellar width* showed excellent diagnostic performance.

Conclusions Morphometric measures reliably quantify the morphological distortions of Chiari II malformation on MR images and may provide additional tools to assess the severity of Chiari II malformation in clinical and research settings.

Introduction

Chiari II malformation is a complex developmental malformation of the central nervous system. It is characterized by a small posterior fossa and downward displacement of the cerebellum and brainstem through an enlarged foramen magnum (hindbrain herniation) [1]. Chiari II malformation is almost uniquely associated with open spinal dysraphism [2]. McLone and Knepper [3] hypothesized that leakage of cerebrospinal fluid through the spinal anomaly reduces the distention of the embryonic ventricular system. The decreased inductive pressure on the surrounding mesenchyme results in an abnormally small posterior fossa. Approximately one third of the patients with Chiari II malformation develop signs and symptoms of brainstem compression [4]. The mortality in this symptomatic group is 15 to 35% [5,6].

Usually, Chiari II malformation is clinically diagnosed with the help of MR imaging to assess its severity. Although the malformation is characterized by a constellation of morphological features [7-11], the evaluation of MR images may not always be straightforward. A previous study showed that the assessment of several features is unreliable, because judgment of these features varied between observers (see Chapter 7). Assessment of MR images is complicated by the morphological diversity of the malformation, the qualitative nature of the features, and the fact that the distinction between normal and abnormal brain development is not defined by an unambiguous cutoff point.

Still, brain MR imaging plays a substantial role in clinical decision making regarding the management of children with spina bifida [9,10,12]. On the one hand, the discussion on selective treatment of severely affected newborn infants is still ongoing [13]. On the other hand, fetal imaging and prenatal surgery are becoming more important every day. Recently, a randomized trial showed important improvement of hindbrain herniation following prenatal surgery for spina bifida [14]. However, the assessment of Chiari II malformation may be even more complicated in prenatal MR imaging. A discrepancy of 41% was seen in judgment of the degree of hindbrain herniation in prenatal MR imaging studies [15]. When choices have to be made about prenatal and postnatal treatment options, morphometric analyses may improve the assessment of the severity of Chiari II malformation in clinical and research settings. Measurements of the cerebellum, brainstem, and posterior fossa may give quantitative information about the extent of the malformation and may provide objective cutoff points between normal and abnormal brain development. A few morphometric studies on Chiari II malformation have been reported [16-21]. These studies generally focused on the small posterior fossa and the degree of cerebellar herniation in the midsagittal plane, but not on dimensions in the axial or coronal plane.

Interobserver reliability and diagnostic performance of such morphometric measures are hardly addressed in the literature.

Therefore, we investigated the interobserver reliability and diagnostic performance of morphometric measures of the cerebellum, brainstem, and posterior fossa, not only in the midsagittal plane, but also in the axial and coronal plane, to select appropriate measures for the MR assessment of Chiari II malformation.

Materials and methods

Patients

Brain MR images of 79 children (mean age 10.6 [SD 3.2; range 6 to 16] years) were evaluated. Of these children, 43 children had spinal dysraphism (26 with open spinal dysraphism and 17 with closed spinal dysraphism [22]). The majority of these children (n = 36) were recruited at the Outpatient Clinics of Pediatric Neurology of the Radboud University Nijmegen Medical Centre (RUNMC) as part of a prospective research program dedicated to the outcome and prognosis of spina bifida. MR images of the remaining seven children were obtained retrospectively from the archives of the Department of Radiology of the RUNMC, from which we also obtained brain MR images of 36 children without spinal dysraphism. Although MR imaging in these 36 children was performed with suspicion of or to rule out cerebral pathology, the MR images had been assessed as normal by an independent radiologist in a clinical setting before the start of the study. All 79 children were reassessed for Chiari II malformation using the criteria: cerebellar herniation on a sagittal MR image and the presence of open spinal dysraphism. Consequently, the study population consisted of three diagnostic groups: 23 children with spinal dysraphism and Chiari II malformation (SDCM+ group; mean age 11.4 [SD 2.9; range 6 to 16] years), 20 children with spinal dysraphism, but without Chiari II malformation (SDCM− group; mean age 10.9 [SD 3.1; range 7 to 16] years), and 36 children without spinal dysraphism or cerebral pathology (reference group; mean age 9.9 [SD 3.2; range 6 to16] years).

MR imaging

All MR images were acquired using a 1.5 T MR imaging unit (Siemens Avanto; Siemens Medical Solutions, Erlangen, Germany) with a standard head coil. MR imaging in the 36 children who were part of the prospective research program consisted of T1-weigthed images in the sagittal plane and T2-weigthed images in the axial and coronal plane. The retrospectively obtained MR images were acquired using comparable sequences. For different reasons, MR images were not

acquired in three planes for all 79 children. Images in the sagittal plane were available for 69 children (21 in the SDCM+ group, 20 in the SDCM− group, and 28 in the reference group), images in the axial plane for 58 children (19 in the SDCM+ group, 13 in the SDCM− group, and 26 in the reference group), and images in the coronal plane for 51 children (18 in the SDCM+ group, 19 in the SDCM− group, and 14 in the reference group).

The Regional Committee on Research involving Human Subjects approved the study protocol. Prior to inclusion in the study, written informed consent was obtained from the parents of all 36 children and all children above 12 years of age taking part in the prospective research program.

Image analysis

All MR images were blinded for demographic and diagnostic information. The MR images of the three diagnostic groups were mixed and arranged by plane into three data sets: a sagittal set, an axial set, and a coronal set. These three data sets were reviewed independently by three observers: a junior pediatric neurologist (N.G.) with 6 years of experience in reviewing pediatric brain MR images, a senior pediatric neurologist (R.A.M.), and a senior neuroradiologist (T.V.), both with more than 20 years of experience in reviewing pediatric brain MR images. The images were available on compacts disks and were reviewed on an Agfa workstation or on a personal computer using Agfa software (Impax Client, release 4.5).

The MR images were reviewed for 13 sagittal, four axial, and four coronal morphometric measures (Table 1). Most of the measures in the sagittal plane were selected from the literature. The measures in the axial and coronal plane were defined by the authors to appraise the width of the cerebellum, the degree of wrapping of the cerebellar hemispheres around the brainstem, and the degree of upward tentorial herniation of the cerebellar hemispheres.

First, the feasibility of the protocol was evaluated in a pilot study (n = 10), resulting in the final set of measures with their definitions. Measures were assessed to the nearest decimal of a millimeter. If an observer could not identify a landmark or could not assess the measure for other reasons, the measurement was classified as ‘indeterminable’.

Statistical analysis

For each measure, the indeterminable measurements were tallied up per observer to assess the feasibility of each measure. If at least two observers considered a measure indeterminable in more than 5% of the MR images, the measure was qualified as unfeasible and subsequently excluded from the further analyses.

Table 1 Morphometric measures of Chiari II malformation

Measure	Definition	Reference
Sagittal plane[a]		
Foramen magnum diameter	Distance between basion and opisthion	Aboulezz et al. [16]
Vermis level	Distance perpendicular from the line between basion and opisthion, to the most caudal extent of the vermis[b]	Modified from Barkovich et al. [29]
Tonsil level	Distance perpendicular from the line between basion and opisthion, to the most caudal extent of the tonsil[b]	Barkovich et al. [29]
Kinking level	Distance perpendicular from the line between basion and opisthion, to the most caudal and dorsal border of the kink	Modified from Barkovich et al. [29]
Fourth ventricle level	Distance perpendicular from the line between basion and opisthion, to the fastigium of the fourth ventricle	Modified from Barkovich et al. [29]
Cerebellar height	Distance from the most rostral point of the cerebellum to the most caudal extent of the cerebellum	Salman et al. [21]
Vermis length	Sagittal distance from the fastigium of the fourth ventricle to the most dorsal part of the vermis	Salman et al. [21]
Medulla length	Distance from the superior pontine notch to the cervicomedullary junction	Nishikawa et al. [30]
Pons length	Distance from the superior pontine notch to the inferior pontine notch	Tsai et al. [20]
Pons thickness	Distance from the ventral side of the pons to the dorsal side of the medulla, perpendicular to the line representing the pons length, at the middle of this line	Modified from Barkovich [1]
Mamillopontine distance	Distance from the inferior border of the mamillary body to the superior bulge of the pons	El Gammal et al. [28]
Tentorial length[c]	Distance from the tentorial insertion at the cortex of the skull to the edge of the tentorium	
Cisterna magna width[c]	Distance from the opisthion to the vermis perpendicular to the line between opisthion and tentorial insertion	
Axial plane		
Cerebellar width[c]	Distance from the most lateral border of the right hemisphere to the most lateral border of the left hemisphere, perpendicular to the midsagittal line, independent of the MR image slice level	
Hemispheral length[c] (left and right)	In the same slice as the Cerebellar width, distance from the most rostral border of the cerebellar hemisphere to the most posterior border of the cerebellar hemisphere, parallel to the midsagittal line	
Vermis length[c]	Maximal distance from anterior vermis border to posterior vermis border, independent of the MR image slice level	
Coronal plane		
Cerebellar width[c]	In the slice just posterior to the fourth ventricle, distance from the most lateral border of the right hemisphere to the most lateral border of the left hemisphere, perpendicular to the midsagittal line	
Hemispheral height[c] (left and right)	In the slice just posterior to the fourth ventricle, distance from the most cranial border of the cerebellar hemisphere to most caudal border of the cerebellar hemisphere, parallel to the midsagittal line	
Vermis length[c]	Distance from the most rostral vermis border to the most caudal vermis border, independent of the MR image slice level	

[a] All sagittal measurements were performed in the midsagittal plane
[b] If above the foramen magnum, provided with a positive sign, and if below the foramen magnum, with a negative sign
[c] Measure introduced in the present study

The interobserver agreement of the feasible measures was quantified by the agreement index (AI), defined as AI = 1 − RRE, where RRE denotes the relative random measurement error expressed as the pooled coefficient of variation across patients of the observations made by the three observers. This AI can be seen as an extension to more than two observers of the AI defined for two observations per patient [23,24]. The relative random measurement error was used instead of the absolute random measurement error in order to compare measures among each other. An AI ≥ 0.90 was considered to indicate reliable interobserver agreement. Using this method, the overall interobserver agreement, the interobserver agreement between pairs of observers, and the interobserver agreement per diagnostic group were calculated.

The reliable measures were also analyzed for diagnostic performance regarding Chiari II malformation. Initially, the measurements of observer A were used for this purpose. Differences between the three diagnostic groups were analyzed with the Kruskal-Wallis test. Using the diagnosis of Chiari II malformation (defined as cerebellar herniation on a sagittal MR image and presence of open spinal dysraphism) as the reference standard, a receiver operating characteristic (ROC) curve was constructed for each measure. The area under the ROC curve (AUC) and its 95% confidence interval (CI) were calculated to assess the diagnostic performance. The cutoff value with the optimal sensitivity and specificity was ascertained from the curve. Subsequently, the consistency of the measures with a high diagnostic performance (AUC > 0.90) was assessed using the measurements of the other two observers. All statistical analyses were performed using SPSS software version 14.0.1.

Results

Reliability

Most measures turned out to be feasible, except for *Fourth ventricle level* in the sagittal plane and *Vermis length* in the axial and coronal planes. These three measures were excluded from the further interobserver agreement and diagnostic performance analyses.

The interobserver agreement of the remaining measures is presented in Table 2. For most measures, the interobserver agreement was reliable (AI≥0.9), both overall and per diagnostic group. In general, the agreement was slightly weaker in the SDCM+ group than in the other two diagnostic groups, but this difference was only meaningful for *Tentorial length*. The agreement was very poor for *Vermis level*, *Tonsil level*, and *Cisterna magna width*. The interobserver agreement for pairs of observers showed that the poor agreement for *Cisterna magna width* and *Tonsil level* were not observer dependent. The poor agreement for *Vermis level*, however, was observer dependent (Table 3). For all other measures, pairwise agreement did not differ among pairs of observers.

Table 2 Agreement indexes[a] of morphometric measures overall and per diagnostic group

Measure	Overall	SDCM+	SDCM−	Reference group
Sagittal plane				
Foramen magnum diameter	*0.93*	0.91	0.97	0.94
Vermis level	0.06	-0.25	0.25	0.26
Tonsil level	0.20	0.38	0.41	0.36
Kinking level	*0.92*	0.93	-[b]	-[b]
Cerebellar height	*0.92*	0.87	0.97	0.98
Vermis length	*0.93*	0.93	0.92	0.94
Medulla length	*0.92*	0.90	0.93	0.93
Pons length	*0.94*	0.91	0.96	0.98
Pons thickness	*0.95*	0.93	0.97	0.95
Mamillopontine distance	*0.91*	0.94	0.90	0.89
Tentorial length	0.88	0.76	0.92	0.92
Cisterna magna width	0.40	-1.57	0.48	0.54
Axial plane				
Cerebellar width	*0.93*	0.86	0.98	0.98
Hemispheral length left	0.88	0.87	0.87	0.91
Hemispheral length right	0.89	0.89	0.89	0.90
Coronal plane				
Cerebellar width	*0.98*	0.98	0.99	0.99
Hemispheral height left	*0.91*	0.89	0.92	0.91
Hemispheral height right	*0.90*	0.91	0.90	0.92

Overall agreement indexes ≥0.90 are indicated in italics
[a] Calculated as 1 − RRE; for further details, see section materials and methods
[b] Kinking was not present in the SDCM− group and in the reference group
SDCM+, spinal dysraphism with Chiari II malformation; SDCM−, spinal dysraphism without Chiari II malformation

Table 3 Agreement indexes[a] of three measures with poor interobserver agreement, overall and by observer pair

Measure	Overall	Observer pairs		
		A-B	A-C	B-C
Vermis level	0.06	0.69	-0.12	-0.19
Tonsil level	0.20	0.33	0.15	0.10
Cisterna magna width	0.40	0.39	0.41	0.39

[a] Calculated as 1 − RRE; for further details, see section materials and methods
A, observer A; B, observer B; C, observer C

Diagnostic performance

In the sagittal and axial plane, all but one measure differed statistically significantly between the SDCM+ group and the other two diagnostic groups (Table 4). In the coronal plane, only *Cerebellar width* was statistically significantly smaller in the SDCM+ group than in the other two groups. No differences were present between the SDCM− group and the reference group.

The diagnostic performance of the measures based on the data from observer A is presented in Table 5 and illustrated by ROC curves in Figure 1. The AUC was substantial (>0.90) for five measures: *Foramen magnum diameter*, *Pons length*, *Pons thickness*, and *Mamillopontine distance* in the sagittal plane (Figure 2), and *Cerebellar width* in the axial plane (Figure 3), but sensitivity and specificity was not all that high for *Pons length* and *Pons thickness*, respectively. Consistency of the performance of these five measures was evaluated using the measurement values of observers B and C (Table 6). In this analysis, only *Mamillopontine distance* and *Cerebellar width* maintained their excellent diagnostic performance. Despite the high sensitivity and specificity in the primary analysis, *Foramen magnum diameter* failed to the consistency test.

Table 4 Measurements (mean values in cm) by diagnostic group[a]

Measure	SDCM+		SDCM−	Reference group		P-value[b]
Sagittal plane						
Foramen magnum diameter	4.46	(4.35[16])[c]	3.62	3.64	(3.68[16])	<0.0001
Kinking level	-3.56		-[d]	-[d]		
Cerebellar height	6.94	(6.8[21])	5.84	5.68	(5.5[21])	<0.0001
Vermis length	3.60	(3.7[21])	3.00	2.91	(3.0[21])	<0.0001
Medulla length	6.03		5.55	5.41		<0.05
Pons length	3.27	(2.9[20])	2.59	2.56	(2.7[20])	<0.0001
Pons thickness	1.87		2.24	2.21		<0.0001
Mamillopontine distance	1.34		0.74	0.72		<0.0001
Axial plane						
Cerebellar width	8.01		10.22	10.30		<0.0001
Hemispheral length left	5.18		5.86	5.73		0.06
Hemispheral length right	5.09		5.71	5.76		<0.001
Coronal plane						
Cerebellar width	8.55		9.98	9.91		<0.001
Hemispheral height left	5.61		5.46	5.42		0.46
Hemispheral height right	5.46		5.40	5.50		0.77

[a] Data obtained from observer A
[b] P-values for differences between the three diagnostic groups based on the Kruskal-Wallis test
[c] Values between brackets are reference values from the literature
[d] Kinking was not present in the SDCM− group and in the reference group
SDCM+, spinal dysraphism with Chiari II malformation; SDCM−, spinal dysraphism without Chiari II malformation

Table 5 Results of ROC analyses showing the diagnostic performance of Chiari II malformation measures[a]

	AUC	95% CI	Sensitivity	Specificity	Cutoff value (cm)
Sagittal plane					
Foramen magnum diameter	0.97	0.93-1.01	0.90	0.96	3.94
Cerebellar height	0.87	0.76-0.98	0.85	0.90	6.31
Vermis length	0.88	0.76-0.99	0.88	0.88	3.19
Medulla length	0.72	0.56-0.87	0.50	0.94	6.07
Pons length	0.95	0.89-1.01	0.80	0.98	2.96
Pons thickness	0.93	0.88-0.99	0.95	0.75	2.14
Mamillopontine distance	0.94	0.86-1.03	0.90	1.00	1.05
Axial plane					
Cerebellar width	0.93	0.83-1.03	0.89	0.97	9.57
Hemispheral length left	0.68	0.51-0.85	0.53	0.90	5.22
Hemispheral length right	0.82	0.70-0.95	0.71	0.90	5.30
Coronal plane					
Cerebellar width	0.82	0.68-0.97	0.76	0.88	9.43
Hemispheral height left	0.52	0.34-0.69	0.18	0.94	6.04
Hemispheral height right	0.61	0.42-0.79	0.53	0.81	5.80

[a] Data obtained from observer A
AUC, area under the receiver operating characteristic (ROC) curve

Discussion

On brain MR images, Chiari II malformation is generally evaluated based on a constellation of morphological characteristics in the midsagittal plane. The current study provides quantitative measures that may provide information about the extent or severity of Chiari II malformation. The measures *Mamillopontine distance* and *Cerebellar width* seem to be highly specific and sensitive for assessing Chiari II malformation.

In the present study, most measures turned out to be reliable, both overall and per diagnostic group. The literature provides some morphometric studies of Chiari II malformation [16-21,25], but only the study of Salman et al. [21] deals with interobserver agreement of several measures. As far as the same measures

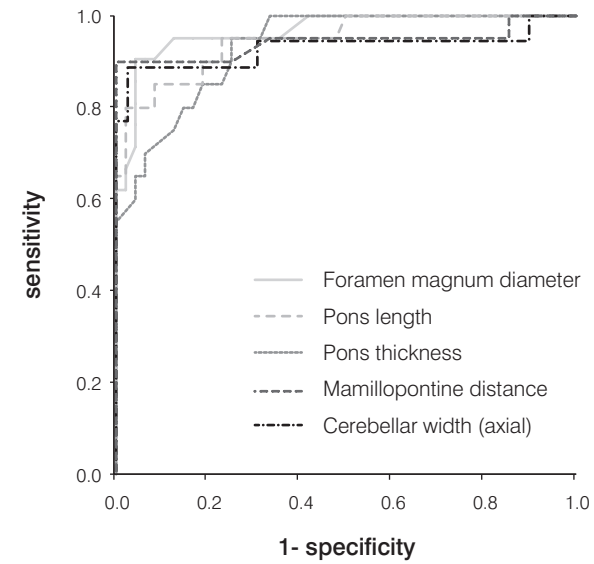

Figure 1 Receiver operating characteristic curves for measures with a good diagnostic performance (AUC > 0.90). See Table 5 for further details.

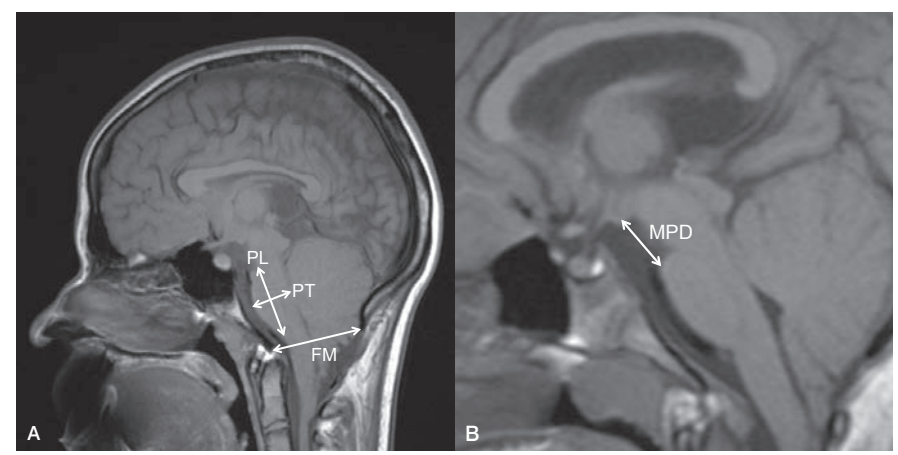

Figure 2 **A**. Sagittal T1-weighted brain MR image of a 16-year-old child with open spinal dysraphism and Chiari II malformation. The arrows indicate *Foramen magnum diameter* (FM), *Pons length* (PL), and *Pons thickness* (PT); **B**. Sagittal T1-weighted brain MR image of an 8-year-old child with open spinal dysraphism and Chiari II malformation. The arrow indicates *Mamillopontine distance* (MPD).

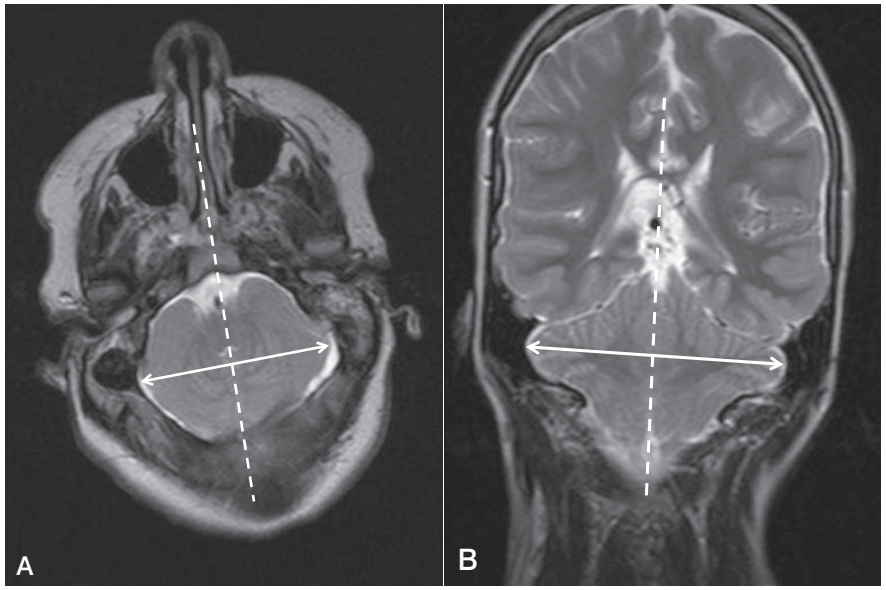

Figure 3 **A**. axial T2-weighted brain MR image of a 16-year-old child with open spinal dysraphism and Chiari II malformation. The arrow indicates axial *Cerebellar width;* **B**. Coronal T2-weighted brain MR image of a 13-year-old child with open spinal dysraphism and Chiari II malformation. The arrow indicates coronal *Cerebellar width*.

Table 6 Consistency[a] of the measures with the best diagnostic performance in the ROC analyses

Measure	Sensitivity	Specificity	Cutoff value (cm)
Foramen magnum diameter	0.69	0.79	3.94
Pons length	0.68	0.96	2.96
Pons thickness	0.93	0.59	2.14
Mamillopontine distance	0.84	0.97	1.05
Cerebellar width (axial plane)	0.89	0.92	9.57

[a] Tested by applying the results of the ROC analysis (see Table 5) to the data obtained from observer B and C

were studied, our results agree with the previous findings. The additional value of our study is that we investigated measures in three planes and in different diagnostic groups. The interobserver agreement in the Chiari II malformation group was slightly lower than in the unaffected groups. This may be due to anatomical distortions, which may hamper precise identification of landmarks. However, this did not affect reliability to a large extent.

Unreliable measures in the present study were predominantly complex measures, depending on reference lines, which are susceptible to differences in interpretation as well. For example, the disagreement found for *Foramen magnum diameter* will have contributed to the disagreement for the measures that depend on it, such as *Vermis level*.

The unreliability of *Vermis level* and *Tonsil level* was remarkable. Blurred boundaries in a crowed posterior fossa and upper cervical spinal canal may have hampered precise delineation of the tonsils and vermis. Consequently, these structures could not be distinguished precisely. On the other hand, the disagreement for *Vermis level* may also be observer dependent, as two of the three observers moderately agreed on *Vermis level*, whereas these two observers systematically disagreed with the third observer (Table 3). To elucidate this, we performed a post hoc analysis using the most caudal extent of cerebellar tissue (vermis or tonsil) as a variable. As this derivative measure also failed to be reliable (AI=0.29), however, observer dependency seems to play a minor role. In contrast, Salman et al. [21] presented a comparable measure 'herniation distance' as reliable, but they used other statistical methods in a smaller sample size. Although cerebellar herniation remains a key feature of Chiari II malformation and its morphological appearance can reliably be judged on MR images (see Chapter 7), the present study shows that measuring the degree of cerebellar herniation can be unreliable.

The majority of the reliable measures differed statistically significantly between children with Chiari II malformation and unaffected children (Table 4). These differences are in accordance with the morphogenesis of Chiari II malformation. Increased *Cerebellar height* and *Vermis length* and decreased *Cerebellar width* support the hypothesis of a small posterior fossa [3] with squeezing of the vermis and enlargement of the midsagittal vermis area [21]. An increased *Mamillopontine distance* results from caudal displacement of the brainstem and pons. For a few measures, reference values have been reported in the literature (Table 4). Our values for *Foramen magnum diameter* corresponded well with the values reported by Aboulezz et al. [16] and our values for *Cerebellar height* and *Vermis length* with the values reported by Salman et al. [21]. The *Pons length* in affected children in our study was longer than the *Pons length* reported by Tsai et al. [20]. A different identification of the inferior pontine notch and a different age range of the investigated population might explain this difference.

The substantial differences in the measurement values between affected and unaffected children warrant the search for cutoff points. The ROC analyses showed reasonably accurate cutoff points for more than half of the reliable measures (Table 5), but only two measures, *Mamillopontine distance* and *Cerebellar width*, showed consistent diagnostic performance. Some caution is justified, however. From the ROC analyses, very precise cutoff points were calculated, but this amount of precision will not be feasible in clinical practice.

Clinicians should be aware of the imprecise judgment of the degree of cerebellar herniation in the midsagittal plane. The reliable measures presented are more suitable to assess the morphological distortions. They appraise the cerebellum and brainstem, not only in the midsagittal plane, but also in the axial and coronal plane. Since measures differ substantially between affected and unaffected children, they are considered to be of diagnostic value. *Cerebellar width* provides an indication of the size of the posterior fossa, and *Cerebellar height* and *Vermis length* reflect the enlarged vermis area. *Mamillopontine distance, Pons length,* and *Medulla length* provide quantifications of downward displacement and stretching of the brainstem. Although *Hemispheral length* and *Hemispheral height* were reliable measures, they did not differ substantially between affected and unaffected children and thus failed to provide objective cutoff values for wrapping of the cerebellar hemispheres around the brainstem and upward tentorial herniation, respectively. The reliable measures might be suitable to assess severity of clinical signs and symptoms. However, the association between measurements and severity of Chiari II malformation is a matter of further study.

The results of this study may have implications for prenatal surgery for spina bifida as well. Intrauterine spina bifida repair appears to reverse the degree of hindbrain herniation [14,26,27]. The currently used scoring system might be imprecise, as it is based on the degree of vermis herniation and the position of the fourth ventricle. The present study provides reliable measures, which may be more suitable to objectively evaluate the effect of prenatal surgery on Chiari II malformation in three dimensions. However, the results may not simply be transformed to prenatal imaging, since unshunted hydrocephalus might have an effect on the measures in the prenatal setting. In particular, this may be relevant for *Mamillopontine distance*, as this distance may decrease as a result of raised intracranial pressure [28]. The effect of hydrocephalus may have less influence on most other measures. However, additional evaluation of the measures in a prenatal setting is recommended.

The study also had some limitations. Due to its partly retrospective design, the study population comprised a heterogeneous set of MR images. Furthermore, the reference standard used in the ROC analyses might be questionable. However,

a better reference standard is currently not available. Finally, we could not take into account a possible age effect even though brain dimensions change in a growing child. However, Salman et al. [21] showed that MR measurements of the posterior fossa did not correlate with age in children with Chiari II malformation. In the present study, the strong differences between affected and unaffected children seem to outweigh the influence of age.

In conclusion, using morphometric measures represent a reliable and feasible method to quantify the morphological distortions of Chiari II malformation on MR images. These measures are easily used on standard MR images without the need of specific software. They appraise different parts of the cerebellum, brainstem, and posterior fossa providing quantitative information about the extent of Chiari II malformation in three dimensions. The measures may have added value in assessment of severity of Chiari II malformation in clinical decision making as well as in research settings, such as studies on the effect of prenatal surgery for spina bifida. The excellent diagnostic performance of *Mamillopontine distance* and *Cerebellar width* makes these measures particularly helpful in cases in which the diagnosis of Chiari II malformation is ambiguous.

References

1. Barkovich AJ. Congenital malformations of the brain and skull. In: Barkovich AJ, ed. *Pediatric neuroimaging*. 4th ed. Philadelphia: Lippincott Williams & Wilkins, 2005: 374-384.
2. Chiari H. Ueber Veränderungen des Kleinhirns infolge von Hydrocephalie des Grosshirns. *Deut Med Wochenschr* 1891; 17:1172-1175.
3. McLone DG, Knepper PA. The cause of Chiari II malformation: a unified theory. *Pediatr Neurosci* 1989; 15:1-12.
4. Stevenson KL. Chiari type II malformation: past, present, and future. *Neurosurg Focus* 2004; 16:E5.
5. McLone DG. Continuing concepts in the management of spina bifida. *Pediatr Neurosurg* 1992; 18:254-256.
6. Oakeshott P, Hunt GM. Long-term outcome in open spina bifida. *Br J Gen Pract* 2003; 53:632-636.
7. Wolpert SM, Anderson M, Scott RM, Kwan ES, Runge VM. Chiari II malformation: MR imaging evaluation. *AJR Am J Roentgenol* 1987; 149:1033-1042.
8. El Gammal T, Mark EK, Brooks BS. MR imaging of Chiari II malformation. *AJR Am J Roentgenol* 1988; 150:163-170.
9. Just M, Schwarz M, Ludwig B, Ermert J, Thelen M. Cerebral and spinal MR-findings in patients with postrepair myelomeningocele. *Pediatr Radiol* 1990; 20:262-266.
10. Kawamura T, Morioka T, Nishio S, Mihara F, Fukui M. Cerebral abnormalities in lumbosacral neural tube closure defect: MR imaging evaluation. *Childs Nerv Syst* 2001; 17:405-410.
11. Miller E, Widjaja E, Blaser S, Dennis M, Raybaud C. The old and the new: supratentorial MR findings in Chiari II malformation. *Childs Nerv Syst* 2008; 24:563-575.
12. Mitchell LE, Adzick NS, Melchionne J, Pasquariello PS, Sutton LN, Whitehead AS. Spina bifida. *Lancet* 2004; 364:1885-1895.
13. Barry S. Quality of life and myelomeningocele: an ethical and evidence-based analysis of the Groningen Protocol. *Pediatr Neurosurg* 2010; 46:409-414.
14. Adzick NS, Thom EA, Spong CY, et al. A randomized trial of prenatal versus postnatal repair of myelomeningocele. *N Engl J Med* 2011; 364:993-1004.
15. Mangels KJ, Tulipan N, Tsao LY, Alarcon J, Bruner JP. Fetal MRI in the evaluation of intrauterine myelomeningocele. *Pediatr Neurosurg* 2000; 32:124-131.
16. Aboulezz AO, Sartor K, Geyer CA, Gado MH. Position of cerebellar tonsils in the normal population and in patients with Chiari malformation: a quantitative approach with MR imaging. *J Comput Assist Tomogr* 1985; 9:1033-1036.
17. Wolpert SM, Scott RM, Platenberg C, Runge VM. The clinical significance of hindbrain herniation and deformity as shown on MR images of patients with Chiari II malformation. *AJNR Am J Neuroradiol* 1988; 9:1075-1078.
18. Curnes JT, Oakes WJ, Boyko OB. MR imaging of hindbrain deformity in Chiari II patients with and without symptoms of brainstem compression. *AJNR Am J Neuroradiol* 1989; 10:293-302.
19. Ruge JR, Masciopinto J, Storrs BB, McLone DG. Anatomical progression of the Chiari II malformation. *Childs Nerv Syst* 1992: 8:86-91.
20. Tsai T, Bookstein FL, Levey E, Kinsman SL. Chiari II malformation: a biometric analysis. *Eur J Pediatr Surg* 2002; 12(Suppl.1):12-18.
21. Salman MS, Blaser SE, Sharpe JA, Dennis M. Cerebellar vermis morphology in children with spina bifida and Chiari type II malformation. *Childs Nerv Syst* 2006; 22:385-393.
22. Tortori-Donati P, Rossi A, Cama A. Spinal dysraphism: a review of neuroradiological features with embryological correlations and proposal for a new classification. *Neuroradiology* 2000; 42:471-491.
23. Filippi M, Horsfield MA, Bressi S, et al. Intra- and inter-observer agreement of brain MRI lesion volume measurements in multiple sclerosis. A comparison of techniques. *Brain* 1995; 118:1593-1600.
24. Joe BN, Fukui MB, Meltzer CC, et al. Brain tumor volume measurement: comparison of manual and semiautomated methods. *Radiology* 1999; 212:811-816.
25. Grant RA, Heuer GG, Carrion GM, et al. Morphometric analysis of posterior fossa after in utero myelomeningocele repair. *J Neurosurg Pediatr* 2011; 7:362-368.
26. Tulipan N, Hernanz-Schulman M, Bruner JP. Reduced hindbrain herniation after intrauterine myelomeningocele repair: A report of four cases. *Pediatr Neurosurg* 1998; 29:274-278.
27. Tulipan N, Hernanz-Schulman M, Lowe LH, Bruner JP. Intrauterine myelomeningocele repair reverses preexisting hindbrain herniation. *Pediatr Neurosurg* 1999; 31:137-142.
28. El Gammal T, Allen MB, Brooks BS, Mark EK. MR evaluation of hydrocephalus. *AJR Am J Roentgenol* 1987; 149:807-813.
29. Barkovich AJ, Wippold FJ, Sherman JL, Citrin CM. Significance of cerebellar tonsillar position on MR. *AJNR Am J Neuroradiol* 1986; 7:795-799.
30. Nishikawa M, Sakamoto H, Hakuba A, Nakanishi N, Inoue Y. Pathogenesis of Chiari malformation: a morphometric study of the posterior cranial fossa. *J Neurosurg* 1997; 86:40-47.

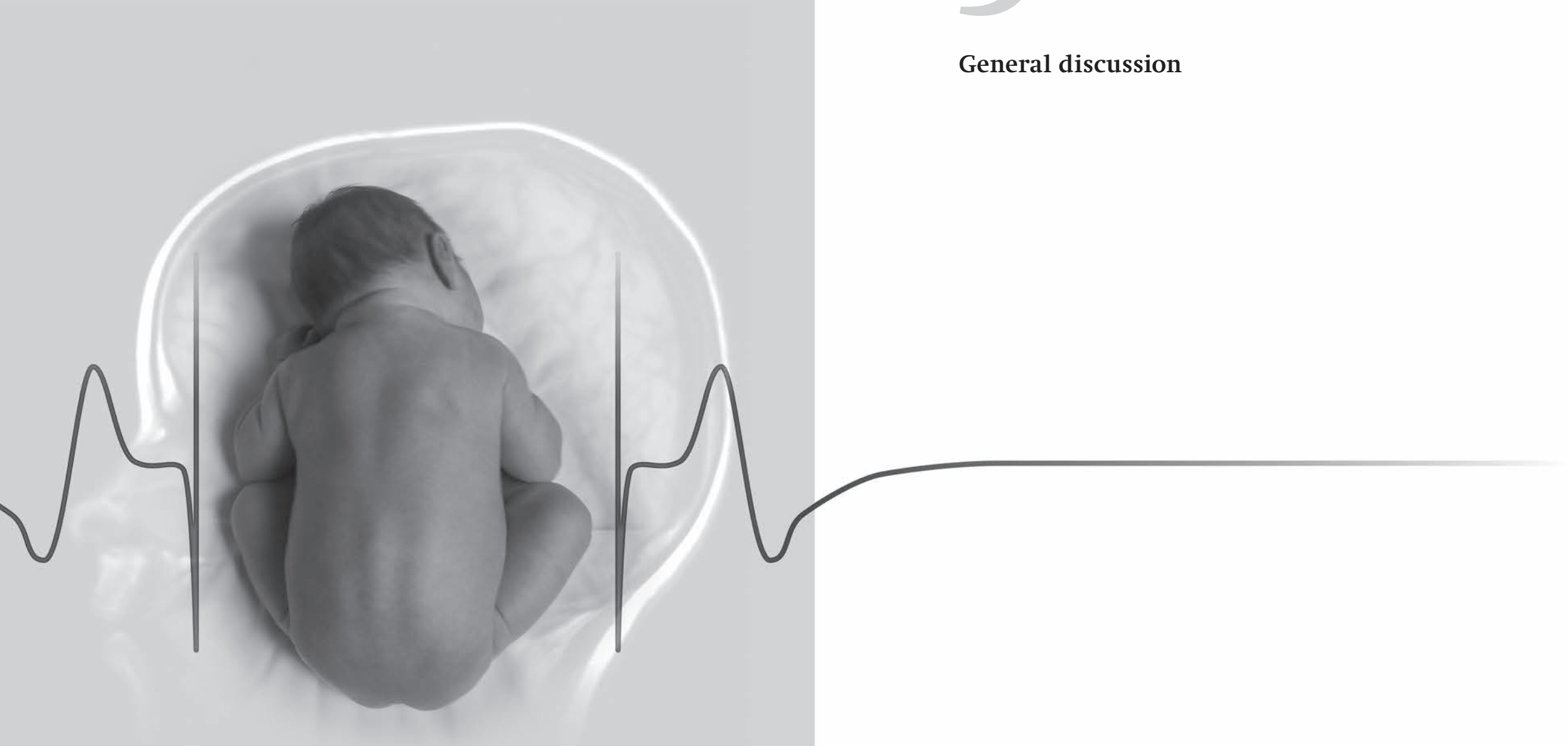

9

General discussion

Spina bifida is a complex and heterogeneous congenital malformation of the nervous system with pathology at multiple levels along the neural axis resulting in life-long disabilities and handicaps. Discussions on whether or not to treat severely affected newborn infants are still current [1], while fetal imaging and prenatal surgery are becoming more important nowadays [2,3]. The choices that have to be made about such prenatal and postnatal treatment options are complicated by the fact that the outcome for an individual infant with spina bifida is hardly predictable. In this final chapter, the findings described in this thesis are put in perspective related to these issues with a focus on the research questions formulated in Chapter 1. The main findings are discussed in light of the multilevel pathology of spina bifida and the diagnostic and prognostic values of the instruments used. Methodological and clinical considerations as well as research implications and future perspectives are presented.

Neurophysiological studies

Main findings in light of the multilevel pathology

As described and illustrated in Chapter 1, the pathology in spina bifida includes malformations at multiple levels along the neural axis. Consequently, motor impairment in the lower limbs may result from lower motor neuron (LMN) and upper motor neuron (UMN) dysfunction. LMN dysfunction in particular results from neurosegmental pathology in the spinal anomaly, whereas UMN dysfunction may result from pathology at several levels along the corticospinal tract. The neurophysiological studies in this thesis provide some new insights in the proportional LMN and UMN dysfunction in relation to the multilevel pathology of spina bifida.

Lower motor neuron function

Lower motor neurons are alpha-motor neurons (synonym: anterior horn cells) located in the ventral horns of the spinal cord with axons leaving the spinal cord through the ventral roots to innervate voluntary muscles. They can roughly be divided into fast-conducting thick fibres and slow-conducting thin fibres. The lower motor neuron and the muscle fibres innervated by its axon are called a motor unit.

In Chapters 2, 3 and 4 we showed that a certain degree of LMN function is present in virtually all affected spinal segments in newborn infants with spina bifida. This is not surprising in muscles that are paretic. However, we also demonstrated LMN function in paralytic muscles by obtaining reproducible compound muscle action potentials (CMAPs) after percutaneous electrical

stimulation, and motor evoked potentials (MEPs) after lumbosacral magnetic stimulation in these muscles. In agreement with our findings, other authors also reported similar responses in lower limbs muscles of infants with spina bifida [4-6]. In addition, the presence of LMN function is supported by neuropathological studies, which showed that ventral horns are usually present and often contain large numbers of anterior horn cells [7]. From these cells, nerve roots extend at the proper position in the malformed spinal cord innervating corresponding muscles [8]. On the other hand, Sival et al. [9] reported that disappearance of neonatal lower limb movements indicates additional progressive LMN dysfunction based on the presence of denervation potentials and the disappearance of muscle stretch reflexes in the first postnatal week. We also observed disappearance of lower limb movements in newborn infants, but according to our neurophysiological findings, this disappearance does not implicate complete loss of LMN function. Moreover, we showed that the neonatally present LMN function is at least partly preserved throughout the childhood years, because substantial CMAPs and lumbosacral MEPs were still obtainable in school-age children with spina bifida, also in paralytic muscles (Chapter 6). These findings are supported by neuropathological examinations of peripheral nerves that revealed preserved nerve bundles containing small numbers of normal axons in children with spina bifida [10].

The latencies of CMAPs and lumbosacral MEPs provide additional information about LMN function. In children with spina bifida, we considered these peripheral latencies as relatively unaffected, as they did not differ essentially from latencies in control children without spina bifida. These findings suggest that extensive dys- or demyelination of peripheral motor axons or loss of fast-conducting thick motor neurons are unlikely.

From the associations observed between the CMAP area and neurological impairment, we presumed a gradual cranio-caudal decrease in lower motor neuron function in affected spinal segments (Chapter 3). This assumption is supported by a gradual cranio-caudal reduction of motor neuron populations in affected spinal segments as seen in neuropathological examinations [11].

In conclusion, functional motor units are present in almost all affected spinal segments in neonatal spina bifida and are at least partly preserved with relatively intact conduction ability during the childhood years.

Upper motor neuron function

Upper motor neurons are motor neurons with their cell bodies in the cerebral cortex and their axons descending into the spinal cord to make synaptic connections with spinal alpha-motor neurons in the ventral horns. We attempted to investigate UMN function in newborn infants with spina bifida using

transcranial magnetic stimulation (TMS), but this method did not result in reproducible MEPs. These findings are is in agreement with experiences of other investigators, as reliable transcranial MEPs without facilitation are generally not obtainable in infancy [12-14]. Therefore, we are not able to draw clear conclusions about UMN function in neonatal spina bifida. In the literature, assumptions on UMN function in newborn infants are mainly based on observational studies and are somewhat inconsistent. Stark and Drummond [5,6] postulated that lower limb weakness results from UMN dysfunction rather than LMN dysfunction based on observations of voluntary and reflex activity in the lower limbs and on responses to stimulation of the neuroplacode. Sival et al. [15] suggested preserved neural conduction through the spinal anomaly based on the concurrence of lower limb movements and general movements, and as such, they suggested that UMN input is preserved. In addition to these assumptions, we like to speculate that the gradual cranio-caudal decrease in LMN function in the affected spinal segments might be secondary to a decreased connectivity with UMNs in the more caudal affected segments, as the corticospinal tract fibers leading to these caudal segments may be more vulnerable than the fibers leading to cranial affected segments (Chapter 3). Therefore, UMN dysfunction might be the primary factor in lower limb motor impairment in newborn infants with spina bifida.

In contrast to the results in newborn infants, we were able to investigate UMN function in school-age children with spina bifida (Chapter 6). In this study, reproducible MEPs were obtained after TMS and UMN dysfunction was demonstrated by reduced transcranial MEP areas and prolonged central motor conduction times (CMCTs) in children with spina bifida compared to control children without spina bifida. The transcranial MEP area not only reflects the excitability of the motor cortex and the integrity of the corticospinal tract (UMN), but also the excitability of spinal motor neurons and the conduction along the peripheral motor pathways (LMN) [16]. Therefore, the reduced transcranial MEP areas in our study may reflect both UMN and LMN dysfunction. Considering the substantial reduction in transcranial MEP areas not only in the lower limb muscles but also in the upper limb muscles (See Table 3 in Chapter 6), it is unlikely that this reduction is due to LMN dysfunction alone. Above all, a prolonged CMCT indicates UMN dysfunction, as it includes the time needed for excitation of cortical cells, conduction via the corticospinal tract, and excitation of spinal motor neurons sufficient to exceed their firing threshold [17]. Consequently, a prolonged CMCT may result from abnormal cortical excitation (indirect versus direct excitation of the corticospinal tract), dys- or demyelination of the corticospinal tract, loss of large fast-conducting corticospinal neurons, or impaired summation of descending volleys at spinal motor neurons [17-19]. All these mechanisms may be involved in spina bifida, as is discussed in the paragraphs below.

Regarding the complex neuropathology of spina bifida, UMN dysfunction may have its origin at multiple levels along the neural axis (see Figure 1 in Chapter 1). Considerations about UMN dysfunction in relation to these levels are discussed in a caudo-cranial direction.

Most caudally, the axonal endings of the corticospinal tract are likely to be disrupted in the spinal anomaly. This disruption may be more substantial in caudal than in cranial affected spinal segments. The corticospinal tract in fused spinal segments above the spinal anomaly may be disrupted due to tethering of the spinal cord or due to syringomyelia. Based on our findings, we cannot draw clear conclusion about these corticospinal tract levels, but abnormal myelination due to traction on the spinal cord or syringomyelia may be associated with a prolonged CMCT. Abnormal myelination of the spinal cord is frequently seen in neuropathological examinations [20].

The origin of UMN may be located at a supraspinal level as well. As similar results regarding UMN dysfunction were found for the lower limb muscles and the biceps brachii muscle (Chapter 6), part of the origin should be located above the neurosegmental innervation of the biceps brachii muscle. This may be at infratentorial level, where the corticospinal tract could be affected either by maldevelopment as part of Chiari II malformation or by damage due to compression in a crowded posterior fossa. Clinical signs of spasticity are frequently seen in children with symptomatic Chiari II malformation [21-23], providing further support for the involvement of Chiari II malformation in UMN dysfunction.

Furthermore, supratentorial malformations, whether or not related to hydrocephalus, may be involved in UMN dysfunction as well. In recent years, advanced imaging techniques revealed detailed cerebral white and gray matter abnormalities in spina bifida [24]. Regarding white matter, a diffusion tensor imaging study showed extensive abnormalities in white matter tracts in individuals with spina bifida [25]. However, the corticospinal tract at the posterior limb of the internal capsule appeared to be relatively unaffected [26]. Therefore, it is difficult to relate the prolonged CMCT in our study to the white matter abnormalities in the diffusion tensor imaging study. Regarding gray matter, malformations of cortical development in spina bifida have been reported before [27,28]. More recently, advanced quantitative MR imaging revealed important abnormal patterns of thickening, thinning, and gyrification of the cortex [24,29]. Although research on these cortical abnormalities is focused on cognitive impairment, it is conceivable that these abnormalities are involved in motor dysfunction as well. The abnormal patterns of gray matter might be substrates for our findings on UMN dysfunction, as abnormal cortical excitation may result in prolonged CMCTs and reduced transcranial MEPs. In addition, gray matter abnormalities may be involved in facilitation of transcranial MEPs. As

known from the literature, voluntary muscle contraction during TMS results in shorter MEP latencies and larger MEP areas [30]. In our study, this facilitatory effect was substantially decreased in school-age children with spina bifida (See Figure 2 in Chapter 6). Although the physiology of facilitation, in which both spinal and cortical mechanisms seem to be involved, is not completely understood [31], gray matter abnormalities are likely to interfere with the facilitatory effects at cortical level.

In conclusion, our findings show that UMN dysfunction contributes substantially to motor impairment in spina bifida and support a supraspinal localization of UMN dysfunction.

Upper motor neuron in relation to lower motor neuron dysfunction

The findings in this thesis show that both UMN and LMN dysfunction are involved in motor impairment in the lower limbs, but we cannot draw firm conclusion about their proportional contribution to motor impairment. Yet, we might speculate that UMN dysfunction plays a central role and that LMN dysfunction is secondary to UMN dysfunction. Findings that may support this assumption are the gradual cranio-caudal decrease of LMN function in affected spinal segments in neonatal spina bifida and the clearly prolonged central motor conduction times in contrast to the relatively unaffected peripheral motor conduction times in children with spina bifida. In addition to these findings, we speculate about circumstantial support for these assumptions focusing on the establishment of the synaptic connections between UMNs and LMNs during spinal cord development. First, in the complex embryonic development of the spinal cord, the axons of the corticospinal tract descend into the spinal cord to make synaptic connections with spinal motor neurons [32,33], which originate in the ventral section of the neural tube [34,35]. The descend of corticospinal tract axons in the lateral sections of the spinal cord may be disturbed to a larger extent than the development of anterior horn cells in the relatively sheltered ventral section. Second, functional synaptic corticospinal connections to spinal motor neurons are only established during the final trimester of gestation in normal development [36]. In spina bifida, the 'second hit' to the vulnerable neuroplacode may harm proper establishment of these synaptic connections. Furthermore, spinal ischemia resulting from aberrant spinal cord blood vessels in combination with reduced blood flow during delivery [37], may further harm these connections, as we know from experimental studies that synaptic activity is very vulnerable to ischemia [38]. In addition, ischemia-induced synaptic failure might be an explanation for the disappearance of lower limb movements in early neonatal life. Third, UMNs are involved in activity-dependent maturation of LMNs during a critical period of normal development [36]. If synaptic connections

between UMNs and LMNs are not well established, the LMNs will fail to maturate normally secondary to synaptic dysfunction. Finally, transsynaptic degeneration due to insufficient corticospinal input may result in LMN loss as well [39].

Methodological considerations

To our best knowledge, the neurophysiological studies in this thesis are the first studies aiming to investigate corticospinal and spinal motor function in spina bifida using neurophysiological tools, such as magnetic stimulation. The strengths of the studies are the participation of newborn infants as well as school-age children, the prospective study design regarding the investigations in newborn infants, and the participation of an appropriate control group in the study on school-age children. During the study period, virtually all newborn infants born at or referred to our centre were included in the prospective study and they were all investigated before surgical closure of the spinal anomaly. All participants were systematically evaluated according to the study protocol in which we used generally accepted and well-established neurophysiological methods and clinical impairment measures.

The studies also had some limitations. The sample sizes of the cohorts were smaller than anticipated at at the start of the study. Important reasons for the small neonatal cohort were a decreasing prevalence of live born children with spina bifida in the Netherlands during the study period and loss of follow-up due to migration or withdrawal of consent. In the cohort of school-age children, the willingness to participate was lower than expected. The main reason for non-participating was the burden that the research protocol placed upon children and parents. Although we are under the impression that the non-participating children did not differ from the included children, non-response bias cannot be ruled out completely. Despite the small sample sizes, the results provided new pathophysiological insights and knowledge about the diagnostic value of the neurophysiological instruments in spina bifida. However, the sample size of the neonatal cohort was too small to draw firm conclusions about the prognostic value of the neurophysiological instruments.

Participation of a neonatal control group would have been interesting from a pathophysiological point of view. However, in the initial phase of our research program, the focus of interest was the diagnostic value of CMAPs and MEPs in differentiating between mildly and severely affected infants, which did not need a control group. With the expansion of the focus to pathophysiology, a neonatal control group and longitudinal measurements could have provided additional insights in the development of motor function in spina bifida. We attempted to perform magnetic stimulation at the first follow-up moment at two years of age. However, we were unable to obtain reliable responses due to lack of cooperation.

Other methodological considerations concern TMS, as TMS may result in direct corticospinal tract excitation or in indirect corticospinal tract excitation by transsynaptic excitation from cortical interneurons [16]. In healthy subjects, high TMS intensities mainly results in direct excitation and low TMS intensities in indirect excitation [19]. In spina bifida, however, we are unaware of the proportions of direct and indirect excitation relative to TMS intensity. Determination of motor thresholds or stimulus-response curves might have provided more information about cortical excitability [17]. Since we performed TMS at 100% intensity and did not use a predefined percentage above threshold, the degree of intensity above threshold may have differed between control children and children with spina bifida or among children with spina bifida. These differences may have influenced the results to a certain extent, which cannot be predicted.

Spinal magnetic stimulation results in activation of motor nerve roots at the site where they leave the intervertebral foramen. At this site, the magnetic field focuses and the stimulus threshold is low. As the spine insulates the spinal cord, direct stimulation of the spinal cord is impossible [40,41]. In spina bifida, however, the site of activation might be at another level, due to the abnormal spinal anatomy. Theoretically, excitation could then occur at corticospinal level. However, the unaffected peripheral latencies in children with spina bifida as compared to control children (Chapter 6) do not support this hypothesis. Furthermore, spinal magnetic stimulation does not result in supramaximal responses in healthy subjects, since axons of fast-conducting motor neurons are stimulated predominantly [41,42]. In spina bifida, however, the absence of bony insulation and the more superficial localization of neural tissue may result in the activation of relatively more axons. The lumbosacral MEP areas in our study support this assumption, as the MEP areas in gastrocnemius and tibialis anterior muscles seem to approach the supramaximal CMAP areas generated in the same muscles in children with spina bifida, whereas the MEP areas are clearly smaller than the CMAP areas in children without spina bifida (See Tables 1 and 2 in Chapter 6). This may explain the more obvious differences between children with spina bifida and control children for the CMAP areas than for the lumbosacral MEP areas.

The CMCTs were calculated from the differences between the latencies of the transcranial and lumbosacral MEPs. Considering the fact that lumbosacral magnetic stimulation results in activation of motor nerve roots at the site where they leave the intervertebral foramen, the calculated CMCT includes part of the proximal spinal motor neuron. The contribution of this proximal part is relatively small and will be equal in children with spina bifida and control children, because the lumbosacral MEP latencies did not differ between these

children. Other methods to measure the CMCT are also available. Using the F-response latency, the calculated CMCT might be more precise [18]. However, F-responses are highly variable in latency, they may be difficult to obtain in affected nerves, and they are difficult to interpret in multisegmentally innervated muscles. Moreover, performing 10 to 20 reliable electrical stimuli may be a large burden to children. Using a triple stimulation technique, the corticospinal motor conduction time can be measured very precisely [43]. However, this method is only suitable for upper limb muscles and is very painful especially when Erb's point is electrically stimulated.

Clinical diagnostic and prognostic implications

Nerve conduction studies have proven to be of clinical usefulness in neuropathies and other neuromuscular disorders in adults and children for many years. Magnetic stimulation is a relatively new neurophysiological tool providing information about the excitability of the motor cortex and the functional integrity of the corticospinal tract as well as the peripheral motor pathways [16]. The method is safe and non-invasive and it is easily used and well-tolerated [44,45].

In adults, magnetic stimulation has proven to be of diagnostic value in neurological disorders, such as myelopathy, amyotrophic lateral sclerosis, multiple sclerosis, and stroke, while prognostic value is reported for multiple sclerosis and stroke as well [16,17]. In children, investigations using magnetic stimulation provided additional understanding of the development and maturation of the central nervous system and its reorganization potential following early brain injury [46]. In children with cerebral palsy, TMS investigations revealed projections from the contra-lesional hemisphere participating in motor control of paretic hand muscles [47-49]. TMS also appeared to have some prognostic value regarding early brain injury [47,50,51]. In addition, TMS can demonstrate corticospinal tract involvement in complex neurological disorders, despite the absence of significant abnormalities on MR imaging [46,52-54].

In our studies, the MEP and CMAP areas seem to reflect the severity of neurological impairment, as severely affected newborn infants and school-age children had smaller MEP and CMAP areas than mildly affected subjects (Chapters 3, 4, and 6). Although the distinction between mildly and severely impaired children may be apparent from neurological examination, the neurophysiological tools may be helpful in quantifying the degree of neurological impairment. Furthermore, TMS may have a diagnostic value in revealing clinically hidden UMN dysfunction. The clinical neurological picture of spina bifida is generally dominated by flaccid paresis of the lower limbs, from which the presence of UMN dysfunction might be underestimated. Clinical signs of

spasticity are seen in less than 50% [55-57], whereas our findings showed UMN dysfunction in almost all children. TMS may be particularly helpful to detect subclinical deterioration of UMN function. For example, secondary tethering of the spinal cord is commonly seen in growing children with spina bifida. As this complication is generally associated with additional UMN dysfunction, TMS may be helpful in an early recognition of a tethered spinal cord.

In newborn infants with spina bifida, we have shown that percutaneous electrical nerve stimulation and lumbosacral magnetic stimulation are applicable and well tolerated (Chapter 2). CMAPs and MEPs provide a quantitative estimate of residual LMN function in affected spinal segments in these infants. Despite strong associations between the neurophysiological parameters and the neurological impairment levels at neonatal age, the prognostic value of these parameters appeared to be weak. The neonatal MEP and CMAP areas had some prognostic value for neurological outcome and walking ability, but the clinically assessed neonatal neurological impairment levels showed better prognostic value (See Table 4 in Chapter 4). Considering the substantial involvement of UMN dysfunction in motor impairment, as demonstrated in school-age children, the weak prognostic value may be explained by the fact that the assessed neonatal MEPs and CMAPs only reflect LMN function. Furthermore, it should also be noted that a substantial part of children with spina bifida will achieve walking ability beyond the age of two years [58]. Therefore, the prognostic value for walking ability at a later age might be somewhat better.

In addition to motor dysfunction in a narrow term, other factors may influence the neurodevelopmental outcome in spina bifida. The extent of sensory impairment is strongly related to the outcome, for example. In the studies of Hunt and Oakeshott [59,60], the degree of neonatal sensory impairment turned out to be predictive for ambulation, need of daily care, and community participation in adulthood. Other factors, such as balance disturbances, energy expenditure, scoliosis, and joint contractures may influence the outcome as well [56,61].

Brain MR imaging studies

In addition to the spinal anomaly, Chiari II malformation is another important developmental malformation in spina bifida. The Chiari II malformation is characterized by a small posterior fossa and downward displacement of the cerebellum and brainstem through an enlarged foramen magnum, and it may cause substantial morbidity and mortality [23,62-64]. The malformation is usually diagnosed using MR imaging. However, the MR interpretation of the

malformation may not always be straightforward due to its heterogeneity and an abundance of morphological features. This may be particularly relevant in the assessment of its severity in decision-making processes regarding the treatment of spina bifida.

Main findings

The brain MR imaging studies described in this thesis identified reliable morphological features of the malformation (Chapter 7) and provided morphometric measures that can be used to quantify the extent of the malformation (Chapter 8). The use of these features and measures may improve the MR assessment of Chiari II malformation.

The unreliability of several features of the Chiari II malformation supports our hypothesis that the MR interpretation is not straightforward. Most of the features studied were originally derived from post-mortem examinations or computed tomography studies [65-70]. With the introduction of MR imaging, they were simply applied to rate MR images without critical appraisal of their compatibility for MR images. To our best knowledge, our study is the first in which the reliability of these features was investigated. We showed that several features are not reliable enough to assess Chiari II malformation on MR images.

The main deformity in Chiari II malformation is herniation of the cerebellum through an enlarged foramen magnum. In the literature, this herniation is inconsistently termed as cerebellar [71], vermis [22,23,72], or tonsil herniation [73,74]. Our study demonstrated that it is possible to reliably assess whether or not herniation of any part of the cerebellum is present on MR images, but that distinguishing vermis and tonsil herniation from each other is unreliable. In addition, neuropathological examinations showed that herniation of the vermis without herniation of the tonsils does not occur [75]. Therefore, we recommend to use only the term cerebellar herniation in the MR assessment of Chiari II malformation. Other typical features of the Chiari II malformation, like downward displacement of the medulla and fourth ventricle, medullary kinking, and beaked tectum appeared to be reliable features as well, but these were seen less frequently than cerebellar herniation (See Table 3 in Chapter 7). Therefore, we recommend that the diagnosis Chiari II malformation should be based on the presence of open spinal dysraphism in combination with cerebellar herniation in the sagittal MR plane.

In contrast to the morphological features, most morphometric measures investigated turned out to be reliable in quantifying the morphological abnormalities. This discrepancy is not surprising, as quantitative measures are easier to define than qualitative features. As such, some measures may substitute unreliable features. For example, the interobserver reliability for the morphological position

and shape of the pons was weak (See Table 4 in Chapter 7), whereas measurements of the thickness, length and position of the pons were particular reliable and showed clear differences between Chiari II malformation and normal hindbrain morphology (See Tables 2 and 4 in Chapter 8). 'Wrapping' of the cerebellum around the brainstem and 'towering' of the cerebellum were unreliable features as well. These features describe the abnormal extension of the cerebellar hemispheres in the axial and coronal plane, respectively. In our attempt to assess these features quantitatively by measuring the hemispheral length and height (See Table 1 in Chapter 8), we found that these measures were reliable, but failed to be distinctive between Chiari II malformation and normal hindbrain morphology. Therefore, these measures are just as unsuitable as their corresponding features.

Most of the reliable measures pertain to the morphological abnormalities in Chiari II malformation, which can be seen from the substantial measurement differences between children with and without Chiari II malformation (See Table 4 in Chapter 8). Therefore, we expect these measures to be useful in a severity assessment of the malformation. Two measures, *Cerebellar width* and *Mamillopontine distance*, showed clear diagnostic potential, as they were highly sensitive and specific for Chiari II malformation. *Cerebellar width* is closely related to the small posterior fossa, which is a central aspect of the pathology of Chiari II malformation [76], while *Mamillopontine distance* reflects the caudal displacement of the brainstem. However, the dimension of this measure is very small, which could be a source of measurement errors.

Methodological considerations

Prior to the study, an extensive literature search was performed in order to incorporate all known features and measures of the Chiari II malformation in the study. Because we felt that measures to appraise the malformation in the axial and coronal planes were lacking, we defined new measures as well.

Several other MR imaging studies regarding the Chiari II malformation are described in the literature (see Chapters 7 and 8 for an overview). In contrast to these studies, our study addressed interobserver reliability of features and measures as well as the diagnostic performance of Chiari II malformation measures, which makes the study original. Further added value can be found in our presentation of measures in three planes with their reliability assessed in different diagnostic groups.

All observers worked at the same academic hospital at the time of the study, which might have increased the interobserver agreement through institutional bias. However, the observers differed in terms of experience and educational and professional background, which guarantees a realistic diversity in observers comparable to clinical practice.

The study also had some limitations. First, the number of available MR images of children with spina bifida was relatively small as the participation of school-age children in the overall research program was lower than expected. We attempted to replenish the study material by retrieving appropriate MR images from the archives of the Department of Radiology, which might have made the set of MR images more heterogeneous. However, this heterogeneity resembles daily clinical practice. Second, we could not take into account a possible age effect on the morphometric analyses, even though brain dimensions change in a growing child. Salman et al. [77], however, showed that MR measurements of the posterior fossa do not correlate with age in children with Chiari II malformation. In our study, the strong differences between affected and unaffected children seem to outweigh the influence of age. Third, a recurrent issue in spina bifida research is the influence of hydrocephalus on brain morphology and function. Hydrocephalus was present in virtually all children with Chiari II malformation, and as such, it is difficult to disentangle abnormalities due to Chiari II malformation from abnormalities due to hydrocephalus. The mamillopontine distance in particular is affected by both Chiari II malformation and hydrocephalus, as an increased mamillopontine distance results from caudal displacement of the brainstem and pons [78], while hydrocephalus may decrease this distance [79]. In our study, all children with hydrocephalus were shunted and none of the children had a decreased mamillopontine distance. Therefore, we assumed that the effect of increased intracranial pressure on the measurements was minimal in the population studied. In fetuses and newborn infants with unshunted hydrocephalus, however, increased intracranial pressure may influence the measurements and caution is called for when applying the results to neonatal and fetal MR images.

Clinical implications

The Chiari II malformation seems to be a clear entity with apparently recognizable characteristics, but clinicians should be aware of different interpretations of its MR features among observers. In the care of children with Chiari II malformation, decision-making processes regarding treatment should be based on clinical signs and symptoms in combination with reliable MR findings. Using reliable features and measures may facilitate plain communication about the malformation in such processes. Although Chiari II malformation is almost uniquely associated with open spinal dysraphism, there might be exceptions. In such cases, measuring the cerebellar width or mamillopontine distance may be helpful to diagnose Chiari II malformation.

Several advanced MR imaging methods, such as volumetric analyses, diffusion tensor imaging, and fiber tractography are upcoming in research settings [24], but conventional MR imaging is still the first choice imaging tool in clinical

settings with broad accessibility to all clinicians working with children with spina bifida. It is important that these clinicians are informed about the reliability and diagnostic value of features and measures on conventional MR images. The features and measures presented in this thesis are particularly useful in routine clinical practice, as they are easy to be assessed by radiologists as well as by clinicians who may be less familiar with reviewing MR images.

In addition, clinicians should be aware of the imprecise judgment of the degree of cerebellar herniation in the midsagittal plane. The measures presented in Chapter 8 are more suitable to quantitatively assess the morphological abnormalities. They appraise the cerebellum and brainstem, not only in the midsagittal plane, but also in the axial and coronal plane providing reliable quantifications of most morphological abnormalities in Chiari II malformation.

Research implications and other future perspectives

Research implications for prenatal surgery

Prenatal surgery is a hot topic in spina bifida and has become an optimistic treatment option since the first successful prenatal interventions were reported in the late 1990s [80,81]. Recently, a randomized trail (Management of Myelomeningocele Study – MOMS trail) showed improvement of motor outcome and reduction of hindbrain herniation and hydrocephalus shunting after prenatal surgery compared to postnatal surgery [82]. However, data about long-term outcome after prenatal surgery are limited and criticism about prenatal surgery is present as well [83,84]. The results presented in this thesis may contribute to the understanding of the outcome of prenatal surgery as well as to an objective evaluation of the outcome.

The neurophysiological studies may provide additional understanding regarding the improved motor outcome after prenatal surgery. Considering the UMN dysfunction and its relation with motor impairment demonstrated in our study, improved motor outcome is likely to result from an improved corticospinal tract development after prenatal surgery. In particular, the establishment of synaptic connections between the corticospinal and spinal motor neurons may be protected by interventions in utero. To gain further support for these assumptions, it would be interesting to assess UMN function neurophysiologically in the children included in the MOMS trail. Furthermore, magnetic stimulation may be a valuable instrument to objectively evaluate the outcome of prenatal surgery.

Another interesting issue in prenatal surgery is the reported reduction of hindbrain herniation, which is assessed by the degree of cerebellar herniation and the position of the fourth ventricle [82]. Our findings, however, showed that

this scoring system might be imprecise, and moreover, the degree of herniation is only weakly related to the functional severity of the malformation [85]. The reliable measures presented in this thesis may be more helpful to objectively evaluate the effect of prenatal surgery on Chiari II malformation. The added value of these measures is that they appraise different parts of the malformation in three dimensions.

Future perspectives

The neurophysiological findings presented showed UMN dysfunction at a supraspinal level in spina bifida using conventional TMS. Currently, more advanced methods of TMS, such as paired-pulse TMS and silent period measurements, are available. These methods may provide information about cortical excitatory and inhibitory phenomena [16] and may be particularly useful to investigate the supraspinal localization of UMN dysfunction in more detail.

In addition, a method to investigate UMN function in newborn infants is desirable. Methods using muscle pre-activation to elicit transcranial MEPs in newborn infants are reported in the literature [86], but these methods are difficult to perform and may result in highly variable MEPs [87]. If muscle pre-activation can be standardized, for example by paired-pulse TMS, assessment of UMN function might become possible in newborn infants with spina bifida.

Prospective longitudinal neurophysiological measurements in subjects with spina bifida and control subjects from neonatal age to late childhood may provide additional information about the postnatal course of corticospinal and spinal motor function in spina bifida. Furthermore, knowledge about fetal development of the corticospinal and spinal motor neurons and in particular the establishment of spinal synaptic connections in spina bifida is still limited. Methods to study these developmental processes from morphological and functional points of view are ultimately desirable in order to provide further understanding of the complex pathology of spina bifida.

The follow-up of the neonatal cohort described in this thesis was short. Future follow-up assessments of this cohort may reveal more information about the prognostic value of the neurophysiological tools for motor outcome at different ages during childhood.

Regarding the MR imaging study, the reliable measures may be of particular value regarding severity assessment of Chiari II malformation. The clinical severity may not only be reflected in the classical brainstem and cervical spinal cord symptoms, but also in cognitive function [88]. Therefore, an exploration of associations between morphometric measurements, clinical signs and symptoms,

and cognitive function may be interesting regarding a potential prognostic significance of the measures. Before the true prognostic significance of the measures can be established, however, their consistency needs to be tested on fetal and neonatal brain MR images first.

An ultimate future perspective based on this thesis is an analysis in which the neurophysiological findings are combined with the MR imaging findings. Investigating associations between these findings may be helpful to explore the involvement of Chiari II malformation in UMN dysfunction. This involvement might be demonstrated by hypothetical associations between the MR measurements and the CMCT or transcranial MEP area. Furthermore, other advanced MR imaging techniques, such as diffusion tensor imaging and volumetric studies, offer new perspectives to assess motor function in spina bifida. Using these methods, the main white matter fiber bundles and abnormal patterns of gray matter can be visualized. Currently, research using these advanced techniques is focused on cognitive function in spina bifida [24], but these techniques may also be useful to investigate the integrity of central motor pathways in relation to clinical motor impairment.

References

1. Barry S. Quality of life and myelomeningocele: an ethical and evidence-based analysis of the Groningen Protocol. *Pediatr Neurosurg* 2010; 46:409-414.
2. Bulas D. Fetal evaluation of spine dysraphism. *Pediatr Radiol* 2010; 40:1029-1037.
3. Danzer E, Johnson MP, Adzick NS. Fetal surgery for myelomeningocele: progress and perspectives. *Dev Med Child Neurol* 2012; 54:8-14.
4. Mortier W, von Bernuth H. The neural influence on muscle development in myelomeningocele: histochemical and electrodiagnostic studies. *Dev Med Child Neurol* 1971; 13(Suppl.25):82-89.
5. Stark GD, Drummond M. The spinal cord lesion in myelomeningocele. *Dev Med Child Neurol* 1971; 13(Suppl.25):1-14.
6. Stark GD, Drummond M. Neonatal electromyography and nerve conduction studies in myelomeningocele. *Neuropädiatrie* 1972; 3:409-420.
7. Emery JL, Lendon RG. Clinical implications of cord lesions in neurospinal dysraphism. *Dev Med Child Neurol* 1972; 14(Suppl.27):45-51.
8. Hori A. A review of the morphology of spinal cord malformations and their relation to neuro-embryology. *Neurosurg Rev* 1993; 16:259-266.
9. Sival DA, van Weerden TW, Vles JS, et al. Neonatal loss of motor function in human spina bifida aperta. *Pediatrics* 2004; 114:427-434.
10. Ralis Z, Ralis HM. Morphology of peripheral nerves in children with spina bifida. *Dev Med Child Neurol* 1972; 14(Suppl.27):109-116.
11. Lendon RG. Neuron population in the lumbosacral cord of myelomeningocele children. *Dev Med Child Neurol* 1969; 11(Suppl.20):82-85.
12. Muller K, Homberg V, Lenard HG. Magnetic stimulation of motor cortex and nerve roots in children. Maturation of cortico-motoneuronal projections. *Electroencephalogr Clin Neurophysiol* 1991; 81:63-70.
13. Nezu A, Kimura S, Uehara S, Kobayashi T, Tanaka M, Saito K. Magnetic stimulation of motor cortex in children: maturity of corticospinal pathway and problem of clinical application. *Brain Dev* 1997; 19:176-180.
14. Garvey MA, Ziemann U, Bartko JJ, Denckla MB, Barker CA, Wassermann EM. Cortical correlates of neuromotor development in healthy children. *Clin Neurophysiol* 2003; 114:1662-1670.
15. Sival DA, Brouwer OF, Bruggink JL, et al. Movement analysis in neonates with spina bifida aperta. *Early Hum Dev* 2006; 82:227-234.
16. Kobayashi M, Pascual-Leone A. Transcranial magnetic stimulation in neurology. *Lancet Neurol* 2003; 2:145-156.
17. Chen R, Cros D, Curra A, et al. The clinical diagnostic utility of transcranial magnetic stimulation: report of an IFCN committee. *Clin Neurophysiol* 2008; 119:504-532.
18. Pascual-Leone A, Davey NJ, Rothwell J, Wassermann EM, Puri BK. eds. *Handbook of Transcranial Magnetic Stimulation.* 1st ed. London: Arnold, 2002.
19. Curra A, Modugno N, Inghilleri M, Manfredi M, Hallett M, Berardelli A. Transcranial magnetic stimulation techniques in clinical investigation. *Neurology* 2002; 59:1851-1859.
20. Gilbert JN, Jones KL, Rorke LB, Chernoff GF, James HE. Central nervous system anomalies associated with meningomyelocele, hydrocephalus, and the Arnold-Chiari malformation: reappraisal of theories regarding the pathogenesis of posterior neural tube closure defects. *Neurosurgery* 1986; 18:559-564.
21. Curnes JT, Oakes WJ, Boyko OB. MR imaging of hindbrain deformity in Chiari II patients with and without symptoms of brainstem compression. *AJNR Am J Neuroradiol* 1989; 10:293-302.
22. Rauzzino M, Oakes WJ. Chiari II malformation and syringomyelia. *Neurosurg Clin N Am* 1995; 6:293-309.
23. Stevenson KL. Chiari type II malformation: past, present, and future. *Neurosurg Focus* 2004; 16:E5.
24. Juranek J, Salman MS. Anomalous development of brain structure and function in spina bifida myelomeningocele. *Dev Disabil Res Rev* 2010; 16:23-30.
25. Hasan KM, Eluvathingal TJ, Kramer LA, Ewing-Cobbs L, Dennis M, Fletcher JM. White matter microstructural abnormalities in children with spina bifida myelomeningocele and hydrocephalus: a diffusion tensor tractography study of the association pathways. *J Magn Reson Imaging* 2008; 27:700-709.
26. Ou X, Glasier CM, Snow JH. Diffusion tensor imaging evaluation of white matter in adolescents with myelomeningocele and Chiari II malformation. *Pediatr Radiol* 2011; 41:1407-1415.
27. Barkovich AJ. Congenital malformations of the brain and skull. In: Barkovich AJ. ed. *Pediatric Neuroimaging*. 4th ed. Philadelphia: Lippincott Williams & Wilkins, 2005: 374-384.
28. Miller E, Widjaja E, Blaser S, Dennis M, Raybaud C. The old and the new: supratentorial MR findings in Chiari II malformation. *Childs Nerv Syst* 2008; 24:563-575.
29. Juranek J, Fletcher JM, Hasan KM, et al. Neocortical reorganization in spina bifida. *Neuroimage* 2008; 40:1516-1522.
30. Hess CW, Mills KR, Murray NM. Responses in small hand muscles from magnetic stimulation of the human brain. *J Physiol* 1987; 388:397-419.
31. Di Lazzaro V, Restuccia D, Oliviero A, et al. Effects of voluntary contraction on descending volleys evoked by transcranial stimulation in conscious humans. *J Physiol* 1998; 508:625-633.
32. Ten Donkelaar HJ, Lammens M, Wesseling P, Hori A, Keyser A, Rotteveel J. Development and malformations of the human pyramidal tract. *J Neurol* 2004; 251:1429-1442.
33. Eyre JA. Corticospinal tract development and its plasticity after perinatal injury. *Neurosci Biobehav Rev* 2007; 31:1136-1149.
34. Jessell TM. Neuronal specification in the spinal cord: inductive signals and transcriptional codes. *Nat Rev Genet* 2000; 1:20-29.
35. Briscoe J, Ericson J. Specification of neuronal fates in the ventral neural tube. *Curr Opin Neurobiol* 2001; 11:43-49.
36. Eyre JA, Miller S, Clowry GJ, Conway EA, Watts C. Functional corticospinal projections are established prenatally in the human foetus permitting involvement in the development of spinal motor centres. *Brain* 2000; 123:51-64.
37. Sival DA, Verbeek RJ, Brouwer OF, Sollie KM, Bos AF, den Dunnen WF. Spinal hemorrhages are associated with early neonatal motor function loss in human spina bifida aperta. *Early Hum Dev* 2008; 84:423-431.
38. Hofmeijer J, van Putten MJ. Ischemic cerebral damage: an appraisal of synaptic failure. *Stroke* 2012; 43:607-615.
39. Van de Meent H, Hosman AJ, Hendriks J, Zwarts M, Schubert M. Severe degeneration of peripheral motor axons after spinal cord injury: a European multicenter study in 345 patients. *Neurorehabil Neural Repair* 2010; 24:657-665.
40. Ugawa Y, Rothwell JC, Day BL, Thompson PD, Marsden CD. Magnetic stimulation over the spinal enlargements. *J Neurol Neurosurg Psychiatry* 1989; 52:1025-1032.
41. Chokroverty S, Flynn D, Picone MA, Chokroverty M, Belsh J. Magnetic coil stimulation of the human lumbosacral vertebral column: site of stimulation and clinical application. *Electroencephalogr Clin Neurophysiol* 1993; 89:54-60.
42. Schmid UD, Walker G, Hess CW, Schmid J. Magnetic and electrical stimulation of cervical motor roots: technique, site and mechanisms of excitation. *J Neurol Neurosurg Psychiatry* 1990; 53:770-777.
43. Magistris MR, Rosler KM, Truffert A, Landis T, Hess CW. A clinical study of motor evoked potentials using a triple stimulation technique. *Brain* 1999: 122:265-279.
44. Rossi S, Hallett M, Rossini PM, Pascual-Leone A. Safety, ethical considerations, and application guidelines for the use of transcranial magnetic stimulation in clinical practice and research. *Clin Neurophysiol* 2009; 120:2008-2039.
45. Gilbert DL, Garvey MA, Bansal AS, Lipps T, Zhang J, Wassermann EM. Should transcranial magnetic stimulation research in children be considered minimal risk? *Clin Neurophysiol* 2004; 115:1730-1739.

46. Frye RE, Rotenberg A, Ousley M, Pascual-Leone A. Transcranial magnetic stimulation in child neurology: current and future directions. *J Child Neurol* 2008; 23:79-96.
47. Carr LJ, Harrison LM, Evans AL, Stephens JA. Patterns of central motor reorganization in hemiplegic cerebral palsy. *Brain* 1993; 116:1223-1247.
48. Eyre JA, Taylor JP, Villagra F, Smith M, Miller S. Evidence of activity-dependent withdrawal of corticospinal projections during human development. *Neurology* 2001; 57:1543-1554.
49. Staudt M, Grodd W, Gerloff C, Erb M, Stitz J, Krageloh-Mann I. Two types of ipsilateral reorganization in congenital hemiparesis: a TMS and fMRI study. *Brain* 2002; 125:2222-2237.
50. Maegaki Y, Maeoka Y, Ishii S, et al. Mechanisms of central motor reorganization in pediatric hemiplegic patients. *Neuropediatrics* 1997; 28:168-174.
51. Vandermeeren Y, Bastings E, Fadiga L, Olivier E. Long-latency motor evoked potentials in congenital hemiplegia. *Clin Neurophysiol* 2003; 114:1808-1818.
52. Nezu A, Kimura S, Kobayashi T, et al. Transcranial magnetic stimulation in an adrenoleukodystrophy patient. *Brain Dev* 1996; 18:327-329.
53. Dan B, Christiaens F, Christophe C, Dachy B. Transcranial magnetic stimulation and other evoked potentials in pediatric multiple sclerosis. *Pediatr Neurol* 2000; 22:136-138.
54. Noguchi Y, Okubo O, Fuchigami T, Fujita Y, Harada K. Motor-evoked potentials in a child recovering from transverse myelitis. *Pediatr Neurol* 2000; 23:436-438.
55. Verhoef M, Barf HA, Post MW, van Asbeck FW, Gooskens RH, Prevo AJ. Secondary impairments in young adults with spina bifida. *Dev Med Child Neurol* 2004; 46:420-427.
56. Bartonek A, Saraste H. Factors influencing ambulation in myelomeningocele: a cross-sectional study. *Dev Med Child Neurol* 2001; 43:253-260.
57. Danielsson AJ, Bartonek A, Levey E, McHale K, Sponseller P, Saraste H Associations between orthopaedic findings, ambulation and health-related quality of life in children with myelomeningocele. *J Child Orthop* 2008; 2:45-54.
58. Bartonek A. Motor development toward ambulation in preschool children with myelomeningocele--a prospective study. *Pediatr Phys Ther* 2010; 22:52-60.
59. Hunt GM. Open spina bifida: outcome for a complete cohort treated unselectively and followed into adulthood. *Dev Med Child Neurol* 1990; 32:108-118.
60. Oakeshott P, Hunt GM, Poulton A, Reid F. Open spina bifida: birth findings predict long-term outcome. *Arch Dis Child* 2012; 97:474-476.
61. Samuelsson L, Skoog M. Ambulation in patients with myelomeningocele: a multivariate statistical analysis. *J Pediatr Orthop* 1988; 8:569-575.
62. McLone DG. Continuing concepts in the management of spina bifida. *Pediatr Neurosurg* 1992; 18:254-256.
63. Oakeshott P, Hunt GM. Long-term outcome in open spina bifida. *Br J Gen Pract* 2003; 53:632-636.
64. Hunt GM, Oakeshott P. Outcome in people with open spina bifida at age 35: prospective community based cohort study. *BMJ* 2003; 326:1365-1366.
65. Peach B. Arnold-Chiari malformation: anatomic features of 20 cases. *Arch Neurol* 1965; 12:613-621.
66. Emery JL, MacKenzie N. Medullo-cervical dislocation deformity (Chiari II deformity) related to neurospinal dysraphism (meningomyelocele). *Brain* 1973; 96:155-162.
67. Naidich TP, Pudlowski RM, Naidich JB, Gornish M, Rodriguez FJ. Computed tomographic signs of the Chiari II malformation. Part I: Skull and dural partitions. *Radiology* 1980; 134:65-71.
68. Naidich TP, Pudlowski RM, Naidich JB. Computed tomographic signs of Chiari II malformation. II: Midbrain and cerebellum. *Radiology* 1980; 134:391-398.
69. Naidich TP, Pudlowski RM, Naidich JB. Computed tomographic signs of the Chiari II malformation. III: Ventricles and cisterns. *Radiology* 1980; 134:657-663.
70. Naidich TP, McLone DG, Fulling KH. The Chiari II malformation: Part IV. The hindbrain deformity. *Neuroradiology* 1983; 25:179-197.

71. Sutton LN, Adzick NS, Bilaniuk LT, Johnson MP, Crombleholme TM, Flake AW. Improvement in hindbrain herniation demonstrated by serial fetal magnetic resonance imaging following fetal surgery for myelomeningocele. *JAMA* 1999; 282:1826-1831.
72. Wolpert SM, Anderson M, Scott RM, Kwan ES, Runge VM. Chiari II malformation: MR imaging evaluation. *AJR Am J Roentgenol* 1987 149:1033-1042.
73. Just M, Schwarz M, Ludwig B, Ermert J, Thelen M. Cerebral and spinal MR-findings in patients with postrepair myelomeningocele. *Pediatr Radiol* 1990; 20:262-266.
74. Danzer E, Finkel RS, Rintoul NE, et al. Reversal of hindbrain herniation after maternal-fetal surgery for myelomeningocele subsequently impacts on brain stem function. *Neuropediatrics* 2008; 39:359-362.
75. Variend S, Emery JL. Cervical dislocation of the cerebellum in children with meningomyelocele. *Teratology* 1976; 13:281-289.
76. McLone DG, Knepper PA. The cause of Chiari II malformation: a unified theory. *Pediatr Neurosci* 1989; 15:1-12.
77. Salman MS, Blaser SE, Sharpe JA, Dennis M. Cerebellar vermis morphology in children with spina bifida and Chiari type II malformation. *Childs Nerv Syst* 2006; 22:385-393.
78. El Gammal T, Mark EK, Brooks BS. MR imaging of Chiari II malformation. *AJR Am J Roentgenol* 1988; 150:163-170.
79. El Gammal T, Allen MB, Brooks BS, Mark EK. MR evaluation of hydrocephalus. *AJR Am J Roentgenol* 1987; 149:807-813.
80. Adzick NS, Sutton LN, Crombleholme TM, Flake AW. Successful fetal surgery for spina bifida. *Lancet* 1998; 352:1675-1676.
81. Tulipan N, Hernanz-Schulman M, Bruner JP. Reduced hindbrain herniation after intrauterine myelomeningocele repair: A report of four cases. *Pediatr Neurosurg* 1998; 29:274-278.
82. Adzick NS, Thom EA, Spong CY, et al. A randomized trial of prenatal versus postnatal repair of myelomeningocele. *N Engl J Med* 2011; 364;993-1004.
83. Shurtleff D. Fetal endoscopic myelomeningocele repair. *Dev Med Child Neurol* 2012; 54:4-5.
84. Simpson JL, Greene MF. Fetal surgery for myelomeningocele? *N Engl J Med* 2011; 364:1076-1077.
85. Narayan P, Mapstone TB, Tubbs RS, Grabb PA, Frye T. Clinical significance of cervicomedullary deformity in Chiari II malformation. *Pediatr Neurosurg* 2001; 35:140-144.
86. Koh TH, Eyre JA. Maturation of corticospinal tracts assessed by electromagnetic stimulation of the motor cortex. *Arch Dis Child* 1988; 63:1347-1352.
87. Hess CW, Mills KR, Murray NM. Magnetic stimulation of the human brain: facilitation of motor responses by voluntary contraction of ipsilateral and contralateral muscles with additional observations on an amputee. *Neurosci Lett* 1986; 71:235-240.
88. Vinck A, Maassen B, Mullaart R, Rotteveel J. Arnold-Chiari-II malformation and cognitive functioning in spina bifida. *J Neurol Neurosurg Psychiatry* 2006; 77:1083-1086.

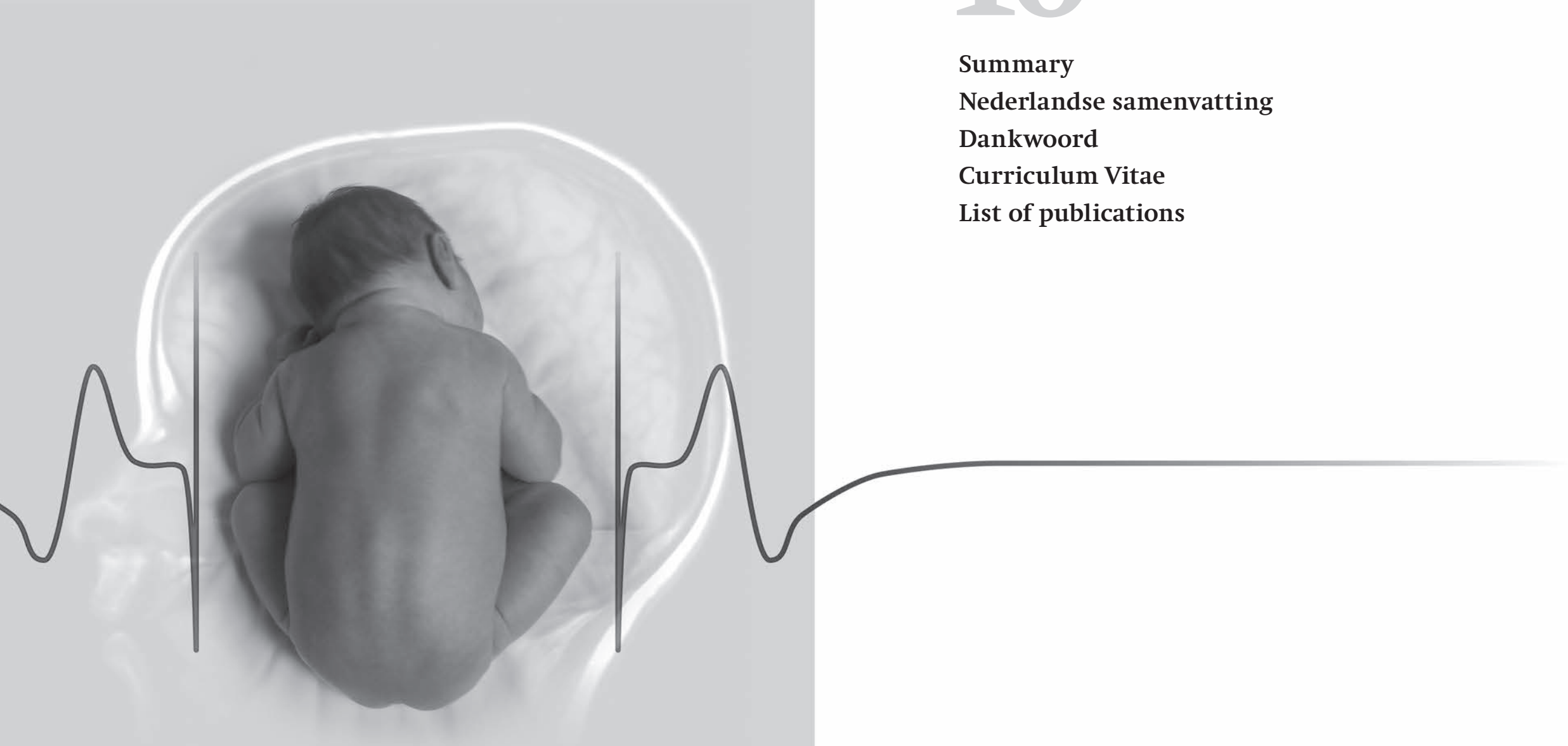

10

Summary

Spina bifida is a complex and heterogeneous congenital malformation of the nervous system with abnormalities at several levels along the neural axis (multilevel pathology). The most pronounced abnormality is the spinal anomaly, which results from an incomplete closure of the embryonic neural tube. Based on the appearance of the spinal anomaly, spina bifida can be categorized into *open spinal dysraphism* and *closed spinal dysraphism*. Other abnormalities include Chiari II malformation, hydrocephalus, corpus callosum dysmorphology, and cortical malformations. Although the neurodevelopmental outcome of children with spina bifida has improved over the last decades and spina bifida is compatible with long-term survival, affected individuals may encounter considerable consequences which have repercussions on daily activities and community participation. In particular, these consequences involve neurological impairment in the lower limbs, bladder and bowel dysfunction, orthopedic problems, sequelae from hindbrain compression, and cognitive impairments.

Chapter 1, the general introduction, provides background information regarding spina bifida and presents the motivation and aim of the thesis. The motivation is founded on the multilevel pathology and the heterogeneity of spina bifida. The improved overall outcome, the absence of up-to-date prognostic standards, and current discussions about prenatal and postnatal treatment also contribute to the motivation. Considering improvements in lower limb motor impairment and Chiari II malformation after prenatal surgery for spina bifida, the pathophysiology of motor impairment in relation to the multilevel pathology as well as the heterogeneity of Chiari II malformation are of particular interest. Neurophysiological investigations may provide new insights into the pathophysiology of motor impairment in spina bifida, and the assessment of Chiari II malformation may be upgraded by a critical appraisal of the malformation on magnetic resonance (MR) images. These two instruments may provide objective outcome measures or predictive tools and as such, may contribute to decision-making processes regarding the treatment of spina bifida. Hence, the aim of the thesis is twofold. First, we aim to disentangle the proportional contribution of upper motor neuron (UMN) and lower motor neuron (LMN) dysfunction to motor impairment in the lower limbs using conventional nerve conduction studies and transcranial and spinal magnetic stimulation. In addition, the diagnostic and prognostic values of these tools are studied. Second, we aim to improve the MR assessment of Chiari II malformation by critically appraising its morphological features and performing morphometric analyses on MR images.

This thesis is the third PhD thesis achieved within the Nijmegen Interdisciplinary Spina Bifida program. In this program, several different disciplines participate: pediatric neurology, neuropsychology, clinical neurophysiology, neuroradiology, obstetrics, epidemiology, family psychology, and empirical theology. The main purpose of the program is to determine the neurological, neuropsychological, and family-related outcomes of children with spina bifida aiming to improve prognostication and to support decision-making processes regarding prenatal and postnatal treatment.

Part one contains the neurophysiological studies. **Chapter 2** describes a pilot study in which the applicability of transcranial and lumbosacral magnetic stimulation was investigated in 13 newborn infants with spina bifida. Transcranial magnetic stimulation did not lead to any response at all. This was not completely surprising, as it is known from the literature that transcranial motor evoked potentials (MEPs) are difficult to obtain in healthy newborn infants as well. Consequently, we were unable to investigate UMN function in neonatal spina bifida by means of MEPs. In contrast, lumbosacral magnetic stimulation resulted in reproducible MEPs in the lower limb muscles, even in paralytic muscles, in most infants. As such, lumbosacral magnetic stimulation turned out to be applicable to investigate LMN function in neonatal spina bifida. In addition, nerve conduction studies were performed, which resulted in compound muscle action potentials (CMAPs) that were compatible with the obtained MEPs. The findings in this pilot study imply that excitable neural tissue is present at or caudally from the spinal anomaly and we concluded that the integrity of LMNs is at least partly preserved after birth.

In **Chapters 3** and **4**, associations between neurophysiological measurements and clinical neurological impairment assessments in newborn infants with spina bifida were investigated in the light of the potential prognostic value of the neurophysiological tools used. *Chapter 3* addresses associations between CMAPs in the tibialis anterior and gastrocnemius muscles and neurological impairment in 31 newborn infants with spina bifida. The area under the CMAP curve (CMAP area) was associated with the level of motor and sensory impairment and with the presence of muscle stretch reflexes, but not with the morphological level of the spinal anomaly. A lower neurosegmental impairment level was associated with a larger CMAP area. These associations were stronger for the gastrocnemius muscle than for the tibialis anterior muscle. No associations were found between CMAP latency and neurological impairment or morphological level of the spinal anomaly. We concluded that the CMAP area provides an estimate of residual LMN function in affected spinal segments and suggested that the residual function represents a cranio-caudal decrease. The assessment of gastrocnemius

CMAPs is recommended as an additional instrument in the assessment of newborn infants with spina bifida. **Chapter 4** describes the results of MEPs obtained in the quadriceps femoris, tibialis anterior, gastrocnemius, and biceps brachii muscles after trancranial and spinal magnetic stimulation in 36 newborn infants with spina bifida. In agreement with the results in Chapter 2, spinal magnetic stimulation resulted in MEPs in most muscles investigated, but transcranial magnetic stimulation hardly resulted in reproducible MEPs. Associations between the spinal MEPs and neurological impairment were also investigated. Similar to the results in Chapter 3, the area under the MEP curve (MEP area) was associated with the level of motor and sensory impairment and with the presence of muscle stretch reflexes, but not with the morphological level of the spinal anomaly. MEP latencies did not relate to the impairment levels. We suggested that the MEP area after lumbosacral magnetic stimulation may provide additional quantitative information about the neurological impairment. The assessment of gastrocnemius and quadriceps femoris MEPs is recommended as an additional tool in the neonatal assessment of spina bifida.

In continuation of Chapters 3 and 4, we investigated the prognostic value of the neonatal MEPs and CMAPs regarding the neurological outcome at two years of age. The results are described in **Chapter 5**. Of the 36 newborn infants initially studied, 29 children were available for the 2-years outcome evaluation that consisted of assessment of muscle function class (MFC) according to McDonald and ambulatory status according to Hoffer. Of the 29 children, 7 were classified as mildly impaired (MFC 1 or 2) and 22 as severely impaired (MFC 3, 4, or 5). Nine children were community ambulators and 20 children were non-community ambulators. The neonatal CMAP and lumbosacral MEP areas were larger in the mildly impaired subgroup compared to the severely impaired group and in community ambulators compared to non-community ambulators. However, the neonatally determined motor and sensory impairment levels showed stronger segregations regarding the 2-years outcome scores than the neonatal CMAP and lumbosacral MEP areas did. We concluded that neonatal CMAPs and lumbosacral MEPs may have some additional prognostic value, which may be helpful in newborn infants with complex spina bifida and in research settings where quantitative information about the neurological impairment might be needed.

In addition to the studies in the neonatal cohort, we performed neurophysiological studies in a cohort of 42 school-age children with spina bifida and a control group of 36 school-age children without spina bifida, aiming to disentangle the proportional contribution of UMN and LMN dysfunction to lower limb motor impairment in children with spina bifida. The results from this study are presented in **Chapter 6**. Motor impairment in the children with spina bifida was graded into known severity scales: muscle strengths in the

quadriceps femoris, tibialis anterior, and gastrocnemius muscles; muscle function classes according to McDonald; and ambulatory status according to Hoffer. In all children, we performed transcranial and spinal magnetic stimulation with MEP recordings from the quadriceps femoris, tibialis anterior, gastrocnemius, and biceps brachii muscles. CMAPs following percutaneous electrical nerve stimulation were recorded from the tibialis anterior and gastrocnemius muscles as well. Regarding LMN function, severely impaired children with spina bifida had smaller CMAP and lumbosacral MEP areas than control children, whereas mildly impaired children only slightly differed from control children. CMAP and lumbosacral MEP latencies did not differ between children with spina bifida and control children. Regarding UMN function, mildly and severely impaired children with spina bifida clearly had smaller transcranial MEP areas and longer central motor conduction times (CMCTs) than control children. The smallest MEP areas and the longest CMCTs were seen in severely impaired children. These findings suggest that UMN dysfunction substantially contributes to motor impairment in spina bifida. As the results were similar for the upper and lower limbs, we concluded that at least part of the UMN dysfunction has its origin at a supraspinal level.

Part two contains the brain MR imaging studies. Brain MR images of 26 children with open spinal dysraphism, 17 children with closed spinal dysraphism, and 36 children without spinal dysraphism or cerebral malformations were blindly and independently reviewed for morphological features and morphometric measures of Chiari II malformation by three observers. In the study described in **Chapter 7**, we investigated the interobserver reliability of all well-known features of Chiari II malformation. Of the 33 features studied, 23 features turned out to be unreliable. The reliable features were predominantly features assessed in the sagittal plane. Herniation of the cerebellum could reliably be assessed, but distinguishing between herniation of the vermis and tonsils appeared to be senseless. We provided a set of essential features of Chiari II malformation that may facilitate plain communication about the MR assessment of Chiari II malformation and provide a solid basis for consensus on the diagnosis in clinical and research settings. In the study described in **Chapter 8**, we investigated interobserver reliability and diagnostic performance of morphometric measures of Chiari II malformation. Of the 21 measures studied, 15 measures turned out to be reliable. The unreliability of measuring the degree of cerebellar herniation was a remarkable result. In the diagnostic performance analyses, the Chiari II malformation was defined by cerebellar herniation and presence of open spinal dysraphism (n = 23). Most measurements differed statistically significantly between children with and without Chiari II malformation. The measures

Mamillopontine distance and *Cerebellar width* showed high sensitivity (0.84 and 0.89, respectively) and specificity (0.97 and 0.92, respectively) regarding the diagnosis of Chiari II malformation. We concluded that morphometric measures reliably quantify the morphological distortions associated with Chiari II malformation and that they have potential to assess the severity of the malformation in clinical and research settings. The measures *Mamillopontine distance* and *Cerebellar width* may be particularly helpful in cases in which the diagnosis Chiari II malformation is ambiguous.

In **Chapter 9**, the general discussion, the main findings are discussed with regard to the research questions. The neurophysiological findings are put into perspective of the multilevel pathology of spina bifida by relating the findings to UMN and LMN dysfunction. We discuss the proportional involvement of UMN and LMN dysfunction in motor impairment with particular contemplation of a disturbed establishment of the synaptic connectivity between the corticospinal and spinal motor neurons during embryonic development. In addition, the diagnostic and prognostic values of the neurophysiological tools used are discussed. Regarding the brain MR imaging studies, the findings are put into perspective of the assessment and diagnosis of Chiari II malformation. Finally, methodological considerations and future perspectives are presented, especially concerning the role of neurophysiological and brain MR imaging studies in the outcome evaluation of prenatal surgery for spina bifida.

Nederlandse samenvatting

Spina bifida, ook wel 'open ruggetje' genoemd, is een van de meest voorkomende aangeboren afwijkingen van het zenuwstelsel, waarbij complexe en heterogene afwijkingen op meerdere niveaus in het zenuwstelsel tot uiting komen. Deze afwijkingen betreffen een embryonaal sluitingsdefect van de rug, afwijkingen in het ruggenmerg boven het niveau van dit sluitingsdefect, de cervicomedullaire overgang met een zogenaamde Chiari II malformatie, hydrocefalus, corpus callosum afwijkingen en corticale malformaties. In dit proefschrift worden deze afwijkingen op meerdere niveaus aangeduid met 'multilevel pathologie' (zie Figuur 1 in hoofdstuk 1).

Spina bifida ontstaat als gevolg van een gestoorde sluiting van de embryonale neurale buis in de 3e en 4e week na conceptie. De oorzaak hiervan is multifactorieel, waarbij zowel genetische als omgevingsfactoren een rol spelen. Globaal kan een onderscheid gemaakt worden tussen open spina bifida en gesloten spina bifida op basis van het al dan niet bedekt zijn van de rugafwijking met normale huid. De toekomstperspectieven en de levensverwachting van kinderen met spina bifida zijn in de afgelopen decennia verbeterd, maar de gevolgen die hun weerslag hebben op het dagelijks functioneren en de deelname aan de maatschappij blijven aanzienlijk. Deze gevolgen zijn neurologische functiestoornissen in de benen en soms ook in de armen, neurologisch gestoorde blaas- en darmfuncties, orthopedische problemen, stoornissen gerelateerd aan de Chiari II malformatie en stoornissen in het cognitief functioneren. Daarnaast wordt de kwaliteit van leven bepaald door de omgeving waarin een kind met spina bifida opgroeit.

In de algemene introductie in **hoofdstuk 1** wordt de achtergrondinformatie over spina bifida beschreven en worden de motivatie en de doelstellingen van het onderzoek gepresenteerd. De motivatie komt voort uit de complexe multilevel pathologie en de heterogeniteit van de afwijkingen in combinatie met een verbeterde toekomstverwachting, de afwezigheid van individuele prognostische indicatoren en actuele discussies over prenatale en postnatale behandeling van spina bifida. Sinds de jaren 70 wordt er nationaal en internationaal een discussie gevoerd over onthouding van actieve behandeling, ook wel selectieve behandeling genoemd, bij pasgeborenen met zeer ernstige vormen van spina bifida. Daar tegenover staat de opkomst van de prenatale chirurgie als behandelmogelijkheid voor ongeboren kinderen met spina bifida. Prenatale chirurgie lijkt een gunstig effect te hebben op de neurologische functiestoornissen in de benen. In het kader van de multilevel pathologie worden deze functiestoornissen bepaald door het disfunctioneren van zowel het centrale motorisch neuron (*upper motor neuron*) als het perifere motorisch neuron (*lower motor neuron*). Dit wordt geïllustreerd in

Figuur 1 in hoofdstuk 1. Weinig is bekend over de verhouding waarin het centrale en het perifere motorisch neuron bijdragen aan de motorische functiestoornissen in de benen. Bovendien is nog onbekend wat de effecten van prenatale chirurgie zijn op het centrale en het perifere motorisch neuron in verhouding tot het positieve effect op de motorische functiestoornissen. Hedendaagse neurofysiologische technieken, waarbij gebruik gemaakt wordt van transcraniële en spinale magneetstimulatie, kunnen meer inzicht geven in deze complexe pathofysiologie.

Prenatale chirurgie lijkt ook een positief effect te hebben op de Chiari II malformatie. De beoordeling van de Chiari II malformatie op MRI afbeeldingen wordt echter gecompliceerd door de morfologische heterogeniteit en een overmaat aan radiologische kenmerken. Die kenmerken zijn voor verschillende interpretaties vatbaar en de betrouwbaarheid ervan ten aanzien van een eenduidige beoordeling door verschillende beoordelaars is nooit onderzocht. Deze problemen kunnen de beoordeling van de Chiari II malformatie op MRI afbeeldingen beperken zowel in de dagelijkse klinische praktijk als in wetenschappelijk onderzoek met betrekking tot de uitkomsten van prenatale chirurgie. De diagnostische waarde van MRI in dergelijke situaties kan verbeterd worden door een kritische beoordeling van de betrouwbaarheid en de diagnostische waarde van anatomische kenmerken en afmetingen van de malformatie op MRI afbeeldingen.

Uit de bovenstaande motivatie volgt de tweevoudige doelstelling van dit proefschrift. De eerste doelstelling was het uiteenrafelen van de proportionele bijdrage van het centrale en het perifere motorisch neuron aan de motorische functiestoornissen in de benen met behulp van conventioneel zenuwgeleidingsonderzoek en innovatief magneetstimulatieonderzoek. Bij zenuwgeleidingsonderzoek worden zenuwen elektrisch gestimuleerd, waarna responsen, zogenaamde *compound muscle action potentials* (CMAPs), afgeleid worden van de spieren en bij magneetstimulatieonderzoek worden de hersenen of zenuwwortels met een uitwendig magnetisch veld gestimuleerd, waarna responsen, zogenaamde *motor evoked potentials* (MEPs), afgeleid worden van de spieren (zie Figuur 2 in hoofdstuk 1). In deze eerste doelstelling werden ook de diagnostische en de prognostische waarde van deze instrumenten meegenomen. De tweede doelstelling was het verbeteren van de diagnostische waarde van conventionele MRI door een analyse van de interbeoordelaarsbetrouwbaarheid en de diagnostische waarde van de anatomische kenmerken en afmetingen van de Chiari II malformatie op MRI afbeeldingen.

De onderzoeken beschreven in dit proefschrift zijn een onderdeel van het Nijmegen Interdisciplinair Spina Bifida Programma. In dit programma participeerden diverse disciplines: kinderneurologie, kinderneuropsychologie, klinische neurofysiologie, neuroradiologie, obstetrie, epidemiologie, gezinspedagogiek en empirische theologie. De hoofddoelstelling van het programma was het in kaart brengen

van de multimodale gevolgen van spina bifida zowel voor het kind met spina bifida als voor zijn omgeving. Deze doelstelling werd belicht vanuit kinderneurologisch, kinderneuropsychologisch, gezinspedagogische en levensbeschouwelijk perspectief in een poging de prognosestelling te verbeteren en een onderbouwing te vinden voor beslissingen over prenatale en postnatale behandeling. In het kader van dit programma zijn reeds twee proefschriften verschenen. In het proefschrift van Ignace Vermaes (*Parents' psychosocial adjustment in families of children with spina* bifida), dat in 2007 verscheen, werd het psychosociaal functioneren van ouders van kinderen met spina bifida beschreven. In 2011 verscheen het proefschrift van Anja Vinck (*Neurocognitive functioning of children with spina bifida*), waarin het cognitief functioneren en de onderliggende cognitieve en motorische processen bij kinderen met spina bifida werden beschreven. Prenatale beeldvorming en neurofysiologische bevindingen in relatie tot de prognose van spina bifida zullen naar verwachting in 2013 beschreven worden in het proefschrift van Inge Cuppen.

Deel één van het proefschrift bevat de resultaten van de neurofysiologische onderzoeken. In **hoofdstuk 2** wordt een pilotstudie beschreven, waarin de mogelijkheden en beperkingen van transcraniële en spinale magneetstimulatie bij pasgeborenen met spina bifida (n = 13) werden onderzocht. Na transcraniële magneetstimulatie konden geen betrouwbare MEPs aan de benen worden afgeleid. Uit de literatuur is bekend dat het lastig is om MEPs op te wekken na transcraniële magneetstimulatie, ook bij gezonde pasgeborenen. Derhalve waren de uitkomsten niet verrassend en bleek deze methode niet geschikt om de functie van het centrale motorisch neuron te onderzoeken bij pasgeborenen met spina bifida. Lumbosacrale magneetstimulatie daarentegen leverde wel betrouwbare MEPs aan de benen op. Opvallend was dat deze MEPs ook opwekbaar waren in volledig paralytische spieren. Lumbosacrale magneetstimulatie bleek hiermee een geschikte methode om het perifere motorisch neuron bij pasgeborenen met spina bifida te onderzoeken. Conventioneel zenuwgeleidingsonderzoek resulteerde in CMAPs in beenspieren die in overeenstemming waren met de gevonden MEPs in dezelfde spieren. De resultaten in deze pilotstudie laten zien dat lumbosacrale magneetstimulatie uitvoerbaar is bij pasgeborenen met spina bifida en dat exciteerbaar neurologische weefsel aanwezig is in of onder de rugafwijking. Dit laatste toont aan dat het perifere motorisch neuron ten minste gedeeltelijk intact is bij pasgeborenen met spina bifida.

In de **hoofdstukken 3 en 4** worden verbanden beschreven tussen neurofysiologische resultaten en uitkomsten van het klinisch neurologisch onderzoek (betreffende het motorische en het sensibele uitvalsniveau en de opwekbaarheid van peesreflexen) bij pasgeborenen met spina bifida. Deze verbanden werden

onderzocht met het oog op een potentiële prognostische waarde van de neurofysiologische instrumenten. In **hoofdstuk 3** worden deze verbanden beschreven voor CMAPs afgeleid aan de spieren tibialis anterior en gastrocnemius bij 31 pasgeborenen met spina bifida. Hierbij bleek dat de oppervlakte onder de CMAP curve (een maat voor de grootte van de CMAP) was geassocieerd met de klinische uitkomsten: een lager uitvalsniveau ging gepaard met een grotere CMAP oppervlakte, waarbij deze associatie sterker bleek voor de gastrocnemius dan voor de tibialis anterior. Er werden geen associaties gevonden tussen de CMAP latentie en de klinische uitkomsten, noch tussen het anatomische niveau van de rugafwijking en de neurofysiologische parameters. Wij concludeerden dat de CMAP oppervlakte kan gelden als een maat voor de restfunctie van het perifere motorisch neuron in aangedane spinale segmenten bij spina bifida, waarbij deze restfunctie een craniocaudale afname lijkt te representeren. Het bepalen van CMAPs in de gastrocnemius kan hiermee van toegevoegde waarde zijn bij pasgeboren met spina bifida. **Hoofdstuk 4** beschrijft MEPs in de spieren quadriceps femoris, tibialis anterior, gastrocnemius en biceps brachii na transcraniële en spinale magneetstimulatie bij 36 pasgeborenen met spina bifida. In overeenstemming met de bevindingen in hoofdstuk 2, resulteerde spinale magneetstimulatie in betrouwbare MEPs in nagenoeg alle onderzochte spieren, terwijl transcraniële magneetstimulatie nauwelijks in meetbare MEPs resulteerde. De onderzochte verbanden tussen MEP parameters en uitkomsten van het klinisch neurologisch onderzoek stemden overeen met de resultaten in hoofdstuk 3. De oppervlakte onder de MEP curve was geassocieerd met het motorische en het sensibele uitvalsniveau en met de opwekbaarheid van peesreflexen, maar niet met het anatomische niveau van de rugafwijking. Ook werd er geen verband gevonden tussen de MEP latentie en de klinische uitkomsten. We opperden dat de oppervlakte onder de MEP na lumbosacrale magneetstimulatie een bijdrage kan leveren aan het kwantificeren van neurologische functiestoornissen in de benen. Het bepalen van MEPs in de quadriceps femoris en gastrocnemius kan hiermee van toegevoegde waarde zijn in de preoperatieve evaluatie van pasgeborenen met spina bifida.

In aansluiting op de hoofdstukken 3 en 4, worden in **hoofdstuk 5** de prognostische waarden van de neonatale CMAPs en MEPs voor neurologische en functionele uitkomsten op de leeftijd van 2 jaar beschreven. Deze prognostische waarden worden hierbij vergeleken met de prognostische waarde van het klinisch neurologisch onderzoek. Van de oorspronkelijke 36 pasgeborenen waren er 29 beschikbaar voor evaluatie op de leeftijd van 2 jaar. Hierbij werden de *Muscle Function Class* (MFC), een classificatie met een schaal van 1 (mild) tot 5 (ernstig) voor motorische functiestoornissen in de benen volgens McDonald, en de loopfunctie (*community ambulant* versus *non-community ambulant*) volgens Hoffer

bepaald. Van de 29 kinderen waren er zeven mild aangedaan (MFC 1 of 2) en 22 ernstig aangedaan (MFC 3, 4 of 5). Negen kinderen waren *community ambulant* en 20 niet. De oppervlakten onder de neonatale CMAPs en lumbosacrale MEPs bleken groter in de mild aangedane kinderen dan in de ernstig aangedane kinderen. De neonatale motorische en sensibele uitvalsniveaus bleken echter ook duidelijk lager te liggen in de mild aangedane kinderen dan in de ernstig aangedane kinderen, waarbij deze verschillen evidenter leken dan de verschillen voor de neurofysiologische parameters. Op basis hiervan werd geconcludeerd dat neonatale CMAPs en MEPs een beperkte toegevoegd prognostische waarde hebben ten opzichte van het klinische neurologisch onderzoek, welke echter van belang kan zijn bij kinderen met complexe vormen van spina bifida. Daarnaast kunnen CMAPs en MEPs van toegevoegde waarde zijn in wetenschappelijk onderzoek, waarbij kwantitatieve informatie over motorische functies gewenst is.

Naast pasgeborenen met spina bifida werden ook kinderen in de leeftijd van 6-14 jaar in het onderzoek betrokken. Zenuwgeleidingsonderzoek en magneetstimulatieonderzoek werden verricht in een groep van 42 kinderen met spina bifida en in een groep van 36 gezonde controle kinderen. Het doel van deze onderzoeken was het uiteenrafelen van de proportionele bijdrage van het centrale en het perifere motorisch neuron aan de motorische functiestoornissen in de benen bij spina bifida. De resultaten hiervan staan beschreven in **hoofdstuk 6**. De motorische functiestoornis werd beoordeeld op drie manieren: spierkracht in de spieren quadriceps femoris, tibialis anterior en gastrocnemius, *Muscle Function Class* volgens McDonald en loopfunctie volgens Hoffer. Op basis van deze evaluatie werden de kinderen met spina bifida geclassificeerd als mild of ernstig aangedaan. Transcraniële en spinale magneetstimulatie werden verricht bij alle kinderen, waarbij MEPs werden afgeleid aan de quadriceps femoris, tibialis anterior en gastrocnemius en ook aan de biceps brachii. Bovendien werd elektrische zenuwstimulatie verricht in de knieholte, waarna CMAPs werden afgeleid aan de tibialis anterior en gastrocnemius. Met betrekking tot de functie van het perifere motorisch neuron zagen we dat ernstig aangedane kinderen met spina bifida duidelijk kleinere CMAP en MEP oppervlakten hadden dan controle kinderen, terwijl dit verschil voor de mild aangedane kinderen gering was. CMAP en lumbosacrale MEP latenties verschilden niet tussen kinderen met spina bifida en controle kinderen. Met betrekking tot de functie van het centrale motorisch neuron zagen we dat zowel de mild als de ernstig aangedane kinderen duidelijk kleinere transcraniële MEPs en langere centrale motorische conductie tijden (CMCT) hadden dan de controle kinderen. Binnen de groep kinderen met spina bifida hadden de ernstig aangedane kinderen kleinere transcraniële MEPs en langere CMCTs dan de mild aangedane kinderen. Deze bevindingen suggereren dat het centrale motorisch neuron een belangrijke rol speelt in de motorische

functiestoornissen van de benen bij kinderen met spina bifida. Aangezien deze resultaten golden voor zowel de been- als de armspieren, werd aangenomen dat een belangrijk deel van de disfunctie van het centrale motorisch neuron gelegen is boven het niveau van het ruggenmerg. Dit kan geassocieerd zijn met de Chiari II malformatie of met supratentoriële grijze en witte stof afwijkingen.

In deel twee van dit proefschrift worden de onderzoeken naar de interbeoordelaarsbetrouwbaarheid en de diagnostische waarde van de anatomische kenmerken en afmetingen van de Chiari II malformatie op MRI afbeeldingen beschreven. Cerebrale MRI scans van 26 kinderen met open spina bifida, 17 kinderen met gesloten spina bifida en 26 kinderen zonder spina bifida of cerebrale afwijkingen werden geblindeerd en onafhankelijk beoordeeld door drie beoordelaars. Hierbij werden anatomische kenmerken gescoord en anatomische afmetingen bepaald aangaande de Chiari II malformatie. De resultaten van het onderzoek naar de interbeoordelaarsbetrouwbaarheid van de anatomische kenmerken worden beschreven in **hoofdstuk 7**. Alle in de literatuur bekende anatomische kenmerken, 33 in het totaal, werden onderzocht. Hierbij bleek dat slechts 10 kenmerken betrouwbaar gescoord konden worden. Dit waren vooral kenmerken op saggitale MRI scans. Het beoordelen of er sprake is van herniatie van het cerebellum bleek betrouwbaar, maar het bleek niet mogelijk om een betrouwbaar onderscheid te maken tussen herniatie van de vermis en herniatie van de tonsillen. Op basis van dit onderzoek werd een set van betrouwbare Chiari II malformatie kenmerken vastgesteld, die de basis kan vormen voor consensus over de radiologische diagnose Chiari II malformatie. Bovendien leidt het gebruik van deze betrouwbare kenmerken tot heldere communicatie over de Chiari II malformatie zowel in de klinische praktijk als in wetenschappelijk onderzoek. In **hoofdstuk 8** staan de resultaten aangaande de anatomische afmetingen bij Chiari II malformatie beschreven. Ten eerste werd de interbeoordelaarsbetrouwbaarheid van metingen aan de hersenstam, het cerebellum en de achterste schedelgroeve onderzocht. Van de 21 onderzochte maten bleken 15 maten betrouwbaar. Hierbij was opvallend dat het meten van het niveau van herniatie van het cerebellum niet betrouwbaar was. Vervolgens werd de diagnostische waarde van de betrouwbare maten bepaald, waarbij de diagnose Chiari II malformatie gedefinieerd werd als herniatie van het cerebellum door het foramen magnum in combinatie met de aanwezigheid van open spina bifida. Dit gold voor 23 kinderen. De meeste metingen bleken statistisch significant te verschillen tussen de kinderen met en de kinderen zonder Chiari II malformatie. De mamillopontiene afstand en de breedte van het cerebellum hadden een hoge sensitiviteit (0.84 en 0.89) en specificiteit (0.97 en 0.92) voor de diagnose Chiari II malformatie. We concludeerden dat diverse anatomische afmetingen betrouwbaar gebruikt kunnen worden om

de complexe kenmerken van de Chiari II malformatie te kwantificeren. Deze maten hebben potentie om de ernst van de malformatie te kwantificeren in de klinische praktijk en in wetenschappelijk onderzoek. De mamillopontiene afstand en de breedte van het cerebellum kunnen behulpzaam zijn in gevallen waarbij de diagnose Chiari II malformatie twijfelachtig is.

In de algemene discussie beschreven in **hoofdstuk 9** worden de bevindingen in dit proefschrift bediscussieerd in relatie tot de vraagstellingen van het onderzoek. De neurofysiologische resultaten worden hierbij geplaatst in het perspectief van de afwijkingen op meerdere niveaus in het zenuwstelsel (multilevel pathologie) bij kinderen met spina bifida, waarbij de resultaten worden vertaald naar disfunctioneren van het centrale en het perifere motorisch neuron. De proportionele betrokkenheid van het centrale en het perifere motorisch neuron bij de motorische functiestoornissen in de benen wordt verder uitgediept, waarbij gespeculeerd wordt over een gestoorde totstandkoming van synaptische verbindingen tussen het centrale en het perifere motorisch neuron. Bovendien worden de diagnostische en de prognostische waarden van de neurofysiologische instrumenten bediscussieerd. Met betrekking tot de radiologische onderzoeken worden de resultaten geplaatst in het perspectief van de beoordeling en de diagnose van Chiari II malformatie. Methodologische overwegingen worden eveneens belicht. De algemene discussie wordt afgesloten met implicaties voor prenatale chirurgie bij spina bifida en suggesties voor verder onderzoek.

Dankwoord

Bijna 11 jaar geleden begon ik aan mijn promotieonderzoek bij het onderzoeksprogramma dat later de naam Nijmegen Interdisciplinair Spina Bifida Programma kreeg. Met het bijbehorende 'boekje' in handen, sluit ik nu een belangrijke periode in mijn leven af. Het was een vormende periode, waarin promoveren veel meer was dan het schrijven van een proefschrift. Het heeft me veel geleerd over mijzelf en over mijn omgeving. Ik heb onder andere geleerd op mezelf te vertrouwen en mijn eigen pad te kiezen en te volgen. Tevreden en met genoegen kijk ik nu terug op deze enerverende periode, waarin veel mensen een belangrijke bijdrage hebben geleverd aan de goede afloop van het project. Dankbaar ben ik deze mensen voor hun enthousiasme, de praktische hulp, de wijze raad, de kritische commentaren en hun support in welke vorm dan ook. In het zonovergoten Andalusië, mijn hoofd zo goed als leeg, vertrouw ik nu mijn persoonlijke woorden van dank toe aan het geduldige papier, waarbij ik zal proberen niemand te vergeten.

Allereerst gaat mijn dank uit naar alle kinderen, jong en oud, en hun ouders voor hun geduld en hun bereidheid om deel te nemen aan het Nijmegen Interdisciplinair Spina Bifida Programma. Met genoegen denk ik nog wel eens terug aan de dagprogramma's die de kinderen doorliepen op de afdeling BOB. Zonder hun inzet was dit proefschrift niet tot stand gekomen.

In het bijzonder gaan mijn dank en waardering uit naar mijn promotor en copromotoren. Hartelijk dank voor jullie betrokkenheid, het vertrouwen en de geboden mogelijkheden. De weg was lang en in het begin zeer breed, er waren hobbels en obstakels, maar gaande weg versmalde en versnelde het pad, dat leidde naar dit proefschrift.
Beste prof. dr. Rotteveel, beste Jan. Onze eerste ontmoeting in de barakken van het B-gebouw staat me nog helder voor de geest. Tijdens een eerste gesprek over een wetenschappelijke stage bij de afdeling kinderneurologie kwam jij met een dik dossier tevoorschijn met het voorstel een *case report* te schrijven. Hiermee heb je mijn interesse voor zowel de wetenschap als de kinderneurologie verder weten aan te wakkeren en werd er de basis gelegd voor een vervolgsamenwerking in het spina bifida project. Jouw enthousiasme voor de neurofysiologie werkte zo aanstekelijk, dat het MEP-project een wezenlijk onderdeel is geworden van mijn proefschrift. Ondanks de vertragingen, bleef je enthousiast over mijn bevindingen en wist je mij telkens weer op Rotteveliaanse wijze te stimuleren.
Beste dr. Mullaart, beste Reinier, dank voor je intensieve, maar ook eigenzinnige begeleiding in de afgelopen jaren. Samen met Jan was je een belangrijke initiator van het spina bifida project, waarbij je veel voorwerk hebt verricht onder andere

door het aanleggen van een indrukwekkende database voor de retrospectieve studie. Jouw kritische houding vormde de basis voor mijn eigen kritisch-wetenschappelijke instelling. Hoewel jouw commentaren scherp en overvloedig waren, stimuleerde je mij om mijn eigen mening te vormen en mijn eigen weg te kiezen. Veel discussies hebben we gevoerd over de inhoud, maar ook over de taal van de publicaties, waarbij het wetenschappelijk schrijven soms bijna tot kunst werd verheven. “Papier is geduldig” was hierbij een belangrijk uitgangspunt. Onze discussies over de goud(en) standaard en de parallel met oud ijzer heeft zelfs tot een stelling bij dit proefschrift geleid. De laatste jaren was je meer op de achtergrond aanwezig, maar dat maakte jouw mening niet minder belangrijk. Ik heb veel waardering voor het belang dat je toonde in de afronding van mijn promotie. Ook ben ik jou en Silvia dankbaar voor jullie gastvrijheid. Graag kom ik de toekomst nog eens aanwaaien bij jullie in Amsterdam. Ik wens jullie veel geluk en vreugde in het leven.
Beste dr. Pasman, beste Jaco, het ‘MEP-project’ vormt een belangrijke rode draad in mijn promotieonderzoek. Zonder het ‘MEP-project’ en jouw rol daarbij was dit proefschrift er niet gekomen. Je hebt mij wegwijs en enthousiast gemaakt in de wereld van de klinische neurofysiologie en het was een voorrecht om samen met jou alle neurofysiologische metingen te doen. Dank voor de tijd die we samen gestoken hebben in het verkrijgen van de data en het schrijven van de publicaties. Je bent een stabiele steun en toeverlaat. Er zijn maar weinig momenten, dat het niet uitkwam als ik op de stoep stond. Dank voor je relativerend vermogen en je rust, waardoor ik altijd het gevoel had dat het wel goed zou komen.
Beste dr. ir. Roeleveld, beste Nel, ook jouw deur staat altijd open, niet alleen voor inhoudelijk overleg, maar ook voor een goed gesprek. Je maakte mij wegwijs in de wereld van de statistiek, SPSS en SAS. Ik bewonder je passie en ambitie voor de wetenschap. Je bewaakte de voortgang van het spina bifida project met oog voor persoonlijk welbevinden van de promovendi. Dank voor je verfrissende commentaren in de discussies, waarbij jouw kritische feedback, je kennis van methodologie en statistiek en ook je algemeen medische kennis waardevolle aanvullingen waren. Jouw *final* correcties brachten de papers telkens weer naar een hoger niveau. Jaco en Nel, dank voor de continuïteit die jullie gaven aan het project.
Tot slot, promotor en copromotoren, dank voor alle avondbijeenkomsten door de jaren heen. Deze avonden vormden een belangrijke inhoudelijke en informele continuïteit, al dan niet met een goed glas wijn. Ik zal deze avonden missen, maar een (afsluitende) bijeenkomst op de boot staat volgens mij nog steeds in de planning.....

Beste drs. van der Vliet, beste Ton, de twee hoofdstukken over de Chiari II malformatie vormen een belangrijk onderdeel van mijn proefschrift. Dank voor het vertrouwen dat je had in de ideeën van Reinier en mij en voor de tijd die je gestoken hebt in het beoordelen van de MRIs. Ook vanuit het hoge noorden bleef je betrokken bij het Nijmeegse spina bifida project. Hartelijk dank voor je bijdrage aan deze klus en voor de prettige samenwerking. Beste drs. Ton Feuth, beste prof. dr. George Borm, toen op een gegeven moment de statistiek te ingewikkeld werd, hebben Nel en ik jullie hulp ingeroepen. Dank voor jullie bijdrage en de uitleg aangaande kappa analyses en ingewikkelde mixed model analyses. Prof. dr. Maassen, beste Ben, het neuropsychologische deelproject was sterk verweven met het kinderneurologische deelproject van het spina bifida programma. Dank voor je kritische input tijdens de overlegmomenten en de plezierige samenwerking.

Ook gaat mijn dank uit naar de leden van de manuscriptcommissie, prof. dr. Sander Geurts, prof. dr. Dick Stegeman, en prof. dr. Oebo Brouwer, voor de kritische beoordeling van mijn manuscript. Dank voor jullie tijd en bereidheid.

In de kinderkliniek van het UMC St Radboud hebben diverse mensen in meer of mindere mate een bijdrage geleverd aan het onderzoek. De verpleegkundigen van afdeling B31 en BOB en later Q2S en Q2Z, dank voor jullie hulp en flexibiliteit bij de onderzoeken van de pasgeborenen met spina bifida. Gerard Jorna, dank voor je coördinerende ondersteuning bij de complexe dagprogramma’s die de kinderen op BOB doorliepen. Jos Draaisma, René Severijnen en Jean Gardeniers, dank voor jullie bijdrage aan de inclusie van controle kinderen. Mirjam, José en alle andere KNF-laboranten die een bijdrage hebben geleverd aan het verkrijgen van de neurfysiologische metingen, ik ben jullie dankbaar voor jullie inzet en flexibiliteit. Yvonne, telkens als ik weer op onmogelijke tijdstippen kwam met een pasgeborene met spina bifida of er geschoven moest worden met de MEP-tijden, wist jij nog een gaatje te vinden in de diverse agenda’s om een “weinig populaire MEP” te plannen. Dank voor je inspanningen en de logistieke ondersteuning. Gera, Ineke, Marlou en Ria, dank voor de kinderfysiotherapeutische inbreng in het spina bifida project.

Prof. dr. Willemsen, beste Michèl, dank voor je stimulerende en motiverende inbreng en de praktische bijstand in de laatste fase van mijn promotietraject. Mede doordat we nog wat tijd vrij konden maken, kwam het onderzoek in een stroomversnelling. Corrie Erasmus, Charlotte Haaxma, Miel Linders, Jolanda Schieving en Lilian Sie, dank voor jullie support, interesse en prettige samenwerking op de afdeling kinderneurologie. Hanneke en Jeanne, dank voor jullie persoonlijke ondersteuning.

Mijn onderzoek liep door tijdens mijn stage in het Rijnstate ziekenhuis. Anneke Landstra, Petra van Setten en de vakgroep kindergeneeskunde, dank voor de flexibiliteit en het constructieve meedenken in deze periode. Hierdoor kwam de voortgang van het onderzoek niet in gevaar. Ik kijk uit naar onze hernieuwde samenwerking. Kinderartsen en arts-assistenten Kindergeneeskunde uit het Radboud, dank voor een fijne opleidingstijd en de prettige samenwerking. Jos Draaisma, dank voor je interesse en enthousiasme voor mijn promotieonderzoek.

Beste Ignace en Marizjenne, medeonderzoekers in het Nijmegen Interdisciplinair Spina bifida Programma van de overkant van de Erasmuslaan, dank voor jullie inbreng, plezierige samenwerking en gezelligheid. De congrestripjes naar Barcelona en Dublin zijn onvergetelijk. Beste Inge, onze parallelle trajecten leverden een intensieve samenwerking op. Erg blij was ik, toen je in 2006 aansloot bij het project en ik een maatje kreeg om het spina bifida project op de kaart te houden. We vormden een goed klankbord voor elkaar en ik ben trots op onze gezamenlijke publicaties. Dank voor je humor, je plezierige samenwerking en je persoonlijke inbreng. Hoewel onze wegen nu minder parallel lopen (scheiden is een te groot woord), hoop ik dat we in de toekomst kunnen blijven samenwerken. In ieder geval lever ik nog graag een bijdrage aan de afronding van jouw boekwerk. Hiermee en met al het andere dat op je pad komt, wens ik je veel succes en geluk.

Beste vrienden, gelukkig is er ook een leven naast wetenschap en ziekenhuis. Ik ben blij met alle lieve en leuke mensen om mij heen, al heb ik jullie de laatste jaren misschien te kort gedaan. Ik waardeer jullie steun en interesse in iets dat misschien niet altijd goed te begrijpen was. Echt rustig zal het wel nooit worden, maar met het voltooien van dit boekje is er weer meer tijd voor afleiding. De ontspanning, het sporten, het plezier (soms tot in de vroege uurtjes), de weekendjes weg in diverse samenstellingen en, niet te vergeten, de *spaß und gemütlichkeit* tijdens de wintersportvakanties zorgden voor de oh zo belangrijke balans werk-privé. Op naar veel meer bijzondere en mooie momenten in de toekomst. Dank voor de kleur die jullie vriendschap geeft! Echte vriendschap kost geen moeite!

Beste Anja, medeonderzoekster van het eerste uur. Samen zijn we, wellicht een tikkeltje naïef, aan het spina bifida project begonnen en met alle ups en downs hebben we het volbracht. Ik ben blij dat je op deze bijzondere dag naast me staat. Ik bewonder je multi-talent en je vermogen veel ballen tegelijk in de lucht te houden. De rollercoaster, waarin jij je promotie hebt afgerond is ongekend. Ik vind het mooi jou nu te zien genieten van de tijd met je gezin. Dank voor een zeer fijne samenwerking, de momenten van ontspanning en je morele ondersteuning. Veel geluk voor de toekomst samen met Robin, Rosa en Lotte.

Beste Brian, vriend, huisgenoot, ploeggenoot en ook medeonderzoeker in het brede spectrum dat wetenschap heet, wat ben je eigenlijk niet? Ik ben blij dat jij op deze bijzondere dag aan mijn andere zijde staat. Jouw gedrevenheid en energie zijn bewonderenswaardig. Ook je relativerende opmerkingen waren soms net dat duwtje in de rug. We zien elkaar eigenlijk te weinig, dat weten we, maar als ik nu zeg dat dit anders wordt, weten we ook allebei dat dit in onze drukke levens niet direct zal lukken. Laten we het nemen zoals het komt of om met je eigen woorden te spreken: “Vriendschap gaat om kwaliteit en niet om kwantiteit”.

Beste Familie,
Leny en Albert, dank voor jullie interesse in mijn onderzoeksactiveiten en voor de warme gezelligheid die jullie bieden. Het mooie Milsbeek aan de Maas voelt voor mij als een tweede ouderlijk huis. Dat we nog maar vaak mogen proosten op de bijzondere momenten van het leven. Albert, je hebt een wezenlijke bijdrage geleverd aan de totstandkoming van dit boekje en me veel werk uit handen genomen door de eindeloze MEP en MRI data nauwgezet in te voeren. Heel veel dank hiervoor!
Paul, Noor en de kleine Mees, het is bijzonder dat jullie familie én vrienden zijn. Fijn dat jullie altijd in de buurt zijn. De onverwachte momenten van gezelligheid met een kopje koffie of een borreltje zijn voor mij een zeer waardevolle afleiding.
Simone en Jeroen, ik bewonder jullie gedrevenheid en wijze waarop jullie je leven inrichten. Al zien we elkaar niet zo vaak, jullie steun en aanwezigheid is onvoorwaardelijk. De geboorten van Thijs en de kleine Bibi maken dat al het andere relatief is. Het geluk van deze twee kleintjes is van onschatbare waarde. Prachtig is de bijdrage van Bibi: pas vier dagen oud schittert ze op de cover van dit proefschrift.
Lieve pap en mam, jullie hebben mij de mogelijkheden geboden om te worden wie ik nu ben en om dit alles te bereiken. Ik kon altijd op jullie steun rekenen bij de keuzes die ik maakte. Als 18-jarige hebben jullie mij op de trein gezet naar Nijmegen; geen van allen hadden we er toen weet van dat dit uiteindelijk naar deze dag zou leiden. Inmiddels weer 18 jaar later sta ik hier opnieuw op een belangrijk mijlpaal in mijn leven en ik ben erg blij dat jullie daar bij zijn. Ik wil jullie bedanken voor jullie warmte, steun en liefde, waar ik altijd van op aan kan. Ik ben er trots op dat jullie mijn ouders zijn.
Lieve Niek, jij bent mijn stabiele thuissituatie, niets is belangrijker! Je geeft me de liefde en de ruimte die ik nodig heb. Dank voor je geduld, het uithanden nemen en je steun. Samen zijn we goed in het nuttige met het aangename combineren. Eindelijk kunnen nu alle stapels papier in ons huis opgeruimd worden, om ruimte te maken voor andere belangrijke dingen in het leven. Ik kijk uit naar wat de toekomst ons samen zal brengen.

Niels

Curriculum Vitae

Niels Geerdink was born on April 6th, 1976 and was raised together with his younger sister in Eibergen, a village in the Achterhoek in the Netherlands. He attended secondary school at the RKSG Marianum in Groenlo from 1988 to 1994, after which he started Medical School at the Radboud University Nijmegen. During his medical internships, he became interested in pediatrics and pediatric neurology. In light of these interests, he studied MECP2 mutations in children with mental retardation of unknown origin under supervision of prof. dr. Ben Hamel (Department of Human Genetics, Radboud University Medical Centre Nijmegen) and prof. dr. Jan Rotteveel (Department of Pediatric Neurology). In December 2001, he obtained his Medical Degree and soon thereafter he started with his PhD research project in the Nijmegen Interdisciplinary Spina Bifida Program at the Department of Pediatric Neurology of the Radboud University Nijmegen Medical Centre under supervision of prof. dr. Jan Rotteveel, dr. Reinier Mullaart, dr. Jaco Pasman, and dr. ir. Nel Roeleveld. In 2002 and 2003, he worked as a resident in Pediatrics at the Radboud University Nijmegen Medical Centre, where he also started his training in Pediatrics (successive supervisors the late prof. dr. Rob Sengers, prof. dr. Louis Kollée, and dr. Jos Draaisma) in rotation with the Rijnstate Hospital in Arnhem (supervisors dr. Anneke Landstra and dr. Petra van Setten). He combined his clinical training with his PhD project in a so-called AGIKO-program. In 2011, he finished his training in Pediatrics and started a fellowship in Pediatric Neurology at the Department of Pediatric Neurology (Radboud University Nijmegen Medical Centre; supervisor prof. dr. Michèl Willemsen) and the Department of Neurology (Rijnstate Hospital Arnhem; supervisor dr. Quinten Leyten). After completing this fellowship at the end of 2012, he will start working as a pediatrician/pediatric neurologist at the Department of Pediatrics of the Rijnstate Hospital in Arnhem in January 2013. Since 2004, Niels has shared his life with Niek Reintjes. They live together in Nijmegen-Oost.

List of publications

Cuppen I, **Geerdink N**, Rotteveel J, Mullaart R, Roeleveld N, Pasman J. Motor evoked potentials and compound muscle action potentials as prognostic tools for neonates with spina bifida. *Eur J Paediatr Neurol* 2012 (http://dx.doi.org/10.1016/j.ejpn.2012.06.003).

Geerdink N, Cuppen I, Rotteveel J, Mullaart R, Roeleveld N, Pasman J. Contribution of the corticospinal tract to motor impairment in spina bifida. *Pediatr Neurol* 2012; 47:270-278.

Geerdink N, van der Vliet A, Rotteveel J, Feuth T, Roeleveld N, Mullaart R. Essential features of Chiari II malformation in MR imaging: An interobserver reliability study - part 1. *Childs Nerv Syst* 2012; 28:977-985.

Geerdink N, van der Vliet A, Rotteveel J, Feuth T, Roeleveld N, Mullaart R. Interobserver reliability and diagnostic performance of Chiari II malformation measures in MR imaging - part 2. *Childs Nerv Syst* 2012; 28:987-995.

Cuppen I, Vinck A, **Geerdink N**, Rotteveel J, Roeleveld N, Pasman J. Early infantile electroencephalography in patients with spina bifida. *Neuropediatrics* 2011; 42:152-155.

Geerdink N, Pasman J, Rotteveel J, Roeleveld N, Mullaart R. Compound muscle action potentials in newborn infants with spina bifida. *Dev Med Child Neur* 2008; 50:706-711.

Vermaes I, Gerris J, Mullaart R, **Geerdink N**, Janssens J. PMTS and stress response sequences in parents of children with spina bifida. *Eur J Paediatr Neurol* 2008; 12:446-454.

Geerdink N, Pasman J, Roeleveld N, Rotteveel J, Mullaart R. Responses to lumbar magnetic stimulation in newborns with spina bifida. *Pediatr Neurol* 2006; 34:101-105.

Kleeftstra T, Yntema H, Nillesen W, Oudakker A, Mullaart R, **Geerdink N**, van Bokhoven H, de Vries B, Sistermans E, Hamel B. MECP2 analysis in mentally retarded patients: implications for routine DNA diagnostics. *Eur J Hum Genet* 2004; 12:24-28.

Geerdink N, Rotteveel J, Lammens M, Sistermans E, Heikens G, Gabreëls F, Mullaart R, Hamel B. MECP2 mutation in a boy with severe neonatal encephalopathy. Clinical, neuropathological and molecular findings. *Neuropediatrics* 2002; 33:33-36.